



A Review On Lumbar Spine Disease

Assist.Prof. Mrs.J M. Waykule
Electronics Engg.,
Sanjay Ghodawat University, Kolhapur

Dr.V.R.Udupi,
Electronics Engg.,
Gogte Institute of Technology,Belgavi.

Abstract— This survey paper examines spine disease and its symptoms and cause. The lumbar vertebrae are the biggest and support the most weight in the body. The range of motion in this region is greater than that of the thoracic spine, but less than that of the cervical spine. The lumbar facet joints allow for great flexion and extension but not rotation. Cause of lumbar spondylosis in early age due to lose moisture in spinal discs and shrink as human age, bone spurs form, and bones become weaker and this normal wear and tear of the lumbar (lower back) spinal discs is referred to as lumbar spondylosis. While many persons over the age of 50 have minor lumbar spondylosis, the majority of them have no symptoms. This research will aid in the identification of spine structure and function, lumbar disease with its various types with a particular emphasis on lumbar diseases such as DDD (Degenerative disc disease) and DD (Disc Desiccation), DDD causes, and risk factors, as well as the diagnostic tools

Keywords— Spine anatomy, spine vertebral spine intervertebral, spine disease, lumbar spondylosis ,cervical spine. MRI, DDD (Degenerative disc disease), DD(Disc Desiccation)

I. INTRODUCTION

The spinal cord forms a vital link between the brain and the rest of the body and is part of the central nervous system. It regulates body activities, such as movement and behavior, in collaboration with the brain. The spinal cord is protected by the bones of the spine. The spinal cord's major functions include: Electrochemical communication. Electrical currents run up and down the spinal cord and across nerves, sending messages that allow various body parts to connect with the brain. i) Motor Functions - directs your body's voluntary muscle movements. ii) Sensory Functions – monitors sensation of touch, pressure, temperature and pain. iii) Autonomic Functions – regulates digestion, urination, body temperature, heart rate, and dilation/contraction of blood vessels (blood pressure). The cervical spine, thoracic spine, and lumbar spine are the three main segments of the spine. The cervical spine is made up of seven vertebrae and is located at the top of the spine (bones)[2]. The thoracic spine is made up of 12 vertebrae and is located in the middle of the spine. The lumbar spine refers to the bottom part of the spine [1]. While the discs in the lower (lumbar) region of the spine are most often affected in intervertebral disc disease, any part of the spine can have disc degeneration. Depending on the location of the affected disc or discs, intervertebral disc disease can cause periodic or chronic pain in the back or neck. Pain is often worse when sitting, bending, twisting, or lifting objects [3]. In this paper we will focus on structure of spine, different types of diseases in lumbar and

cervical disease, cause and risk factor of degenerative disc disease with its systems and how to diagnose this degenerative disc disease.

II. LITURARY SURVEY

A. Structure of Spinal cord

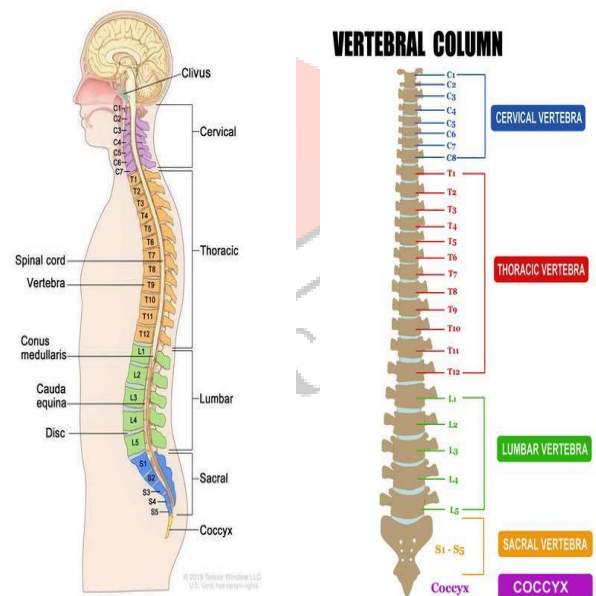


Fig.1: Structure of spinal cord

There are 23 discs in the human spine: 6 in the cervical region (neck), 12 in the thoracic region (middle back), 5 in the lumbar region (lower back). IVDs allow the spine to be flexible without sacrificing a great deal of strength. In humans, the vertebral column usually consists of 33 vertebrae, placed in series and connected by ligaments and intervertebral discs. However, the number of vertebrae can vary between 32 and 35. Usually there are 7 cervical, 12 thoracic, 5 lumbar, 5 sacral and 4 caudal (coccygeal) vertebrae. Intervertebral disc disease is a common condition characterized by the breakdown (degeneration) of one or more of the discs that separate the bones of the spine (vertebrae), causing pain in the back or neck and frequently in the legs and arms. The intervertebral discs provide cushioning between vertebrae and absorb pressure put on the spine. [3]. Low back pain is a spinal problem that is primarily caused by degenerative disc disease. The lumbar region of the spine is the most vulnerable to the disease because it supports the lower back by transmitting compressive and shearing forces to the upper chest During daily activities, The research focuses on

modelling a healthy L5-S1 lumbar segment using image processing and computer-aided engineering to convert a CT scan image into a meshed finite element model. An in-vivo method was also used to measure the range of motion of the lumbar region in this study. Intervertebral discs connect the thirty-three vertebrae. This size of IVD is difference in different location of spine due to the lumbar spine's function, which is to provide support for the body.[8]

Anatomy of discs: A column of bones called vertebrae makes up your spine. A shock-absorbing disc sits between each vertebra, preventing the bones from grinding together. Discs are similar to radial vehicle tyres in design. Like a tyre tread, the robust outer wall, called the annulus, has crisscrossing fibrous bands. Each vertebra bone has a band that attaches to it. The nucleus, similar to a tyre tube, is a gel-filled center inside the disc (Fig. 2). [6]

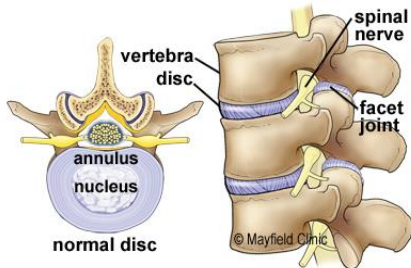


Fig.2: Drawing of a normal disc showing the gel-filled nucleus surrounded by annulus rings of cartilage fibers.

The lumbar spine is made up of vertebral bones, intervertebral discs, nerves, muscles, ligaments, and blood vessels, and it is located in the lower back. The spinal cord terminates at the top of the lumbar spine and the remaining nerve roots, known as the cauda equina, descend the rest of the spinal canal.

The lower back performs the following important functions:

Support and stabilize the upper body. In comparison to other spinal regions, the lumbar vertebrae are the largest. 1,2 These vertebrae sustain the weight of the upper body, including the head and neck, in cooperation with muscles and ligaments. The lumbar spine is also responsible for transferring weight from the upper body to the legs.

Allow truncal movements. The lower back is the key facilitator for trunk motions in all directions, including front-to-back, side-to-side, and twisting. The last two vertebral levels are where most movement occurs.

Protect the spinal cord and cauda equina. In their vertebral arches, the upper lumbar vertebrae protect the spinal cord. The lower vertebrae create a bone cage for the spinal cords cauda equina nerves.

Control leg movements. The lumbar spinal nerves control movement and sensation in the legs.[5]

B. Types of spine Disorders

Numerous conditions can affect the spine anywhere from the neck to the lower back. Some of the many spine disorders we treat are:

Degenerative spine and disc conditions:

- Arthritis,
- Degenerative disc disease ,
- Herniated disc,
- Spinal stenosis
- Spondylosis

There are other different spine conditions and disorders like Back pain, Osteoporosis and Scoliosis etc. [4] While the discs in the lower (lumbar Fig-1) region of the spine are most often affected in intervertebral disc disease, any part of the spine can have disc degeneration. Depending on the location of the affected disc or discs, intervertebral disc disease can cause periodic or chronic pain in the back or neck. Pain is often worse when sitting, bending, twisting, or lifting objects.[3]

1. **Degenerated discs** are prone to out-pouching (herniation); the protruding disc can press against one of the spinal nerves that run from the spinal cord to the rest of the body. This pressure causes pain, weakness, and numbness in the back and legs. (As a disc degenerate, small bony outgrowths (bone spurs) may form at the edges of the affected vertebrae. These bone spurs may pinch (compress) the spinal nerves, leading to weakness or numbness in the arms or legs. Over time, a degenerating disc may break down completely and leave no space between vertebrae, which can result in impaired movement, pain, and nerve damage.)
2. **Bulging** disks occur when the spongy disks between the vertebrae become compressed and bulge out. A common cause of bulging disks is aging. If this degradation continues, it can lead to a herniated disk. Herniated disks can cause pain, numbness, and mobility issues.
3. **Herniated discs** often cause nerve pain called sciatica that travels along the sciatic nerve, which runs from the lower back down the length of each leg.
4. **Thinning Disc:** Disc gets thinner - due to the loss of water, the discs get thin and the distance between vertebrae begin to collapse. Which is why we get shorter as we age. Bone spurs grow – without the discs holding apart the vertebrae, they can rub on each other causing abnormal bone growths [3]. Frequency to affect Intervertebral disc disease is estimated about 5 percent of the population in developed countries each year. Most individuals experience disc degeneration as they age; however, the severity of the degeneration and the pain associated with it varies.[3]

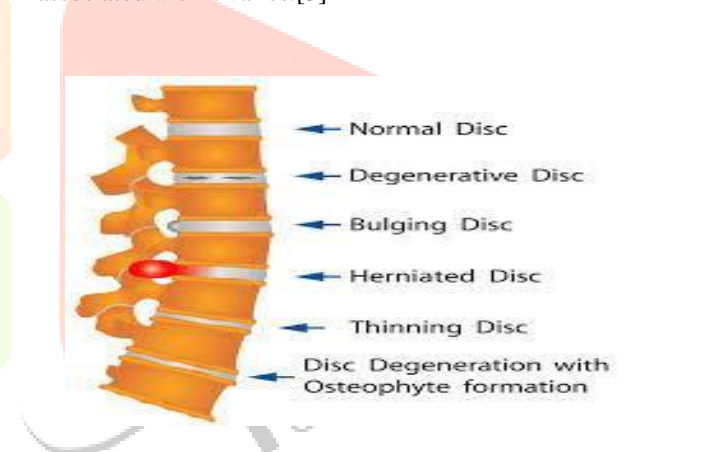

Fig.3: Disc disease

DDD: Degenerative disc disease (spondylosis) can affect any part of the spine (cervical, thoracic, and lumbar), but it is most frequent in the lower back. It's not an illness, but rather a condition in which your discs "degenerate" and lose their ability to cushion the spine by losing their flexibility and height. Because discs have a restricted blood supply, they can't easily heal themselves once they've been harmed. The following are examples of age-related disc alterations (Fig. 4) [6]

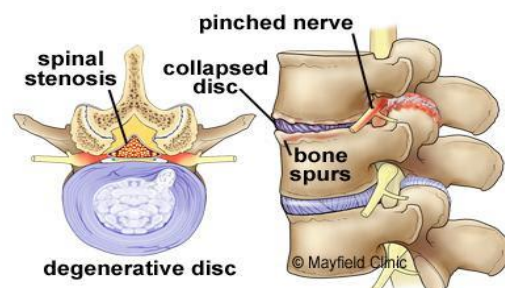


Fig.4: Drawing of a degenerative disc that is dried out and collapsed, reducing the disc space between vertebrae. Bone spurs and tears in the annulus may lead to herniated discs, pinched nerves and spinal stenosis.

Discs dry out and shrink- the disc nucleus is made up of around 80% water, therefore it dries up and shrinks. It gradually loses water and elasticity as you age, putting increasing stress on the disc annulus. **Small tears in the annulus** -occur, and the gel-like nucleus can sometimes push through a tear in the wall, touching neighboring nerves. Inflammatory proteins in this substance can irritate neurons and produce pain. Tears in the annulus also damage microscopic nerves in the annulus, causing discogenic pain and disc micro-motion instability. The proteins in the discs dry out with time, making them stiffer. **Disc gets thinner** - due to the loss of water, the discs get thin and the distance between vertebrae begin to collapse. Which is why we get shorter as we age. **Bone spurs grow** -the vertebrae can rub against each other if the discs aren't holding them apart, resulting in aberrant bone formation. **Excess motion** – abnormal rubbing adds stress to the facet joints. Pinched nerves may result in back or leg pain (sciatica). Spinal canal narrows as a result of the increased stress, the ligaments and facet joints grow (hypertrophy) to compensate and distribute the load across a greater area. The spinal canal narrows as a result of this overgrowth, which can cause discomfort by compressing the spinal cord and nerves (see Spinal Stenosis).[6]

Disc Desiccation: Disc desiccation is a normal part of aging. The discs can become smaller and less flexible as they dehydrate, and can eventually start to break down or degenerate. The symptoms of desiccation depend on the area of the spine that is affected. *Cervical spine disc desiccation cause neck pain*, while lumbar disc desiccation will cause pain in the lower back. Other symptoms of disc desiccation include: *stiffness, weakness, burning or tingling sensation, numbness in the legs or feet, reduced or painful movement, sciatica*. Aging is the most common cause of desiccated discs, though it can occur in younger people as well. *Disc desiccation and degenerative disc disease are among the most common causes of lower back pain*. [8]. In E. section we have added some diagnosed MRI sample spine images from doctor fig.(a), fig.(b), fig.(c), fig.(d), fig.(e)and fig.(f)

C. Causes of Spine Disorders.

Mechanical stress, genetic factors, and disc degeneration due to nutritional disorders are the factors influencing intervertebral disc degeneration [12-13]. The endplate is important in the progression of disc degeneration and low back pain. Clarification of the mechanisms governing endplate degeneration, as well as advances in clinical imaging that allow for precise evaluation of endplate function and dysfunction, will distinguish the correlative vs. causative nature of endplate damage and inspire new treatments that target pathologic endplate function [11].

Spine disorders have a wide variety of causes depending on the particular condition. For some conditions, the causes are unknown. Common causes include [4]:

- Accidents or falls
- Congenital disorders (present since birth)
- Inflammation
- Infection
- Inherited disorders
- Injuries ranging from minor to traumatic
- Degenerative wear and tear that comes with aging.

A combination of hereditary and environmental factors causes intervertebral disc disease. While some of these factors have been recognized, many others are still unknown. Variations in numerous genes have been discovered that may influence the likelihood of developing intervertebral disc disease. The most typically related genes give instructions for making collagen-like proteins. Collagens are a type of protein that helps connective tissues like skin, bone, cartilage, tendons, and ligaments to stay strong and healthy. Collagens form a

network of fibers that provide the intervertebral discs shape and stability. Specific polymorphisms in numerous collagen genes appear to influence the likelihood of developing intervertebral disc disease by reducing the capacity of collagens to interact with one another, lowering the disc's stability and causing it to degenerate. Intervertebral disc disease has been linked to variations in genes that play a role in the development and maintenance of the intervertebral discs and vertebrae. Other genetic alterations linked to an increased risk of intervertebral disc degeneration are being investigated by researchers.[3]

Nongenetic factors that influence the risk of intervertebral disc disease are being investigated as well. Aging, smoking, obesity, chronic inflammation, and long-distance driving are some of these risks (for example, as a long-haul trucker or taxi driver).[3]

The surgical approach to foraminal disc herniations became popular and was widely used in the lumbar region. Compression of the dorsal root ganglion within the foramen has been reported as one cause of severe radicular pain in patients with foraminal disc herniation.[9]

D. Risk Factors for Spine Disorders:

Changes in the motion and loading pattern of the degenerated segments and adjacent normal segments were caused by degenerated discs. The abnormal load and motion in the degenerated models posed a risk of hastening degeneration in adjacent normal segments. Furthermore, accurate simulation of degenerated facet joints is required for predicting changes in facet joint loads as a result of disc degeneration [14].

Factors that can increase the risk of developing a spine disorder include [4]:

- Excess weight or obesity
- Improper lifting techniques
- Nutrition and lifestyle habits such as sedentary lifestyle, low calcium intake, or smoking
- Other conditions such as osteoarthritis, rheumatoid arthritis, or thyroid disease
- Overuse from exercise or occupational movement
- Poor posture
- Repetitive strenuous activities

E. Symptoms of Spine Disorders:

Signs and symptoms depend on the specific spine disorder and often affect other parts of the body, depending on the area of the spine or spinal cord that is affected. Common symptoms include [4]:

- Abnormally rounded shoulders or back
- Back or neck pain that can be sharp and stabbing, dull and aching, or burning.
- Bladder or bowel dysfunction
- Nausea and/or vomiting
- Pain radiating in the arms or legs
- Stiffness or tightness
- Uneven appearance, such as one shoulder or hip being higher than the other
- Weakness, numbness, or tingling in the arms or legs

F. Diagnosis of Spine Disorders[4]:

Most diseases can now be detected using medical imaging techniques such as MRI and CT scans. These images can help physicians make professional decisions about the best treatment methods for their patients. Due to complex composition of our spine, which includes the spine bones, cartilage, fat, water, and soft tissue, it is difficult to correctly

identify the position of each piece of cartilage in the spinal images. In such complex settings, using traditional MRI image processing will result in either over-segmentation or inaccurate segmentation results[9].

At UT Southwestern, our spine experts conduct a thorough evaluation, including:

- Physical exam
- Discussion of personal and family medical history.
- Discussion of symptoms and risk factors
- Neurological exam, if a nerve injury or disorder is suspected

Depending on each patient’s individual case, our doctors might recommend one or more tests, such as:

- Magnetic resonance imaging (MRI) scan: MRI uses radio waves and a strong magnet to produce detailed images of the spine. MRI is useful in detecting injuries and disorders in soft tissue such as muscles, ligaments, tendons, spinal cord, and nerves.
- Computed tomography (CT) scan: CT uses specialized X-rays with or without a contrast agent to produce cross-sectional, 3D images of the spine. CT provides images that are more detailed than plain X-rays for evaluating bone injuries or disorders.
- X-ray: We use X-rays of the neck or different areas of the back to check for bone problems such as fractures, other injuries, and chronic disorders.
- Biopsy: If cancer is suspected, our neurosurgeons can take a small tissue sample for analysis under a microscope.
- Electromyography (EMG):Electrodiagnostic examinations measure electrical activity generated by muscles and nerves. They generally involve seeing how different parts of the body react to stimuli.

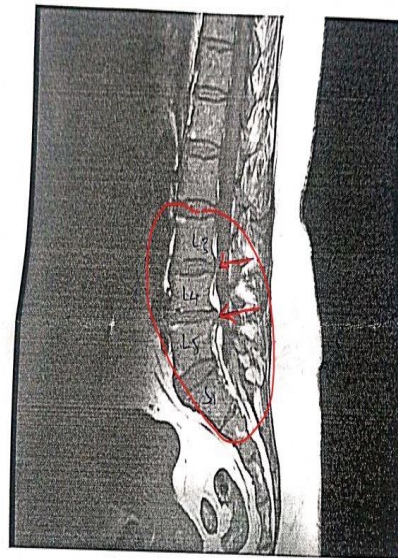
E. Diagnosis of MRI Spine images from doctor:

In the following Fig.5 , Fig.6, Fig.7, and Fig.8 show the analysis of MRI image from the doctor to find out the location of disc protrusion with compression of spinal cord. Fig.5 show the disc protrusion but no cord compression. Fig.5 show the disc protrusion in Lumber region at L4-L5 but no cord compression. Fig.6 show the disc prolapse at L3-L4-L5. Fig.7 show the disc prolapse at L4-L5. Fig.8 show the Normal image.

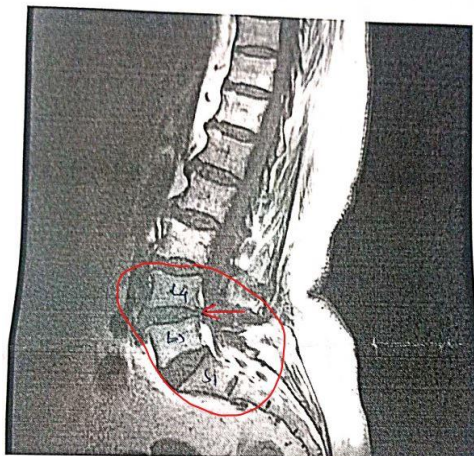

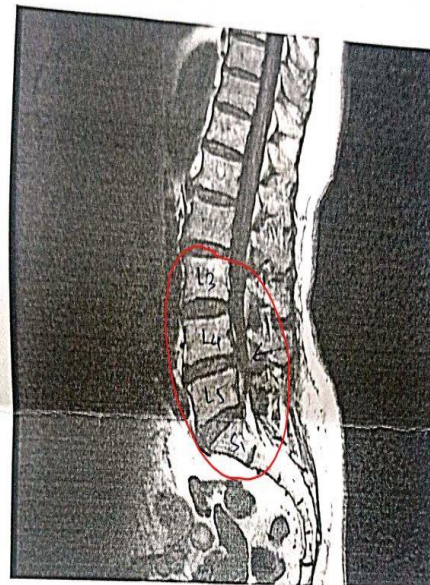Fig.5:

L4-5 Disc protrusion seen, No cord compression



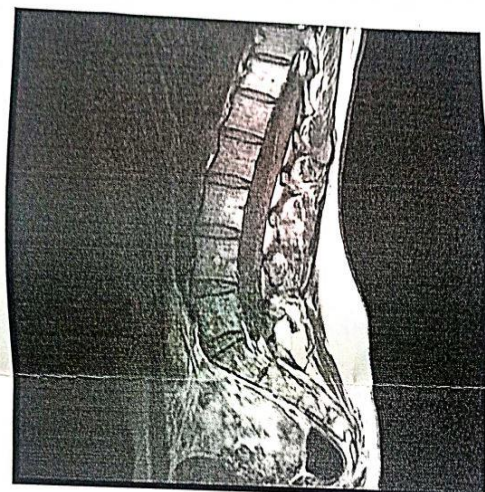- Disc prolapse @ L4-L5 i cord compression
- Disc protrusion @ L3-4 E out —||—

Fig.6:



L4-L5 - Disc prolapse i Cord compression

Fig.7:



Normal.

Fig.8:

REFERENCES

- [1] International Society for the Study of the Lumbar Spine Lumbar Spine Online Textbook –Content <https://www.wheelessonline.com/ISSLS/lumbar-intervertebral-discs-anatomy/>
- [2] Cervical Spine Anatomy <https://www.spinehealth.com/conditions/spine-anatomy/cervical-spine-anatomy>
- [3] U.S. National Library of Medicine <https://medlineplus.gov/genetics/condition/intervertebral-disc-disease/>
- [4] UT Southwestern Medical Center, <https://utswmed.org/conditions-treatments/spine-disorders/>
- [5] Lumbar Spine Anatomy and Pain <https://www.spine-health.com/conditions/spine-anatomy/lumbar-spine-anatomy-and-pain>
- [6] The Mayfield Clinic of Cincinnati, Ohio, has treated hundreds of thousands of patients since its establishment in 1937 by Frank H. Mayfield, MD. Internationally recognized as a leader in neurological surgery <https://mayfieldclinic.com/pe-ddd.htm>. <https://www.medicalnewstoday.com/articles/322121>.
- [7] A. W. Hardjasudjana et al., “Image Analysis of Spine and Related Mechanical Investigations,” 2017 IEEE Int. Conf. Comput. Intell. Comput. Res. ICCIC 2017, pp. 1–4, 2018, doi: 10.1109/ICCIC.2017.8524572.
- [8] M. Arslan et al., “Nerve root to lumbar disc relationships at the intervertebral foramen from a surgical viewpoint: An anatomical study,” *Clin. Anat.*, vol. 25, no. 2, pp. 218–223, 2012, doi: 10.1002/ca.21213
- [9] M. C. Wu and C. A. Fang, “Degenerative disc segmentation and diagnosis technology using important features from MRI of spine in images,” Proc. - 3rd Int. Conf. Inf. Secur. Intell. Control. ISIC 2012, pp. 190–193, 2012, doi: 10.1109/ISIC.2012.6449738.
- [10] <https://www.ncbi.nlm.nih.gov/pmc/articles/PMC7007629/#ref12>
- [11] Fields AJ, Ballatori A, Liebenberg EC, Lotz JC. Contribution of the endplates to disc degeneration. *Curr Mol Biol Rep.* 2018;4(4):151–160. [PMC free article] [PubMed] [Google Scholar]
- [12] McGirt MJ, Ambrossi GL, Dato G, Sciubba DM, Witham TF, Wolinsky JP, et al. Recurrent disc herniation and long-term back pain after primary lumbar discectomy: review of outcomes reported for limited versus aggressive disc removal. *Neurosurgery.* 2009;64(2):338–345. [PubMed] [Google Scholar].
- [13] Urban JP, Smith S, Fairbank JC. Nutrition of the intervertebral disc. *Spine.* 2004;29(23):2700–1709. [PubMed] [Google Scholar]
- [14] Biomechanical Effect of L4 -L5 Intervertebral Disc Degeneration on the Lower Lumbar Spine: A Finite Element Study. Cai XY, Sun MS, Huang YP, Liu ZX, Liu CJ, Du CF, Yang Q. *Orthop Surg.* 2020 Jun;12(3):917-930. doi: 10.1111/os.12703. Epub 2020 May 31. PMID: 32476282 Free PMC article.

