



THE REVIEW ON LARYNGEAL CANCER AND IT'S TREATMENT

¹Mr. Nitesh Barote, ²Mrs. Anjali Mali, ³Dr. Gajanan Sanap, ⁴Mr. Aniket Bankar, ⁵Mr. Sudarshan Chavan

¹Student, ²Assistant Professor, ³Principal, ⁴Student, ⁵Student

¹Department of Pharmacy,

¹Late Bhagirathi Yashwantrao Pathrikar College of Pharmacy, Pathri, Aurangabad, 431001. Maharashtra, India.

Abstract: Laryngeal cancers stays one of the maximum common tumors of the breathing tract. Fortunately, so many improvements had been made over the last decade with inside the treatment of laryngeal cancers. Although surgical treatment has been the historic mainstay for localized disorder and nevertheless is an necessary a part of treatment, non-surgical alternatives like radiation and systemic treatment have emerged as possible alternatives. In addition, the metastatic setting, novel dealers are displaying promise for this affected person population. The general laryngectomy, open partial laryngectomy and trans oral microsurgery is likewise defined on this evaluation with the results of the surgical treatment. The take care of sufferers with laryngeal cancers keeps to adapt and simply calls for a multidisciplinary team primarily based and totally approach. Unique morbidities, including lack of herbal voice, respiration, and airway safety at some stage in swallowing, are located with this disorder and require unique consideration.

Keywords - Laryngeal Cancer, Larynx, Squamous cell carcinoma, Laryngectomy, Glottis, Subglottis, Supraglottis.

I. INTRODUCTION

“Laryngeal cancers is a form of most cancers that develops with inside the laryngeal tissues (the region of the throat that consists of the vocal cords and is used for swallowing, breathing, and talking). Squamous cell carcinoma is the maximum common form of laryngeal cancers (most cancers that begins the lining of flat cells of the larynx).”^[1] Despite the appearance of latest and progressive strategies in radiation, chemotherapy, and surgical procedure, the multidisciplinary treatment of sufferers with intermediate to superior laryngeal cancers stays a difficult medical problem. For a century, overall laryngectomy changed into taken into consideration the best healing method to this disease. In 1991, the Veterans Affairs examine shifted the pendulum of treatment away from primary surgical procedure toward ‘organ preservation’, counting on induction chemotherapy and radiation treatment. The Radiation Therapy Oncology Group (RTOG) 91–eleven later set up the efficacy of radiation treatment with concurrent chemotherapy for ‘laryngeal preservation’, however confirmed that concurrent chemoradiation changed into related to diminished overall survival and better long-time period toxicity, in comparison to induction chemo-therapy and radiation.^[1] Laryngeal cancers is expected to account for 13,150 new instances and 3710 deaths withinside the United States in 2018. With the lower in tobacco use, the occurrence of laryngeal cancers has been reducing 2.4% each year for the remaining 10 years.1 Nonetheless, the 5-year survival rate of 60.9% has modified little over the last numerous years. About 0.8% of all new most cancers instances and 0.6% of all most cancers deaths arise in sufferers with laryngeal cancers.^[2]

In 2016, an estimated 13,430 new instances of laryngeal cancers can be diagnosed, with about 3620 sufferers loss of life from the disease.^[3] Laryngeal cancers happens greater usually in men than in women (5.8 cases per 100,000 vs 1.2 per 100,000, respectively).^[4] Targeted treatment is the corner stone of current most cancers treatment. For cancers which can be absolutely characterized with the aid of using uniquely aberrant markers, retailers that inhibit or goal those markers are super therapeutics with minimum negative results on regular tissues. The medical achievement of imatinib (Gleevec®), for example, which goals the Bcr-Abl tyrosine kinase, is at once because of the particular and informal function of the Bcr-Abl oncoprotein in continual myeloid leukemia and related “Philadelphia chromosome” leukemias ^[1]. During the beyond decades, the improvement of novel strategies to focused on the transport and activation of prodrugs has been rapid, varied, and impressive. The information of those advances were documented in numerous latest reviews.^[2–6] Here, our intention is to offer a unified view of the prodrug idea in focused most cancers treatment. Specifically, we are able to spotlight the useful equivalence of reputedly disparate cell-focused on schemes, and the way such schemes can also additionally supplement every different in focused on complicated most cancers phenotypes primarily based totally on or extra molecular markers.

II. EPIDEMIOLOGY OR PATHOGENESIS

There are racial disparities discovered in laryngeal cancers, with African Americans presenting at a more youthful age and having a better prevalence and mortality as compared with Caucasians.^[5-7] Approximately 60% of sufferers present with advanced (level III or IV) sickness at diagnosis.^[8] Laryngeal cancers refers nearly completely to squamous carcinomas, even though the larynx can be a ability site for all histological forms of neoplasms; the prevalence top is withinside the 6th and 7th decade of life (10-20), however a few instances have additionally been mentioned in children.^[9] Laryngeal cancers is the 11th most common most cancers in men global-extensive with an estimate of 121000 new instances in 1985.^[10] From round 1950 onwards, laryngeal cancers has been visible to increase in prevalence in lots of international locations, each in men and ladies. Incidence is better amongst black than in white citizens of the equal geographical area, and is barely extra common in city than in rural areas.^[11,12] In the United States (Texas), the prevalence has extended from 5.6 to 9.0 in line with 100000 in guys and from 0.5 to 1.5 in line with one hundred thousand in ladies all through the duration 1947-1984.^[13] In Europe, Spain is one of the international locations with the very best prevalence withinside the global and with a big range of areas involved: the Basque area has an prevalence fee of 20.4, Navarra 17.8, Granada 16.2 and Zaragoza 16.1.^[14-15]

Other international locations with excessive costs of laryngeal cancers include: France, Poland, Italy and Brazil. In Poland (Warsaw), the occurrence in keeping with one hundred thousand has risen in guys from 7.6 in 1970 to 11.4 in 1980 and in the course of the identical length mortality has additionally risen.^[16] The sequelae of treatment for laryngeal cancers with modalities consisting of surgery, radiation, and chemoradiation handiest provides to the weight of implications. Treatment for laryngeal cancers has developed from radical resections and in depth radiation or chemo-radiation. Although presenting the capability for cure, such sizeable multimodality treatment frequently ended in bad best of existence with in addition deterioration withinside the capabilities of swallowing, breathing, and voice. The treatment of laryngeal cancers in extra latest a long time has therefore aimed to maintain the larynx, therefore enhancing best of existence, with out sacrificing survival costs.^[17]

III. BASIC ANATOMY OF LARYNX

To The larynx consists of a complicated framework of cavities, cartilages, muscles, membranes, ligaments, and mucosal surfaces. The larynx features to keep a protected, patent airway at the same time as functioning in vocalization.

The anatomic sub regions of the larynx include

1. The Supraglottic Larynx
2. The Glottic Larynx
3. The Subglottic Larynx

Tumor involvement of every anatomic location affords a exceptional medical presentation and gives its personal demanding situations for treatment. The supraglottic larynx consists of the laryngeal surface of the epiglottis, aryepiglottic folds, arytenoids, and fake vocal cords, and is described because the part of the larynx advanced to and along with the fake vocal cords or vestibule. The supraglottic larynx is separated from the glottic larynx through a hollow space referred to as the laryngeal ventricle, a area bounded above through the false vocal cords and under through the real vocal cords. Difficult visualization of the ventricle can permit for an occult malignancy to head undetected.

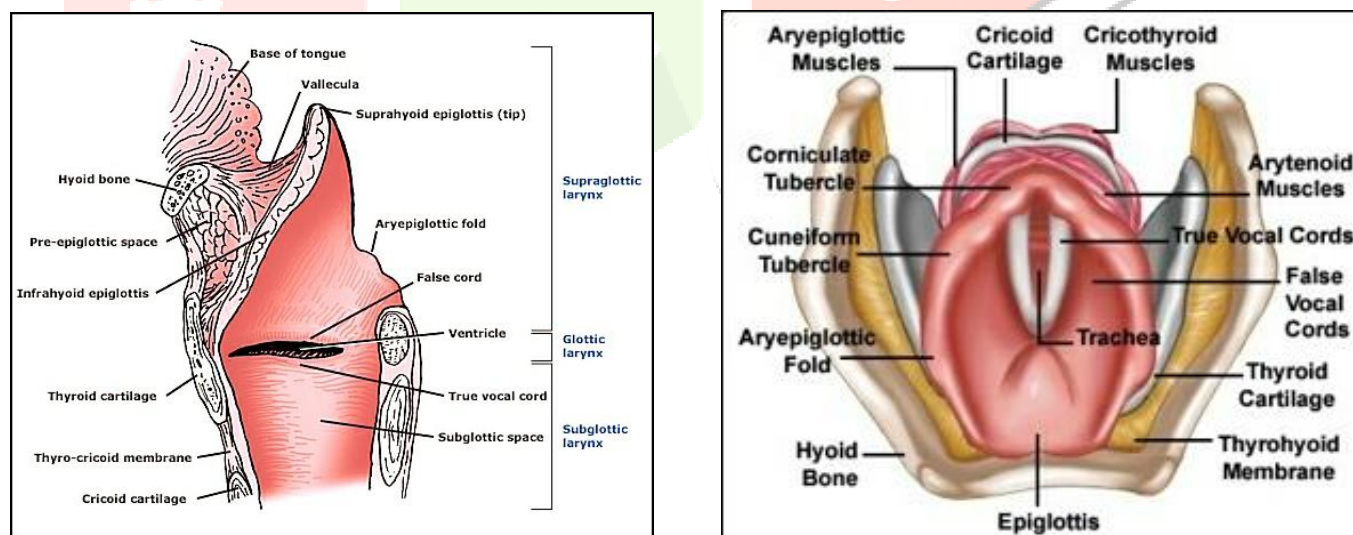


Fig. 1 & Fig. 2: - Figures of Larynx -
 1) Sagittal view showing the positions of –
 Supraglottis, Glottis, and Subglottis
 2) Top view of Larynx

At the maximum anterior quantity of the ventricle, or saccule, an air-filled laryngocele as a result of obstruction may also bring in the presence of tumor detected handiest by endoscopic evaluation. The glottic larynx includes the true vocal cords, consisting of the paraglottic space, in addition to the anterior and posterior commissures, consisting of the inferior floor of the true cords. The subglottic larynx extends from the inferior factor of the true vocal cords to the inferior fringe of the cricoid cartilage. The velocity of airflow through the larynx is ruled by the Bernoulli principle, which states that a increase withinside the pace of flow through a system happens concurrently with a lower in stress. Therefore, the assist of a inflexible framework is needed for the larynx to stay patent and to prevent disintegrate of the mucosal surfaces as airflow will increase in the larynx and because the stress inside

decreases. Thus, the thyroid cartilage presents enough assist for retaining the patency of the airway at the same time as the cricoid cartilage presents an crucial basis to the larynx.^[18]

IV. PATHWAYS OF SPREAD

Cancer of the larynx has a tendency to be contained in the primary systems of the larynx. However, there are numerous pathways of spread to allow for extrinsic tumor spread without thyroid cartilage invasion. Chen et al checked out 103 laryngectomy specimens and cited that handiest 44% of T4 tumors had cartilage penetration ensuing in extrinsic comparable laryngeal spread.^[19]

The thyroarytenoid gap, that's the space among the arytenoid and thyroid cartilage, can permit for extrinsic laryngeal spread of tumor in a posterior lateral direction. Tumors withinside the pre-epiglottic space can hypothetically invade through Broyle's ligament, wherein the authentic vocal cords are suspended to the cartilage, with very little cartilaginous erosion. This is notion to be associated with a weak point withinside the perichondrium on the insertion factor of those ligaments. Otherwise, the tumor can spread through the cricothyroid or thyrohyoid membranes. Finally, the tumors can unfold at once thru the cartilage of the larynx. Regardless of the direction of spread, extrinsic tumor extension upstages the affected person to T4 status.^[20]

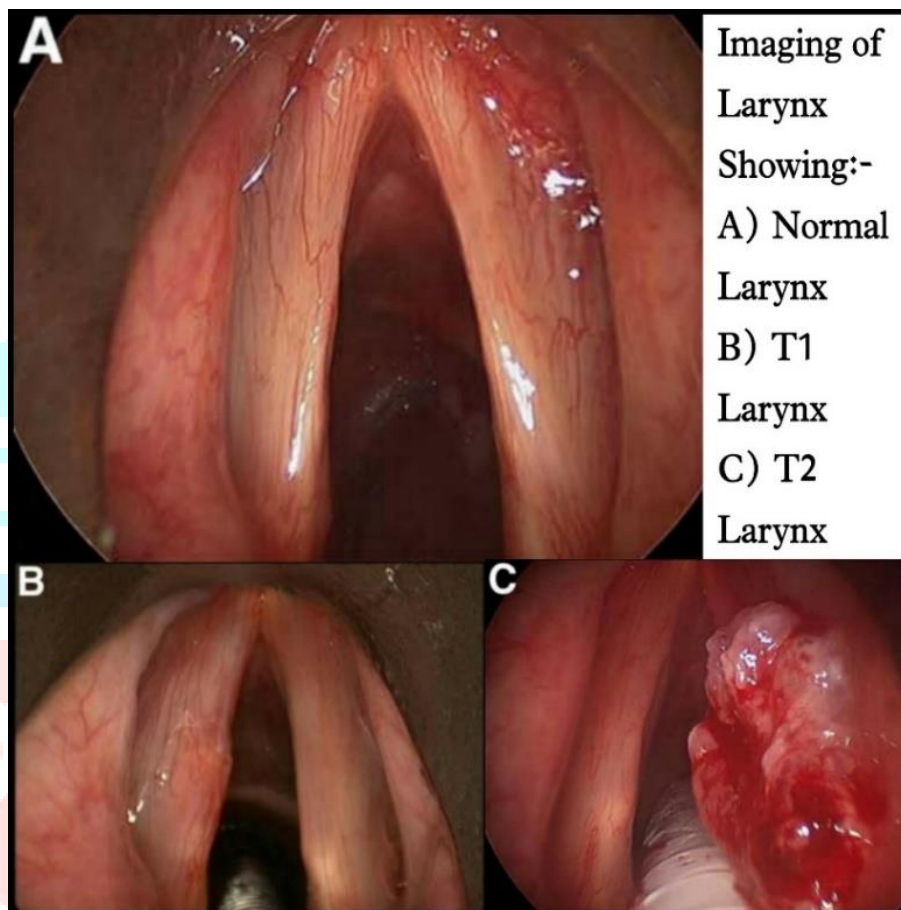


Fig 3: - (A) Normal Larynx,
(B) T1 Larynx: The tumor is only in the subglottis, and
(C) T2: The tumor has spread to the vocal cords.

V. RISK FACTORS OF LARYNGOPHARYNGEAL CANCER

Alcohol and tobacco are the two primary chance elements for laryngeal cancers. The chance is proportional to the depth and period of intake and the chance decreases after cessation of consumption. There is inadequate proof to help the causal function of laryngopharyngeal reflux and laryngeal cancers, specially because of confusion of the tobacco and alcohol results and inaccuracies withinside the analysis of reflux.^[21] All incident instances of laryngeal cancers admitted to the Ear, Nose, and Throat Ward of the University Hospital Of Montevideo withinside the 1-12 months length from June 1985 to May 1986 have been covered withinside the study. All 107 instances confirmed biopsy demonstrated analysis of squamous cell carcinoma. Females have been few in range and therefore, excluded, ensuing in male restrict inside an age variety from 30 years to 89 years. As controls, 290 sufferers admitted to the identical medical institution withinside the identical term with sicknesses taken into consideration now no longer associated with tobacco or alcohol exposures have been entered into the study.^[22] An accelerated consumption of end result and greens is related to a decrease chance of head and neck most cancers in all subtypes, because of this that that this may be a protecting thing for laryngeal cancers.^[23] The nutritional records noted regular person frequency of intake of greens and end result previous to the onset of illness (instances and controls). Patients have been requested to record their frequency of intake of general greens and general end result in accordance six classes (five to 7 days consistent with week, three to four days consistent with week, 1 to 2 days consistent with week, 1 to 3 days consistent with month, rare, and never). Later on, classes 1 to a few days consistent with month and rare have been consolidated as rare use, while classes three to four days consistent with week and 1 to two days consistent with week have been consolidated as weekly intake. Odds ratios (OR) have been calculated and manage of confounding turned into carried out through stratified evaluation the use of the Mantel and Haenszel method.^[22] The affect of human papilloma virus on

laryngeal cancers has additionally been associated, maximum often with subtypes sixteen and 18. It has been detected in 21% of superior laryngeal cancers, maximum normally detected in ladies in comparison to men.^[24]

VI. CLINICAL PRESENTATION

Physical examination should consist of a cautious assessment of the neck and an endoscopic assessment to evaluate the quantity of tumor and the steadiness of the airway. Laryngoscopy withinside the awake affected person is of maximum significance withinside the on the spot assessment of the dynamic characteristic of the larynx, consisting of the patency of the airway, the mobility of the vocal cords, and the feasibility of endotracheal intubation. Laryngoscopy is likewise vital in determining the quantity of tumor involvement of the larynx and the correct T stage.^[25]

The medical presentation of a affected person with laryngeal cancers relies upon at the anatomic place of the larynx involved. Patients with supraglottic tumors, wearing a better propensity for lymph node metastasis, can also additionally present with a neck mass, or with neighborhood signs of dysphagia, muffled voice, or airway compromise for large tumors. Patients with glottic tumors can also additionally frequently present with chronic hoarseness, referred otalgia, dysphagia, persistent cough, stridor, and hemoptysis. Those with subglottic tumors can also additionally present with stridor and dyspnea on exertion, signs traditional of constant airway lesions.^[18] In addition to endoscopic assessment of the airway, the steadiness of the airway from imminent obstruction is decided through the affected person's stage of issue respiration, using accent muscles, the extent of fatigue, intellectual status, and the depth of stridor. As respiration fatigues and the quantity of airflow decreases, the degree of stridor can also additionally satirically lower as obstruction ensues. For imminent airway obstruction, organising a solid airway is the most motion to save you asphyxiation. Endoscopic assessment facilitates to decide whether or not endotracheal intubation is viable or if the airway may be thoroughly secured most effective through unsleeping tracheostomy. In an emergency, cricothyrotomy can also additionally stabilize the imminently or already obstructed airway. The feasibility of intubation is decided through the supply of physicians skilled withinside the control of the tough airway and the get entry to to armamentarium, consisting of specialised or video laryngoscopes and intubating endoscopes.^[18-25]

VII. STAGING

The staging of laryngeal cancers is decided with the aid of using the subsite of involvement of the larynx with the aid of using disease, and for that reason calls for a radical expertise of laryngeal anatomy. The staging type for most cancers of the larynx is decided with the aid of using the volume of subsite involvement with the aid of using the number one tumor, the mobility of vocal cords, extranodal extension, and the presence of metastases. American Joint Committee provided Cancer's TNM staging device on laryngeal cancers.^[26]

Category	Subglottic	Supraglottic	Glottic
T1	Subglottic involvement only	Limited to 1 subsite of supraglottis Normal Vocal Cord Mobility	True vocal cord involvement only
-T1-a	-	-	Singular vocal cord involvement
-T1-b	-	-	Bilateral vocal cord involvement
T2	Extension to vocal cords	Invasion of adjacent subsite of supraglottis or glottis or region outside of the supraglottis without fixation of larynx	Extension to supraglottis or subglottis and/or impaired vocal cord mobility
T3	Extension to larynx with vocal cord fixation and/or inner cortex of thyroid cartilage involvement	Limited to larynx with vocal cord fixation and/or invasion of postcricoid area, preepiglottic space, paraglottic space, or inner cortex of thyroid	Limited to larynx with vocal cord invasion and/or invasion of paraglottic space and/or inner cortex of thyroid cartilage
T4-a	Invasion through cricoid or thyroid cartilage and/or invasion of tissues beyond the larynx	Invasion through outer cortex of thyroid cartilage and/or invasion of tissues beyond the larynx	Invasion through outer cortex of thyroid cartilage and/or invasion of tissues beyond the larynx
T4-b	Invasion of prevertebral space, carotid artery encasement, or invasion of mediastinal structures	Invasion of prevertebral space, carotid artery encasement, or invasion of mediastinal structures	Invasion of prevertebral space, carotid artery encasement, or invasion of mediastinal structures

Data of Table Taken from:- Amin MB, Greene FL, Edge SB, Compton CC, Gershenwald JE, Brookland RK, Meyer L, Gress DM, Byrd DR, Winchester DP. DP: AJCC Cancer Staging Manual.

VIII. SURGICAL ASPECTS OF LARYNGEAL CANCER

Some of the surgical considerations for the laryngeal cancer are explained below.

1. Transoral Laser Microsurgery

Transoral laser microsurgery is a minimally invasive endoscopic method that mixes using suspension laryngoscopy with an working microscope, a tissue-cutting laser, and microsurgical devices to resect a number one tumor. Carbon dioxide and Nd:YAG lasers produce a beam with a frequency of mild this is absorbed through water, minimizing tissue damage. The tumor is both resected en bloc or piecemeal, relying at the surgeon's discretion. In en bloc resection, the tumor is completely excised with a cuff of surrounding normal-performing tissue on the peripheral and deep aspects. Conversely, in a piecemeal resection, the tumor is first transected on the epicenter to decide the intensity of invasion after which eliminated in quadrants extending into the normal-performing surrounding tissues. Preserving at the least 1 cellular arytenoid complicated is needed to hold laryngeal function.^[27] Unlike open partial laryngectomy, The cartilage framework of the larynx is preserved intact in transoral laser microsurgery, presenting much less want for tracheostomy, greater fast go back of post-operative swallowing, and shorter health center stays. The oncologic outcomes of transoral laser microsurgery had been proven to be le with open partial laryngectomy.^[28-32]

Postoperative voice exceptional varies through the volume of tumor, with superior outcomes for T1 membranous vocal twine lesions and supraglottic tumors that don't contain the vocal twine. Voice exceptional after surgical procedure is bad for cancers regarding the arytenoid or the ones extending into the paraglottic space.^[25] The practical blessings are maximum superior best whilst transoral laser microsurgery is used as the only modality of therapy. Adjuvant postoperative radiotherapy for a wonderful margin, although narrow, will increase the morbidity of treatment and compromises the restoration of swallowing.^[33] Therefore, deciding on the approach of transoral laser surgical procedure closely relies upon at the excessive chance of reaching entire microscopic resection.^[25]

2. Total Laryngectomy

TL is the standard treatment for superior level laryngeal cancers for sufferers now no longer amenable to organ upkeep regimens posed via way of means of widespread thyroid cartilage invasion, extralaryngeal spread, or more than one and extreme comorbidities. TL eliminates the whole larynx, strap muscles, paratracheal lymphatics, and the ipsilateral thyroid lobe in a few cases.^[18]

Although TL regularly gives the fine probabilities for cure, the effects are a everlasting tracheostoma and the lack of local voice. The maximum common headaches of TL are wound contamination and pharyngocutaneous fistula, happening in as much as 50% of formerly radiated sufferers.^[34] Therefore, pedicled or loose vascularized tissue flaps to cowl the reconstructed pharyngeal closure in the course of salvage TL can be suggested to lower the danger and severity of fistulas.^[18,25,35]

3. Open Partial Laryngectomy

Open partial laryngectomy is a way of conservation laryngeal surgical procedure that contains a large array of open surgical techniques, starting from hemilaryngectomy to supracricoid partial laryngectomy. The headaches of open partial laryngectomy consist of bleeding, infection, laryngocutaneous fistula, bad wound restoration, airway obstruction that necessitates a tracheostomy, aspiration pneumonia, dysphagia, and dysphonia.^[36] Horizontal partial laryngectomy, or supraglottic laryngectomy, includes resection of the complete part of the larynx positioned above the glottis, such as epiglottis and preepiglottic space, even as maintaining each proper vocal cords and arytenoids.^[34] A transient tracheostomy and a nasogastric feeding tube are required in maximum sufferers postoperatively for four to six weeks. However, the rehabilitative manner can be slowed similarly via way of means of not on time restoration from preoperative radiotherapy, plans for postoperative radiation therapy, or from prolonged surgical resection.^[37] Similar to vertical partial laryngectomy, the function of horizontal partial laryngectomy in conservation surgical procedure has been diminishing by transoral laser microsurgery. Nonetheless, horizontal partial laryngectomy can be provided to pick sufferers with tumor extending past the conventional boundaries, which incorporates T3 and T4 supraglottic tumors related to 1 vocal twine and 1 arytenoid and increasing into the pyriform sinus or base of the tongue.^[34,37]

Vertical partial laryngectomy, or hemilaryngectomy, is a system for decided on T1 and T2 glottic cancers. Vertical incisions are made via the thyroid cartilage close to the anterior commissure and simply anterior to the posterior fringe of the thyroid cartilage, resecting the true vocal wire and instantaneously subglottis, ventricle, fake vocal wire, and aryepiglottic fold. Although time honored, vertical partial laryngectomy is now seldom completed because the development of transoral laser microsurgery, which presents same manipulate rates and advanced voice and swallowing characteristic for tumors amenable to vertical partial laryngectomy.^[37] Supracricoid partial laryngectomy is an technique to open partial laryngectomy greater lately gaining popularity. The laryngopharynx is reconstructed with the aid of using approximating the cricoid cartilage and hyoid bone to create a neoglottis with the arytenoid(s) to both the epiglottis (cricohyoidoepiglottopexy) or the base of the tongue (cricohyoidopexy), relying at the volume of resection.^[34] Although the effects of supracricoid partial laryngectomy are much like supraglottic laryngectomy for swallowing, purposeful effects for voice are much less encouraging. The voice after supracricoid partial laryngectomy is coarse and vulnerable with improved breathiness. Although sufferers lack proper pitch manipulate, maximum sooner or later reap intelligible speech even as fending off the everlasting stoma of TL.^[34,37] The want for postoperative radiation treatment ought to be prevented in any respect fees to save you compromised wound healing, restrained rehabilitative potential, and extended tracheostomy dependence.^[38] The effects of supracricoid partial laryngectomy in T2 and choose T3 tumors are much like mixed chemoradiation treatment and TL with neighborhood manipulate rates of as much as 90%.^[35,38,39]

IX. THE OUTCOMES OF SURGERY

The fulfillment of larynx preservation surgical processes relies upon on tumor extent, the surgeon's ability and expertise, and cautious affected person selection. In latest decades, the surgical control of sufferers with early to intermediate degree laryngeal cancers has shifted from open partial laryngectomy to transoral laser microsurgery.^[34] Accumulating proof helps the similar efficacy of transoral laser microsurgery and open partial laryngectomy in conjunction with reduced morbidity and stepped forward upkeep of laryngeal feature with transoral laser microsurgery. The benefits of transoral laser microsurgery consist of much less need.^[40,41,42] Open partial laryngectomy through supracricoid partial laryngectomy may also function a number one treatment for T3 supraglottic cancers now no longer amenable to endoscopic resection.^[43] Nonetheless, the function of transoral laser microsurgery is restrained especially to medical degrees I and II, and decided on III (T1 to T2N1M0) without or with radiation therapy.^[44,45]

X. CONCLUSION

It is seen that the in modern-day control of laryngeal cancers has such a lot of alternatives to be had to deal with it as early as possible. The CO2 laser has simplified and improved the scope of endoscopic management of percutaneous in addition to minimally infiltrative lesions of the vocal cords. Total laryngectomy is effective and powerful operation to the manage of superior laryngeal cancers and also in addition to many instances of radiation failure. The near-total laryngectomy is appropriate for limited and selected superior lesions. Some of the benefits may be achieved with the aid of using the open partial laryngectomy and transoral laser microscopy in laryngeal cancers. Also, the staging of laryngeal cancers like T1, T2, and T3 is explained in this review. There are such a lot of treatment alternatives, like surgical operation and medication treatment, for laryngeal cancers. Here, in this review, we have tried to give an explanation on some of them.

XI. REFERENCES

- [1] Tomeh C, Holsinger FC. Laryngeal cancer. *Current opinion in otolaryngology & head and neck surgery*. 2014 Apr 1;22(2):147-53.
- [2] Rzepakowska A, Żurek M, Niemczyk K. Review of recent treatment trends of laryngeal cancer in Poland: a population-based study. *BMJ open*. 2021 Apr 1;11(4):e045308.
- [3] DeSantis CE, Siegel RL, Sauer AG, Miller KD, Fedewa SA, Alcaraz KI, Jemal A. Cancer statistics for African Americans, 2016: Progress and opportunities in reducing racial disparities. *CA: a cancer journal for clinicians*. 2016 Jul;66(4):290-308.
- [4] Baselga J. Why the epidermal growth factor receptor? The rationale for cancer therapy. *The oncologist*. 2002 Aug;7(S4):2-8.
- [5] Goodwin WJ, Thomas GR, Parker DF, Joseph D, Levis S, Franzmann E, Anello C, Hu JJ. Unequal burden of head and neck cancer in the United States. *Head & Neck: Journal for the Sciences and Specialties of the Head and Neck*. 2008 Mar;30(3):358-71.
- [6] Shin JY, Truong MT. Racial disparities in laryngeal cancer treatment and outcome: A population-based analysis of 24,069 patients. *The Laryngoscope*. 2015 Jul;125(7):1667-74.
- [7] DeSantis C, Naishadham D, Jemal A. Cancer statistics for African Americans, 2013. *CA: a cancer journal for clinicians*. 2013 May;63(3):151-66.
- [8] Groome PA, O'Sullivan B, Irish JC, Rothwell DM, Schulze K, Warde PR, Schneider KM, Mackenzie RG, Hodson DI, Hammond JA, Gulavita SP. Management and outcome differences in supraglottic cancer between Ontario, Canada, and the Surveillance, Epidemiology, and End Results areas of the United States. *Journal of clinical oncology*. 2003 Feb 1;21(3):496-505.
- [9] Ohlms LA, McGill T, Healy GB. Malignant laryngeal tumors in children: a 15-year experience with four patients. *Annals of Otolaryngology, Rhinology & Laryngology*. 1994 Sep;103(9):686-92.
- [10] Parkin D, Pisani P, Ferlay J. Estimates of the worldwide incidence of eighteen major cancers in 1985. *International journal of cancer*. 1993 Jun 19;54(4):594-606.
- [11] Boyle P. *Multiple primary tumors in the head and neck*. Stuttgart; New York: G. Thieme; New York: Thieme Medical Publishers; 1990.
- [12] Hedberg K, Vaughan TL, White E, Davis S, Thomas DB. Alcoholism and cancer of the larynx: a case-control study in western Washington (United States). *Cancer Causes & Control*. 1994 Jan;5(1):3-8.
- [13] DeRienzo DP, Greenberg SD, Fraire AE. Carcinoma of the larynx: changing incidence in women. *Archives of Otolaryngology-Head & Neck Surgery*. 1991 Jun 1;117(6):681-4.
- [14] Espinosa J, Bravo P, Baron MG. Influence of tobacco on laryngeal carcinoma in Spain. *Neoplasma*. 1992 Jan 1;39(5):319-22.
- [15] Cattaruzza MS, Maisonneuve P, Boyle P. Epidemiology of laryngeal cancer. *European Journal of Cancer Part B: Oral Oncology*. 1996 Sep 1;32(5):293-305.
- [16] Zatonski W, Becker N. Atlas of cancer mortality in Central Europe. International Agency for Research on Cancer; 1996.
- [17] Pfister DG, Laurie SA, Weinstein GS, Mendenhall WM, Adelstein DJ, Ang KK, Clayman GL, Fisher SG, Forastiere AA, Harrison LB, Lefebvre JL. American Society of Clinical Oncology clinical practice guideline for the use of larynx-preservation strategies in the treatment of laryngeal cancer. *Journal of clinical Oncology*. 2006 Aug 1;24(22):3693-704.
- [18] Cohen JI, Clayman GL. *Atlas of Head and Neck Surgery E-Book*. Elsevier Health Sciences; 2011 Jun 6.
- [19] Chen SA, Muller S, Chen AY, Hudgins PA, Shin DM, Khuri F, Saba NF, Beitler JJ. Patterns of extralaryngeal spread of laryngeal cancer: thyroid cartilage penetration occurs in a minority of patients with extralaryngeal spread of laryngeal squamous cell cancers. *Cancer*. 2011 Nov 15;117(22):5047-51.
- [20] Mor N, Blitzer A. Functional anatomy and oncologic barriers of the larynx. *Otolaryngologic clinics of North America*. 2015 Aug 1;48(4):533-45.
- [21] Coca-Pelaz A, Rodrigo JP, Takes RP, Silver CE, Paccagnella D, Rinaldo A, Hinni ML, Ferlito A. Relationship between reflux and laryngeal cancer. *Head & neck*. 2013 Dec;35(12):1814-8.
- [22] Mantel N, Haenszel W. Statistical aspects of the analysis of data from retrospective studies of disease. *Journal of the national cancer institute*. 1959 Apr 1;22(4):719-48.
- [23] Maasland DH, van den Brandt PA, Kremer B, Goldbohm RA, Schouten LJ. Consumption of vegetables and fruits and risk of subtypes of head-neck cancer in the Netherlands cohort study. *International journal of cancer*. 2015 Mar 1;136(5):E396-409.
- [24] Hernandez BY, Goodman MT, Lynch CF, Cozen W, Unger ER, Steinau M, Thompson T, Saber MS, Altekruse SF, Lyu C, Saraiya M. Human papillomavirus prevalence in invasive laryngeal cancer in the United States. *PLoS One*. 2014 Dec 29;9(12):e115931.
- [25] Forastiere AA, Ismaila N, Lewin JS, Nathan CA, Adelstein DJ, Eisbruch A, Fass G, Fisher SG, Laurie SA, Le QT, O'Malley B. Use of larynx-preservation strategies in the treatment of laryngeal cancer: American Society of Clinical Oncology clinical practice guideline update. *Journal of Clinical Oncology*. 2018 Apr 10;36(11):1143-69.
- [26] Amin MB, Greene FL, Edge SB, Compton CC, Gershenwald JE, Brookland RK, Meyer L, Gress DM, Byrd DR, Winchester DP. *AJCC Cancer Staging Manual*.

- [27] Zeitels SM, Burns JA. Oncologic efficacy of angiolytic KTP laser treatment of early glottic cancer. *Annals of Otolaryngology, Rhinology & Laryngology*. 2014 Dec;123(12):840-6.
- [28] Vilaseca I, Blanch JL, Bernal-Sprekelsen M, Moragas M. CO2 laser surgery: a larynx preservation alternative for selected hypopharyngeal carcinomas. *Head & neck*. 2004 Nov;26(11):953-9.
- [29] Suárez C, Rodrigo JP. Transoral microsurgery for treatment of laryngeal and pharyngeal cancers. *Current oncology reports*. 2013 Apr;15(2):134-41.
- [30] Leong SC, Kathan C, Mortimore S. Early outcomes after transoral CO2 laser resection of laryngeal and hypopharyngeal squamous cell carcinoma: one centre's experience. *The Journal of Laryngology & Otolaryngology*. 2010 Feb;124(2):185-93.
- [31] Kutter J, Lang F, Monnier P, Pasche P. Transoral laser surgery for pharyngeal and pharyngolaryngeal carcinomas. *Archives of Otolaryngology-Head & Neck Surgery*. 2007 Feb 1;133(2):139-44.
- [32] Suárez C, Rodrigo JP. Transoral microsurgery for treatment of laryngeal and pharyngeal cancers. *Current oncology reports*. 2013 Apr;15(2):134-41.
- [33] Hinni ML, Salassa JR, Grant DG, Pearson BW, Hayden RE, Martin A, Christiansen H, Haughey BH, Nussenbaum B, Steiner W. Transoral laser microsurgery for advanced laryngeal cancer. *Archives of Otolaryngology-Head & Neck Surgery*. 2007 Dec 1;133(12):1198-204.
- [34] Corey A. Pitfalls in the staging of cancer of the oropharyngeal squamous cell carcinoma. *Neuroimaging Clinics*. 2013 Feb 1;23(1):47-66.
- [35] Zeitels SM, Burns JA. Oncologic efficacy of angiolytic KTP laser treatment of early glottic cancer. *Annals of Otolaryngology, Rhinology & Laryngology*. 2014 Dec;123(12):840-6.
- [36] Ganly I, Patel SG, Matsuo J, Singh B, Kraus DH, Boyle J, Wong R, Shaha AR, Shah JP. Analysis of postoperative complications of open partial laryngectomy. *Head & neck*. 2009 Mar;31(3):338-45.
- [37] Van Etten JL, Meints RH. Giant viruses infecting algae. *Annual Reviews in Microbiology*. 1999 Oct;53(1):447-94.
- [38] Forastiere AA, Ismaila N, Lewin JS, Nathan CA, Adelstein DJ, Eisbruch A, Fass G, Fisher SG, Laurie SA, Le QT, O'Malley B. Use of larynx-preservation strategies in the treatment of laryngeal cancer: American Society of Clinical Oncology clinical practice guideline update. *Journal of Clinical Oncology*. 2018 Apr 10;36(11):1143-69.
- [39] Dufour X, Hans S, De Mones E, Brasnu D, Ménard M, Laccourreye O. Local control after supracricoid partial laryngectomy for advanced endolaryngeal squamous cell carcinoma classified as T3. *Archives of Otolaryngology-Head & Neck Surgery*. 2004 Sep 1;130(9):1092-9.
- [40] Silver CE, Beitler JJ, Shaha AR, Rinaldo A, Ferlito A. Current trends in initial management of laryngeal cancer: the declining use of open surgery. *European Archives of Oto-Rhino-Laryngology*. 2009 Sep;266(9):1333-52.
- [41] Steiner W. Results of curative laser microsurgery of laryngeal carcinomas. *American journal of otolaryngology*. 1993 Mar 1;14(2):116-21.
- [42] Ambrosch P. The role of laser microsurgery in the treatment of laryngeal cancer. *Current opinion in otolaryngology & head and neck surgery*. 2007 Apr 1;15(2):82-8.
- [43] Sperry SM, Rassekh CH, Laccourreye O, Weinstein GS. Supracricoid partial laryngectomy for primary and recurrent laryngeal cancer. *JAMA Otolaryngology-Head & Neck Surgery*. 2013 Nov 1;139(11):1226-35.
- [44] Agrawal A, Moon J, Davis RK, Sakr WA, Giri SP, Valentino J, LeBlanc M, Truelson JM, Yoo GH, Ensley JF, Schuller DE. Transoral carbon dioxide laser supraglottic laryngectomy and irradiation in stage I, II, and III squamous cell carcinoma of the supraglottic larynx: report of Southwest Oncology Group Phase 2 Trial S9709. *Archives of Otolaryngology-Head & Neck Surgery*. 2007 Oct 1;133(10):1044-50.
- [45] Davis RK, Kriskovich MD, Buntin CS, Galloway III EB, Jepsen MC. Endoscopic supraglottic laryngectomy with postoperative irradiation. *Annals of Otolaryngology, Rhinology & Laryngology*. 2004 Feb;113(2):132-8.