



INTERNATIONAL JOURNAL OF CREATIVE RESEARCH THOUGHTS (IJCRT)

An International Open Access, Peer-reviewed, Refereed Journal

Herpes Zoster [Shingles]-A Review

Hrithik J. Haral^{*1}, Pooja S. Hirade² Meghana Raykar³

Department of Pharmacy,

¹²³HSBPVT'S GOI, Faculty of Pharmacy,

Kashti, Shrigonda, Ahmadnagar

*Address for Correspondence

Department of Pharmacy,

HSBPVT, GOI, Faculty of Pharmacy,

Kashti, Shrigonda, MH, India.

ABSTRACT:-

Background: Herpes zoster (HZ), the reactivation of varicella zoster virus, occurs in 1 in 5 people global and may result in a variety of difficult, including post herpetic neuralgia (PHN). Treatment of patients with HZ shown a considerable challenge, especially among the elderly who are prone to get a more severe form of the disease and its complications. Since May 2006, a vaccine was approved for the avoidance of HZ or PHN among separate aged 50 or 60 years and older.

Treatment with antiviral drugs and analgesics within 72 hrs of rash onset has been shown to reduce seriousness and difficulties associated with herpes zoster and post-herpetic neuralgia. Herpes Zoster study mainly focuses on herpes zoster using articles and reviews from PubMed, Embase, Cochrane library, and a handbook find from Google Scholar. We cover the event of herpes zoster, gender distribution, recurrent and topical distribution of herpes zoster, incidence of herpes zoster among immune compromised separate, incidence of post-herpetic neuralgia following a zoster infection, complications, management, and avoidance of herpes zoster and post-herpetic neuralgia.

Keywords:- Herpes zoster-[HZ]; post herpetic neuralgia; varicella zoster virus –[VZV],shingles

INTRODUCTION:-

Herpes zoster (HZ), also called as shingles, is generally characterised by painful, blistering dermatomal rash.^{1,2} The approximately

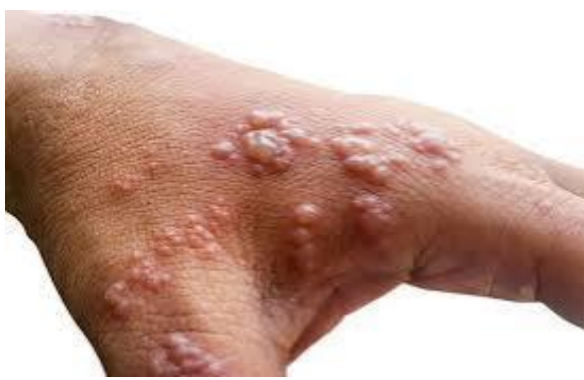

Figure 3: Skin infection herpes zoster virus

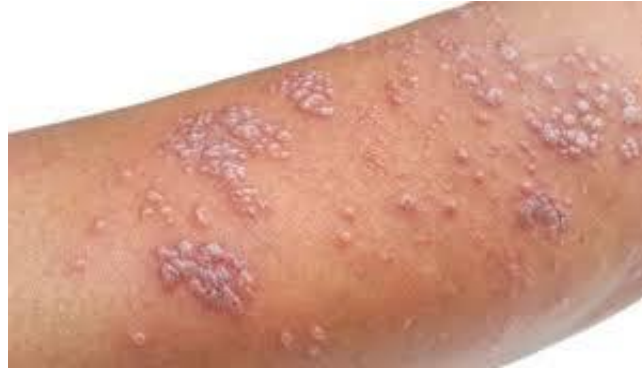

Figure 2: Skin infection herpes zoster virus

lifetime risk of HZ in the general population is approx. 30%, with the risk increase sharply after 50 years of age.³ After conducting a careful long-term monitoring study in the 1960s, Hope-Simpson⁴ showed that HZ results from reanimation of the varicella-zoster virus (VZV) in sensory ganglia after a long intermission period following 1° infection from varicella (chickenpox). In some patients particularly in the elderly, the pain continues to persist after the rash heals and develops into postherpetic neuralgia (PHN), which is the most common difficulty. Postherpetic neuralgia causes physical disability, spiritual distress and intrusion with daily activities and sleep.⁵ HZ also causes neurological sequelae, HZ ophthalmicus (HZO) with eye participation or spread disease. Severe cases of these complications often need hospitalisation.

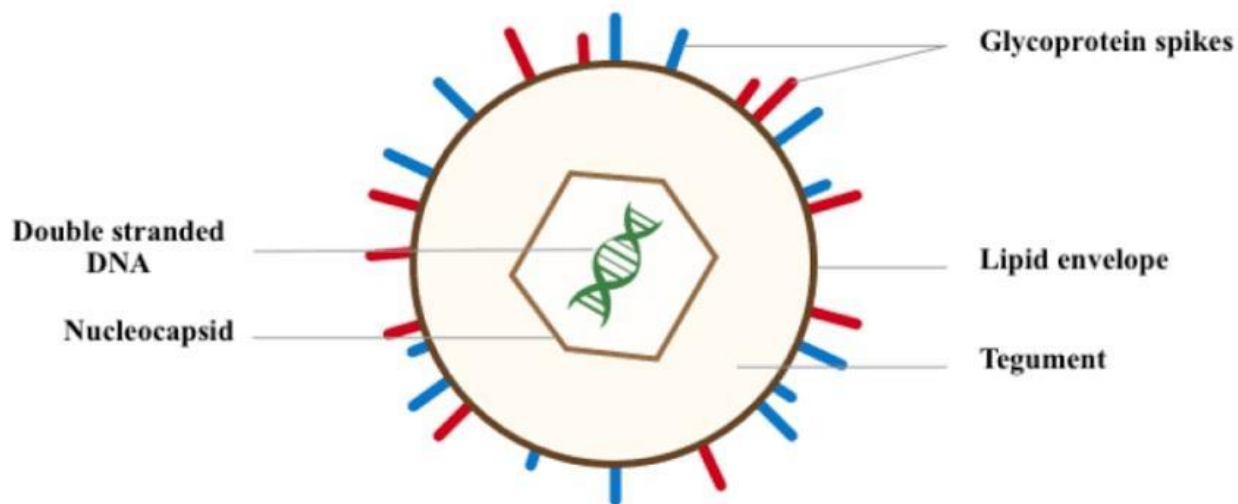


Figure 1: The beneficial effects of varicella zoster virus

ETIOLOGY AND PATHOLOGY:-

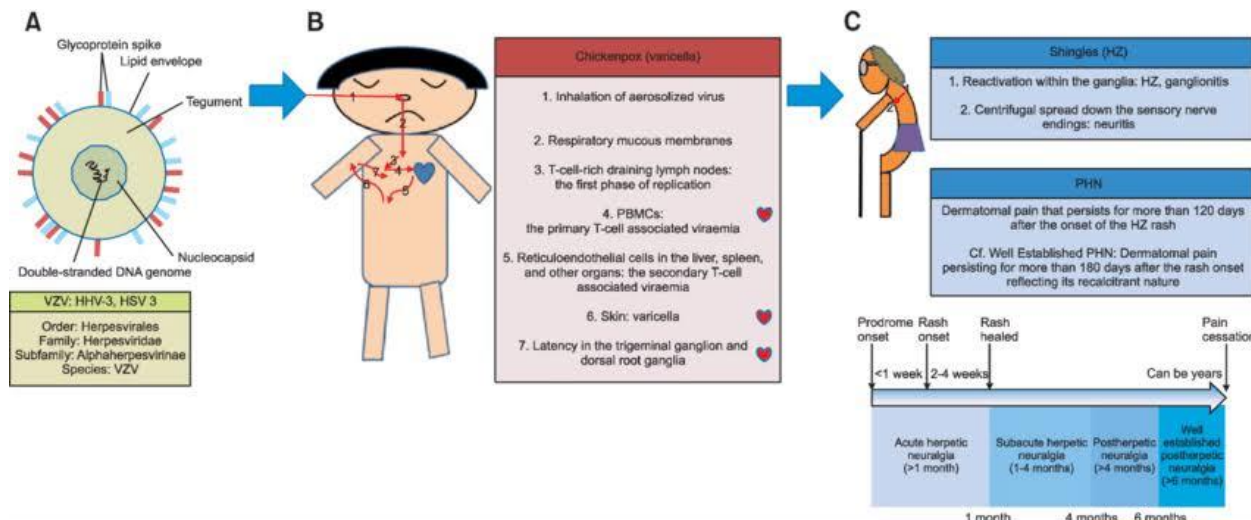


Figure 4: The pathogenesis of varicella, herpes, and zoster & potherapeutic neuralgia

Varicella zoster virus is one of 8 known herpes viruses that contaminate humans. Its structure is characterized by an icosahedral nucleocapsid surround by a lipid cover. Double-stranded DNA is track down at its centre. The virus has 150–200 nm in diameter and has a molecular weight of 80 Million (Mali, 2012)

During its viremic phase, cell-associated varicella zoster virus gains access to epidermal cells, causing the common varicella rash. The virus then enters the sensory nerves in mucocutaneous sites and travel by retrograde axonal transport to the sensory dorsal-root ganglia adjoining to the spinal cord, where the virus initiate permanent latency in neuronal cell bodies. Latent varicella zoster virus is present in 1–7% of sensory ganglion neurons, with max 10 genomic copies per infected cell. Propagating of the dorsal-root ganglia might also occur during viremia. The dimensions of viremia, the no of skin lesions, and the burden of VZV that accepted latency during 1° varicella infection might be link. As with other members of the herpes virus family, varicella zoster virus is noninfected in its latent form, but can renovate at a later time to form whole virions in the involved sensory neurons. These virions then relocate to the skin through axons, spread from cell to cell, and enter into the epidermis. In its full clinical expression, zoster causes pain, which is followed by a vesicular rash dispense across closely overlaying dermatomes of the participated sensory nerve roots. (Mali, 2012)

The Activate for the reactivation of VZV have not been identified and most likely involve multiple factors. However, specific components of cell-mediated immunity (CMI) play a main role in controlling the evaluation of zoster by preventing renewal within the neuron or the full clinical declaration of reactivated Varicella zoster virus as zoster. The efficacy f these protective components of CMI is well maintained in immunocompetent individuals during childhood and early adulthood. These CMI components are believed to be partially or significantly maintained by periodic immunologic boosting. ‘Endogenous boosting’ might happen in response to the subclinical reactivation of inactive VZV or to the evaluation of zoster itself, and ‘exogenous boosting’ might occur in response to exposure to VZV move round in the population as chickenpox. (Mali, 2012)

1° infection is clinically identified as varicella or chickenpox. Varicella zoster virus is ubiquitous and highly contagious, with initial exposure typically occurring during childhood. The virus enters the host through the respiratory system, replicates at an undefined site (presumably the nasopharynx), infiltrates the reticuloendothelial system, and finally makes its way into the bloodstream. Evidence of viremia is display by the disperse nature of the telltale skin lesions on the body. (Mali, 2012)

The usual prenatal time period for varicella is 14–16 days, with contagious ranging from 10 to 21 days after initial exhibition. An individual can no longer transmit Varicella zoster virus once the eventual skin lesions have crusted. Indirectly transmission is not believed to occur. (Mali, 2012)

Once the initial eruption has subsided, Varicella zoster virus then withdraw into the dorsal-root ganglia, where it can remain dormant for years until some excitatory factor triggers reactivation. The associated outbreak is then clinically identified as Herpes Zoster or shingles. Microscopic exam of select dorsal-root ganglia tissue during active Herpes zoster shows the existence of haemorrhage, oedema, and lymphocytic infiltration. Figure 1 shows the typical progress of VZV from varicella to zoster. (Kost & Straus, 1996) (Galluzzi, 2009)

EPIDEMIOLOGY

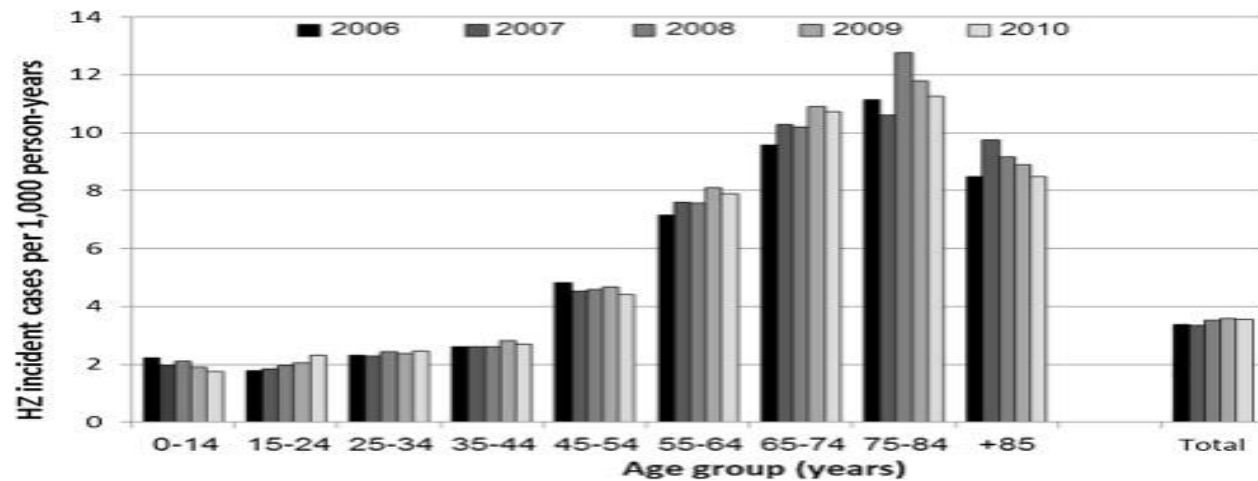


Figure 5: A population based study of the epidemiology of Herpes Zoster & its complications

RISK FACTORS:-

Anyone who has had natural infection with wild-type varicella zoster virus (VZV) or had varicella vaccination can grow herpes zoster. Children who get the varicella vaccine have a low risk of HZ compared with children who were infected with wild-type Varicella zoster virus. Many people do not recall having chickenpox; however, approx. 99.5% of people born before 1980 in the United States have been infected with wild-type Varicella zoster virus. As a result, almost aged adults in the United States are at risk for herpes zoster.

Approx. 1 out of 3 people in the US will experience herpes zoster during their lifetime. Most people have only one event of the illness in their lifetime, however, multiple episodes are possible. A person's risk for herpes zoster, and complications, such as post herpetic neuralgia (PHN) and hospitalization, add sharply after 50 years of age.

The reasons why Varicella zoster virus reactivates and causes herpes zoster are not well understood. However, a person's risk for herpes zoster increases as their Varicella zoster virus-specific cell-mediated immunity declines. This reduction in immunity can result from increasing age as well as from medical conditions or medications that defeat a person's immune system.

People with the following conditions that deal or suppress their immune system have an increased risk for herpes zoster: HZ

Cancer, mainly leukemia & lymphoma,

Human immunodeficiency virus (HIV),

Bone marrow or solid organ (renal, cardiac, liver, and lung) transplant recipients,

Take immunosuppressive drug, including steroids, chemotherapy, or transplant-related

PATHOPHYSIOLOGY:-

Electron micrograph of Varicella zoster virus. Approximately 150,000× amplification. The virus diameter is 150-200 nm

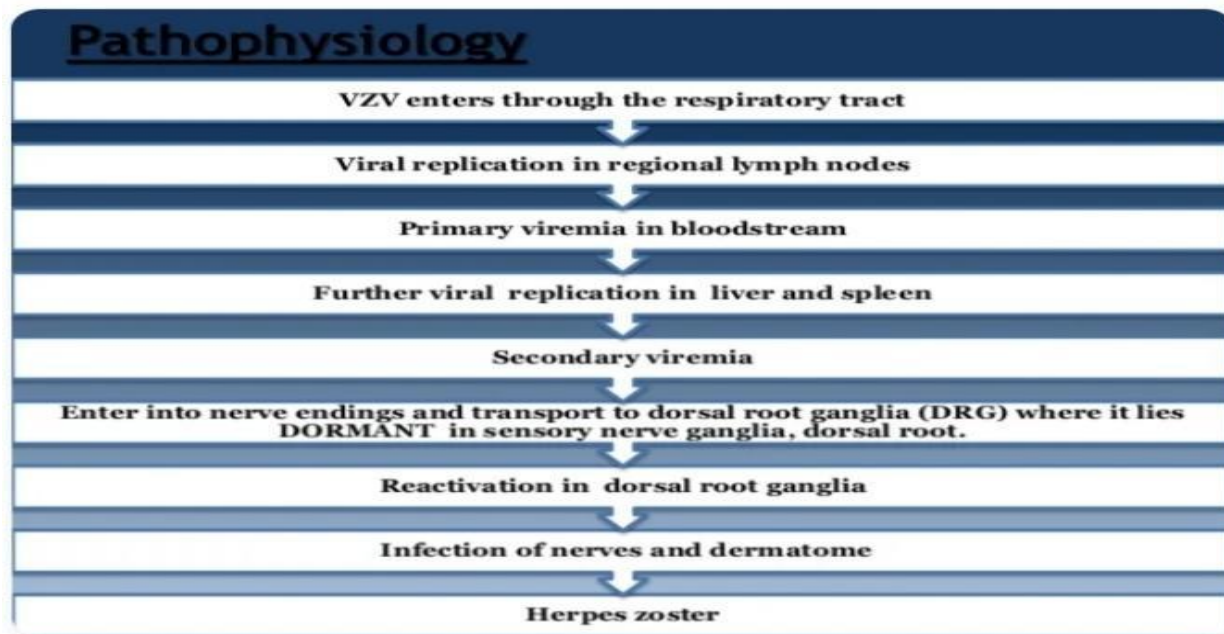
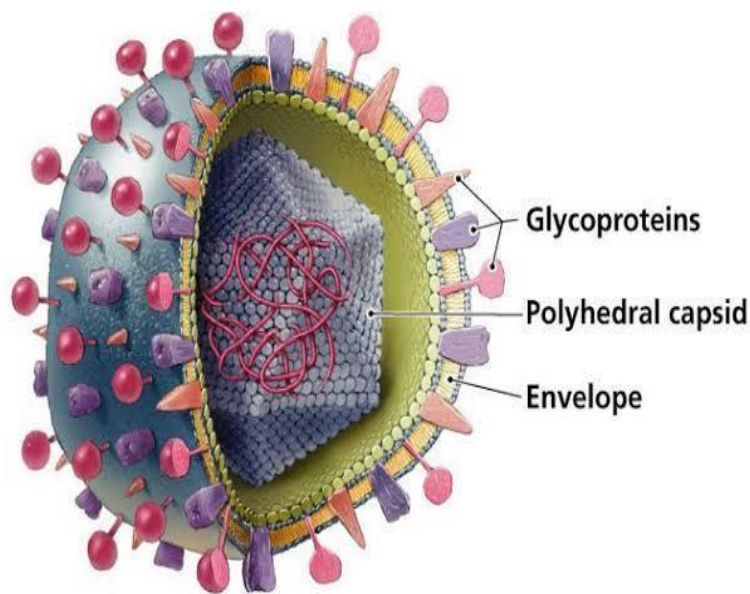
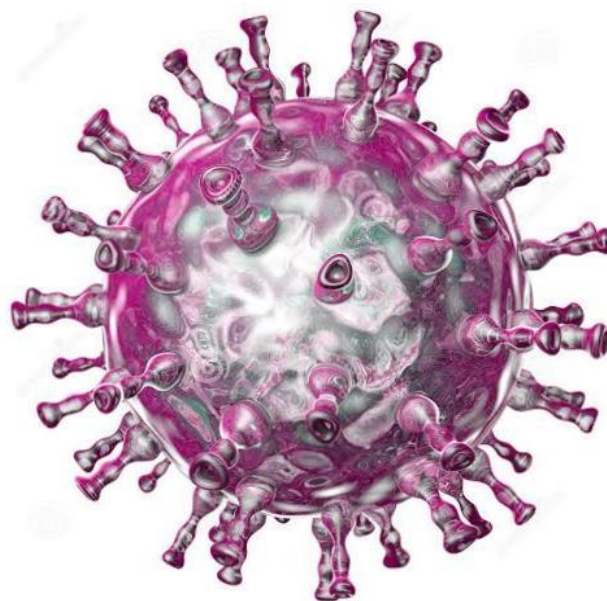


Figure 6: The Pathophysiology

Progression of herpes zoster. A cluster of small bumps (1) turns into vesicles (2). The blisters fill with lymph, break open (3), crust over (4), and finally disappeared. Postherpetic neuralgia can sometimes occur due to nerve injury

The causative agent for herpes zoster is the varicella zoster virus (VZV) – a double-stranded DNA virus correlated to the herpes simplex virus. Most of People are infected with this virus as children which causes an episode of chickenpox. The immune system finally eliminates the virus from most places, but it remains dormant (or latent) in the ganglia adjacent to the spinal cord (called the dorsal root ganglion) or the trigeminal ganglion in the base of the head.

HZ occurs only in people who have been previously infected with VZV; although it can occur at any age, approx. half of the cases in the U.S.-united state occur in those aged 50 years or older the repeated attacks of shingles are rare, and it is extremely rare for a person to have more than three recurrences.

MORPHOLOGY:-**Figure 7: Enveloped Virus with Polyhedral Capsid****Figure 8: varicella zoster or chickenpox virus**

Varicella zoster virus is closely related to the herpes simplex viruses (HSV), sharing much genome homology. The known envelope [Cover] (gB, gC, gE, gH, gI, gK, gL) correlate with those in HSV, however there is similar of HSV gD. Varicella zoster virus virions are round shaped and 150-200 nm diameter. Their lipid envelope encloses the nucleocapsid of 162 capsomeres set out in a hexagonal form. Its A is a single, linear, double-stranded molecule, 125,000 net length.

The virus is very susceptible to disinfectants, notably NaClO. Within the body it can be treat by a number of drugs and therapeutic agents including acyclovir, zoster-immune globulin (ZIG), and vidarabine.

TREATMENT:-**TABLE 1: SHINGLES - A COMPLETE GUIDE FOR CLINICIANS**

Drug	Dose	Frequency	Duration ^a
Acyclovir	800 mg	5 times/day	7–10 d
Famciclovir	500 mg	3 times/day	7–10 d
Famciclovir	750 mg	Once daily	7–10 d
Valacyclovir	1 g	3 times/day	7–10 d

^a Patients with disseminated herpes zoster or herpes zoster ophthalmicus may require intravenous treatment for a number of days followed by oral treatment.

EFFECTS OF TREATMENT IN THE SHORT-TERM**ANTIVIRAL MEDICATION:-**

Most of the placebo-controlled Root canal therapy of antiviral therapy were concise in a meta-analysis.¹⁰ A sub analyse (4 studies^{11–14} comprising 692 patients) showed that acyclovir (800 mg 5 times daily for 7–10 days) had no statistically significant effect on acute pain after 1 month (pooled odds ratio 0.83, 95% confidence interval [CI] 0.58 to 1.21). Because the numerous used measurement methods that could not be collate, no overall effect on the time of acute pain could be established. From the separate studies, however, it appeared that the effect of acyclovir on the duration of acute pain did reach statistical significance in a few occurrence. Pain relief was seen at most a few days before time. Another placebo-controlled RCT with acyclovir, published after this meta-analysis, also did not indicate a statistically significant effect on pain reduce after 1 month. (Opstelten, Eekhof, Neven, & Verheij, 2008)

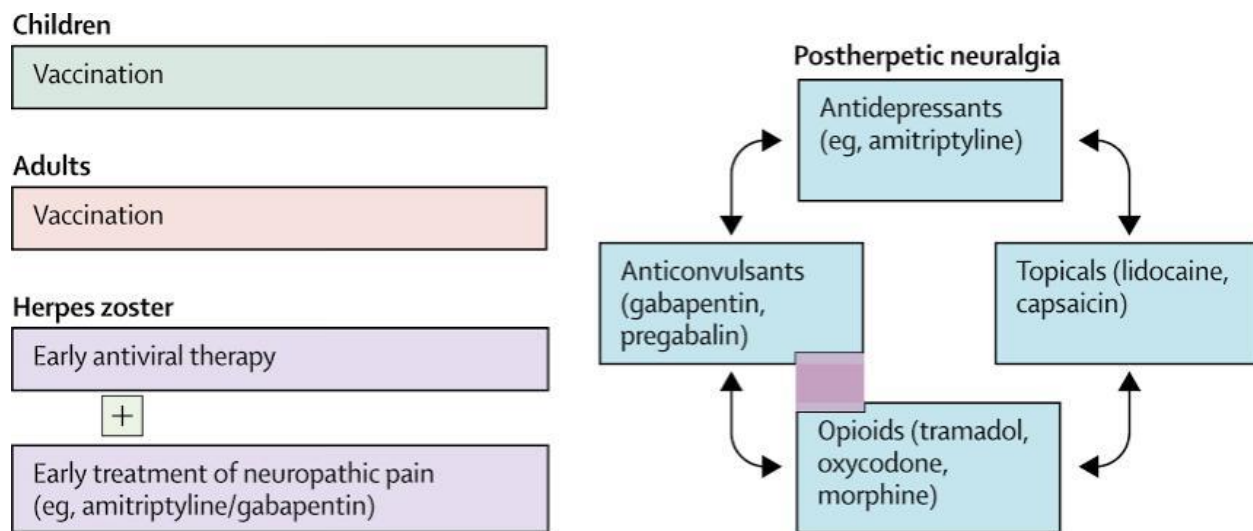
EFFECTS OF TREATMENT ON PREVENTION OF PHN

figure 9: prevention & treatment of posthepatic neuralgia

ANTIVIRAL MEDICATION:-

There is no convincing evidence that acyclovir effect the incidence or duration of PHN. 3 placebo-controlled RCTs on acyclovir (800 mg 5 times daily for 7 days¹³ and 10 days ^{11,14}) reported less pain in the treatment groups in the short-term duration (1–3 months), but no difference in long-term duration (more than 3 months). Another study compared valacyclovir with acyclovir.¹⁹ 3 groups were used: I I)valacyclovir 1000 mg 3 times a day for 7 days,ii) valacyclovir 1000 mg 3 times a day for 14 days, and iii)acyclovir 800 mg 5 times daily for 7 days. The median length of time for pain to vanish was 38 and 44 days in the groups treated with valacyclovir for 7 or 14 days, respectively, and 51 days in the group treated with acyclovir. There was no statistically significant difference among the various groups with respect to post herpetic neuralgia instance, although the postherpetic pain lasted longer among those in the acyclovir group than among those in the group treated with valacyclovir for 7 days (hazard ratio 1.3, 95% CI 1.0 to 1.6). Famciclovir also had no effect on post herpetic neuralgia incidence. However, a well-designed placebo-controlled RCT did show that the time of pain in those patients who developed PHN was notably shorter (63 days in the famciclovir group vs. 119 days in the placebo group; 63 vs 163 days around patients > 50 years).¹⁶ After 6 months, pain was described by 15% of the patients in this class treated with famciclovir differentiated with 23% of these in the placebo group. As stated by these data, 12 patients must be treated with famciclovir in order to gain 1 additional patient free of pain after 6 month.

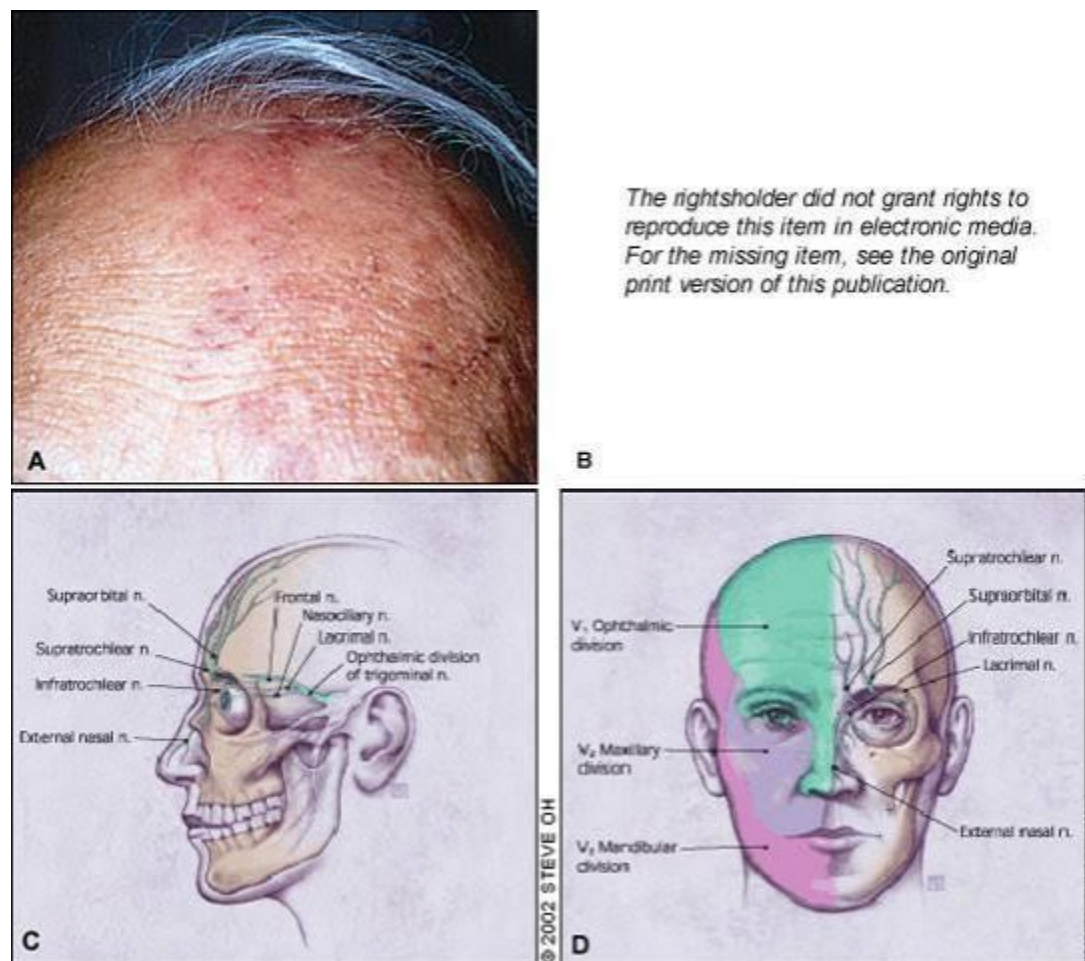
EFFECTS OF TREATMENT OF OPHTHALMIC HERPES ZOSTER:-

Figure 10: Evolution & Management of herpes zoster ophthalmicus

ORAL ANTIVIRAL MEDICATION:-

Ophthalmic HZ is a certainly serious disease that can result in acute and lasting pain, particularly among elderly patients. Besides, without antiviral treatment, about half of all patients will grow various eye disorders. Conjunctivitis, for example, is seen in nearly all HZ patients with ocular participation. Acute disorders include keratitis, uveitis, and optic neuritis of the affected eye. If these latter disorders are not diagnosed and treated adequately, the patient's sight might be forever affected. Before time (within 72 hours after rash onset) treatment with acyclovir (800 mg 5 times a day for 7 days) reduces the % of eye disorders in ophthalmic Herpes Zoster patients from 50% to between 20% and 30% (e.g., 25% of the patients in the acyclovir group developed stromal keratitis vs 56% in the control group; $P = .008$).²⁵ Valacyclovir (1000 mg 3 times daily) and famciclovir (500 mg 3 times daily) seem to be as efficient as acyclovir in reducing Herpes zoster-associated pain,^{26,27} but their effectiveness in reducing eye disorders associated with HZ has not been studied. In clinical practice, however, these 2nd generation antiviral agents might be more efficient than acyclovir because patients are more likely to comply with the treatment regimen (3 rather than 5 daily doses). The effectiveness of antiviral medication initiated more than 72 hours after the onset of skin rash has never been confirmed.

DIFFERENTIAL DIAGNOSIS:-

1. Cellulitis
2. Chickenpox
3. Cnidaria envenomation
4. Contact stomatitis
5. Dermatological manifestation of herpes Simplex
6. Ecthyma
7. Erysipelas
8. Folliculitis
9. Insect bites (Nair & Patel, 2021)

Table 2: Summary

Sr. No.	Specially	Dermatology
1	Symptoms	Painful Rash Occurring in a stripe
2	Complication	Post herpetic neuralgia
3	Duration	2-4 weeks
4	Causes	Varicella zoster virus
5	Risk Factor	Old age, Poor immune function, having chickenpox before 18 month of age
6	Diagnostic method	Based on symptoms
7	Prevention	Shingles Vaccine
8	Medication	Acyclovir, pain medication
9	Death	6,400 (With Chicken-pox)

CONCLUSION:-

Oral antiviral drugs should be authorised to elderly Herpes Zoster patients with high risk of PHN. Moreover, these drugs should be prescribed to all patients at the first signs of ophthalmic Herpes Zoster, irrespective of age or acuteness of symptoms.

Herpes zoster (HZ), also known as shingles, is the secondary manifestation of an earlier contamination with the VZV in one or more dermatomes. The reported incidence varies from 2.2 to 3.4 per 1000 people per year.¹⁻³ as reactivation of the virus is linked to an age-related diminished virus-specific and cell-mediated immunity, HZ develops mainly in elderly people. Immunocompromised patients are also at increased risk of growing Herpes Zoster. As it has not yet been demonstrate that HZ is provoked by any serious underlying pathologic condition (e.g., malignancy),⁴ a search for viable risk factors is not warranted in otherwise healthy patients in whom HZ develops.

The main difficulty of HZ include post herpetic neuralgia (PHN) and ophthalmic problems, the latter in occurrence of ophthalmic Herpes Zoster. Post herpetic neuralgia is usually defined as pain in the involved dermatome that is still present 1 month after rash onset.^{5, 6} Sometimes, however, a time of 3 months is apply.^{7, 8} A large prospective study identified 4 independent predictors of PHN: older age, severe acute pain, severe rash, and a shorter time of rash before discussion.⁹ Although PHN can disappear after a few months, it can also grow into a lasting determine pain syndrome.

A recent double-blind placebo-controlled trial showed that vaccination of immunocompetent persons 60 years of age and older with experimental live attenuated zoster vaccine markedly decreased HZ morbidity and PHN incidence.⁸

The aim of this article is to review the proof regarding treatment of immunocompetent Herpes zoster patients, focusing on short-term as well as on long-term (prevention of PHN) effects.

ABBREVIATION:-

HZ- Herpes Zoster

PHN- Postherapeutic neuralgia

TCA-Tricyclic Antidepressants

VZN-Varicella Zoster Virus

•REFERENCES :-

1. Davies L, Cossins L, Bowsher D, Drummond M. The cost for treatment of post-herpetic neuralgia in the UK. *Pharmacoeconomics* 1994; 6:142-8. [PubMed] [Google Scholar]
- 2.-Simpson RE. The nature of herpes zoster: a long term study and a new hypothesis *Proc R Soc Med* 1965;58:9-20. [PMC free article] [PubMed] [Google Scholar]
3. Mahalingam R, Wellish M, Wolf W, Dueland AN, Cohrs R, Vafai A, et al. Latent varicella zoster viral DNA in human trigeminal and thoracic ganglia. *N Engl J Med* 1990;323:627-31. [PubMed] [Google Scholar]
4. Berry JD, Petersen KL. A single dose of gabapentin reduces acute pain and allodynia in patients with herpes zoster. *Neurology* 2005;65:444-7.
5. Roxas M. Herpes zoster and postherpetic neuralgia: diagnosis and therapeutic considerations. *Altern Med Rev.* 2006;11:102–113
<https://journals.lww.com>
- 6.Tidwell E, Hutson B, Burkhardt N, Gutmann JL, Ellis CD. Herpes zoster of the trigeminal nerve third branch: a case report and review of the literature. *Int Endod J.* 1999;32:61–66
- 7.kost RG, Straus SE. Postherpetic neuralgia – pathogenesis, treatment, and prevention. *N Engl J Med.* 1996;335:32–42
8. Johnson RW, Bouhassira D, Kassianos G, Leplège A, Schmader KE, Weinke T. The impact of herpes zoster and post-herpetic neuralgia on quality-of-life. *BMC Med.* 2010;8:37–49
9. Kanazi GE, Johnson RW, Dworkin RH. Treatment of postherpetic neuralgia: an update. *Drugs.* 2000;59:1113–1126. [PubMed]
- 10.Bowsher D. Postherpetic neuralgia and its treatment: a retrospective survey of 191 patients. *J Pain Symptom Manage.* 1996;12:290–299. [PubMed]
- 11.Baba M, Shigeta S. Antiviral activity of glycyrrhizin against varicella-zoster virus in vitro. *Antiviral Res.* 1987;7:99–107
- 12.Arvin A: Aging, immunity, and the varicella-zoster virus. *N Engl J Med* 2005;352:2266–2267.

13. Johnson RW: Patient awareness of herpes zoster: the Global Herpes Zoster Survey – a preliminary report. *Herpes* 2006;13(suppl 1):40A–41A.

14. Davis AR, Sheppard J. Herpes Zoster Ophthalmicus Review and Prevention. *Eye Contact Lens*. 2019 Sep;45(5):286-291.

15. Heineman TC, Cunningham A, Levin M. Understanding the immunology of Shingrix, a recombinant glycoprotein E adjuvanted herpes zoster vaccine. *Curr Opin Immunol*. 2019 Aug;59:42-48. [PubMed]<https://www.ncbi.nlm.nih.gov>

16. Watanabe D. [Cutaneous Herpesvirus Infection]. *Brain Nerve*. 2019 Apr;71(4):302-308.

17. Van Wijck AJ, Opstelten W, Moons KG, van Essen GA, Stolker RJ, Kalkman CJ, et al. The PINE study of epidural steroids and local anaesthetics to prevent postherpetic neuralgia: a randomised controlled trial. *Lancet*. 2006;367(9506):219–24. [PubMed] [Google Scholar]

18. Alper BS, Lewis PR. Does treatment of acute herpes zoster prevent or shorten postherpetic neuralgia? *J Fam Pract*. 2000;49(3):255–64. [PubMed]

