



# Arterial and Venous Revascularization in Erectile Dysfunction

Anggind Grandika Andromeda

Sukosari Public Health Center, Bondowoso, East Java, 68287, Indonesia

**Abstract:** Erectile dysfunction is one of the most common sexual disorders in men. Penile revascularization surgery is one of the promising procedures that has the ability to cure patients permanently, allowing for the return of spontaneously generating erections without the use of drugs or external/internal devices. This method has undergone numerous revisions since its first description in the 1970s. The surgery's specific goal is to enhance blood flow into the erection (cavernosal) artery in patients who have blood flow-related ED as a result of trauma. Young men with erectile dysfunction owing to pure arterial blockage and no other vascular risk factors (diabetes, high blood pressure, lipid disorders, cigarette smoking) represent the optimum patient population for penile revascularization surgery.

**Index Terms:** erectile dysfunction, revascularization, revascularization surgery, sexual disorders

## Introduction

Erectile dysfunction is one of the most common sexual disorders in men and occurs in 1 out of every 5 men over the age of 40. Erectile dysfunction is defined as "persistent inability to obtain and maintain an erection adequate to achieve satisfactory sexual performance". It is estimated that 152 million men worldwide have erectile dysfunction, and it is predicted to reach 322 million by 2025. Some studies suggest endovascular intervention can play an important role in the management of erectile dysfunction for ~40% of PAD patients with arterial lesions who may undergo angioplasty with or without stenting.<sup>1</sup>

The causes of erectile dysfunction are usually multifactorial, namely arteriogenic, venogenic, endocrinological, neurogenic, drug-induced, and/or psychogenic. The prevalence of arteriogenic erectile dysfunction depends on age. According to observations of pelvic CT angiography (CTA) and another invasive angiography, the prevalence of obstructive lesions (stenosis diameter 50%) of the iliac-pudendal-penile artery system is more than 70% in men with erectile dysfunction aged 50 years. Of these obstructive lesions, 60% were located in the distal common penile and internal pudendal arteries. About 30% of the penile arteries have their blood supply from both the accessory and internal pudendal arteries.<sup>2</sup> In this review article, we aimed to review the updated the erectile dysfunction treatment using penile revascularization surgery.

## History and consideration of penile revascularization surgery

Penile revascularization (PR) surgery was first reported in 1972 by Michal et al. A decade later, Crespo et al reported a 76% subjective success rate after arterio-arterial anastomosis in 257 patients, and Virag reported 74.9% of patients exhibiting good outcomes after deep dorsal vein arterialization. Thereafter, criteria and surgical indications were established in the late 1990s. Penile blood flow depends on the internal pudendal artery, which is a branch of the internal iliac artery. The internal pudendal artery runs within the pudendal canal and is at risk of injury, especially if there is a fracture of the inferior pubic ramus. Other arterial diseases that reduce blood flow to the penis, both impaired flow, and pressure, can cause erectile dysfunction.<sup>3</sup>

Erection is a complex physiological process with vascular factors playing an important role. Treatment options for men with arteriogenic erectile dysfunction are mainly phosphodiesterase 5 inhibitors, injection of intercavernous vasoactive agents (such as prostaglandin E1, papaverine/phentolamine, or triple drugs), intraurethral prostaglandin E1 administration, and centrally acting drugs. However, all of the above methods are only temporary treatments, and patients are not completely cured of impotence, as they become dependent on these drugs.<sup>3</sup>

Penile revascularization is the treatment of choice for patients with erectile dysfunction. The initial results of revascularization surgery appear promising, so this method is increasingly being used. Most vascular reconstructions use the inferior epigastric artery (AEI). Penile revascularization surgical techniques are divided into 3 groups, namely venous arterialization, arteriovenous shunting, and arterio-arterial shunting.<sup>3</sup>

The diameter of the iliac-pudendal-penile artery system varies from 10 mm for the common iliac artery to 1.0 mm for the cavernous artery. Due to advances in technology, all blood vessels are now accessible for endovascular revascularization, and a contrasting pattern of restenosis was found based on pelvic CTA findings taken 8 months after angioplasty. For lesions in the segment from the common iliac artery to the proximal pudendal artery (above the pelvic floor), the incidence of restenosis is <4%, whereas, for lesions in the segment from the internal pudendal artery distal to the cavernous artery, the restenosis rate is up to 40%, regardless of which conventional angioplasty strategy is used. applied. Thus, restenosis remains a challenge in the long-term success of angioplasty for obstructive lesions of the distal penile and internal pudendal arteries.<sup>3</sup>

### **Examination before penile revascularization surgery**

As with other aspects of surgery, patient selection is key to optimizing clinical outcomes. As stated by the Guideline Panel, the ideal patient for microvascular arterial penile bypass revascularization is a young male with a history of focal endothelial dysfunction in the absence of systemic endothelial dysfunction.

In San Diego, all men underwent a thorough biopsychosocial evaluation. Hormone testing is performed to exclude testosterone and/or dihydrotestosterone deficiency, thyroid disorders, hyper- or hypoestrogenic, or prolactinoma. Physical examination includes a qualitative sensory examination by measuring the perception of vibration, heat, and cold to assess the integrity of the dorsal sensory nerve branches of the pudendal nerve which are susceptible to injury due to blunt pelvic and perineal trauma. Doppler duplex ultrasound examination was also performed during pharmacological erection with maximal smooth muscle relaxation. If veno-occlusive dysfunction is found, an end-diastolic velocity >5 cm/s excludes the patient from a candidate for microvascular arterial bypass penile revascularization. When arteriogenic erectile dysfunction is suspected, dynamic cavernosometry is performed to measure the right and left cavernous artery systolic occlusion pressures and compare the results with the brachial artery systolic occlusion pressures measured together. A pressure gradient >30 mmHg is considered abnormal. The final assessment is a selective internal pudendal arteriogram during pharmacological erection. The assessment provides information on the obstructive lesion, the integrity of the donor's inferior epigastric artery, the integrity of the recipient's cavernous artery, and the presence of arterial communication from the recipient's dorsal artery to the cavernous artery.<sup>4</sup>

### **Surgical procedure of penile revascularization surgery**

The goal of surgery is to bypass the obstructed distal/common penile internal pudendal artery/proximal cavernous artery and increase systolic perfusion pressure and blood flow from the donor's inferior epigastric artery to the recipient's dorsal penile artery. Ideally, the increased dorsal artery systolic perfusion pressure and blood flow will communicate with the cavernous artery via the branch between the dorsal penile artery and the cavernous artery. The technique is carried out starting from positioning the patient supine. Ensure proper padding and positioning of the cuff to minimize iatrogenic injury to the ulnar nerve at the elbow, characterized by paresthesia of the 5th finger and half of the 4th finger. A sequential compression device is attached to each calf to minimize postoperative venous thromboembolic disorders. Preoperative antibiotics are given within 1 hour of the skin incision (cefazolin, or vancomycin). The film arteriogram was reviewed before the skin incision to confirm the integrity of the donor's inferior epigastric artery as well as the recipient's most suitable dorsal penile artery. Surgery can be divided into 3 parts namely dorsal artery dissection, obtaining inferior epigastric, and microvascular anastomosis.<sup>4</sup>

The Foley 14-French catheter is placed after the patient is prepared. A 3 cm curvilinear penoscrotal incision was made opposite the abdominal incision to obtain the donor epigastric artery. With the finger-sweep technique, Dartos and Bucks fascia is achieved to expose the corpus spongiosum and tunica albuginea. The penis is then diverted through this incision and fixed in place with a Scott or Lone-Star ring retractor to expose the dorsal neurovascular bundle. This is done to maintain the fundiform ligament and maintain the length of the postoperative penile erection. The neurovascular bundle is dissected proximally below the fundiform ligament. Papaverine hydrochloride irrigation is used to minimize vasospasm and endothelial injury.<sup>3</sup>

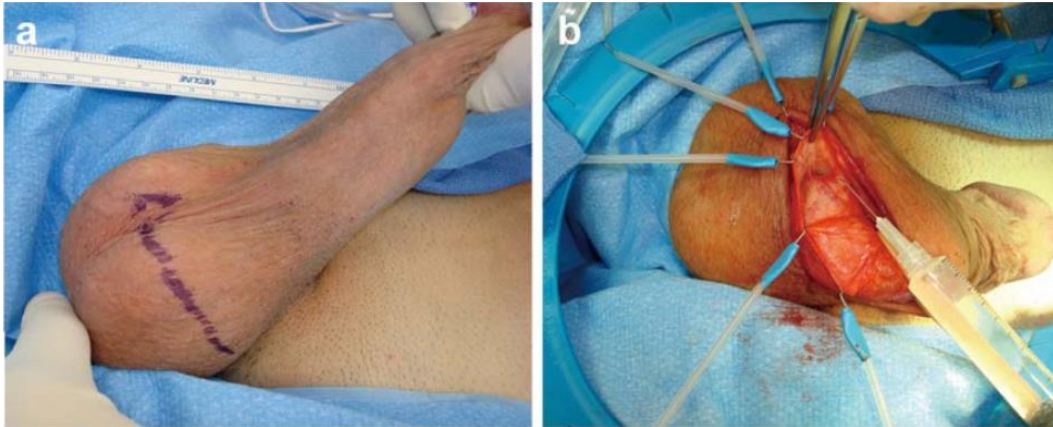


Figure 1. Microvascular arterial bypass penile revascularization surgery. (a) Oblique, inguinal scrotal incision on side of scrotum opposite of donor inferior epigastric harvest. (b) Preservation of fundiform ligament with Scott retractor hooks provides excellent exposure of dorsal neurovascular bundle. Careful initial dissection of recipient dorsal penile artery is fashioned<sup>2</sup>

The skin is marked by the Langer's line from the distance from the pubis to the umbilicus. A 5-cm semilunar incision was made to the anterior rectus fascia. The fascia end was clamped with Kocher clamps and the rectus muscle was shifted medially to identify 1 artery and 2 veins below the muscle surface in the pre-peritoneal. Inferior epigastric bundle dissection was performed cranial to the umbilicus and caudal to near the origin of the femoral artery. Bipolar cautery with a microvascular tip is used to cauterize arterial branches from the inferior epigastric to the rectus muscle and pelvic periphery. The cranial aspect is clamped and divided. The inferior epigastric bundle is very pulsatile with a length of about 16 cm. The ligament clips at the ends of the bundles are clamped with forceps and directed downward into the penile field by passing through the internal ring through the inguinal canal out into the external ring, and under the fundiform ligament to the base of the penis. This stage is important to prevent twisting or bending of blood vessels that can interfere with blood flow.<sup>3</sup>

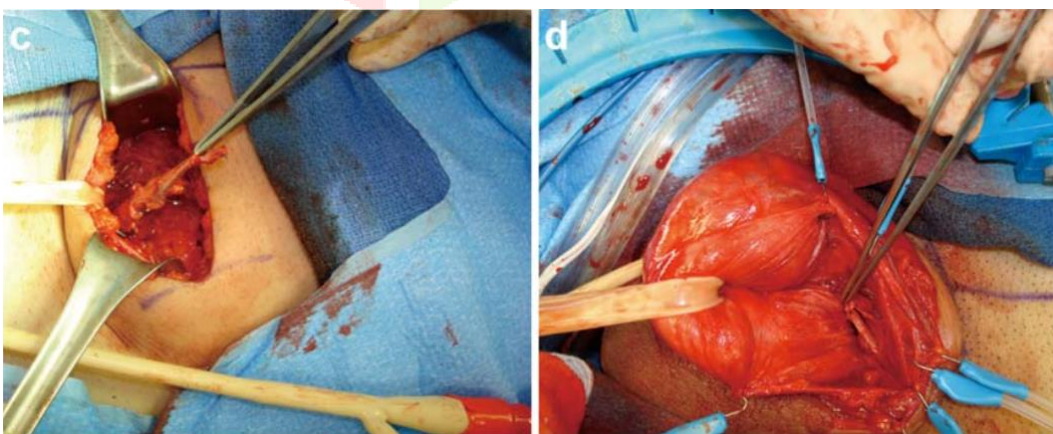


Figure 2. (c) Transverse abdominal incision is fashioned to harvest the donor inferior epigastric artery. The donor inferior epigastric artery has been transected around the level of the umbilicus and is ready for transfer to the base of the penis. (d) The donor inferior epigastric artery has been transferred through the internal ring, through the inguinal canal and out the external ring underneath the fundiform ligament to lie at the base of the penis at the dorsal neurovascular bundle.<sup>2</sup>

Microvascular artery anastomosis between the donor's inferior epigastric artery and the recipient's dorsal penile artery and artery with 10-0 nylon sutures was performed. Then a compressive dressing is applied to the scrotum. The Qn-Q catheter was placed for pain control and placed above and below the rectus muscle for up to 3 days postoperatively. The Foley catheter was inserted and removed the following morning.<sup>3</sup>

### **Elastic recoil**

In December 2018, Diehm et al reported the incidence of elastic recoil, a contributing factor to restenosis, immediately after dilatation of 31 lesions in the distal internal penile and pudendal arteries of 21 patients (mean age 58 years) with arteriogenic erectile dysfunction diagnosed with decreased velocity peak systolic (<30 cm/s) on penile duplex ultrasonography after intracavernous injection of prostaglandins. Recoil is a >10% decrease in lumen diameter 10 min after balloon angioplasty, which is treated with a drug-coated balloon or drug-eluting stent according to the severity of recoil (>10% or >30%, respectively).<sup>5</sup>

It was found that severe elastic recoil (>30%) occurred in up to half of the lesions. A satisfying clinical response after 3-months assessed by questionnaire was successful for the majority of patients; however, scores were worse in patients receiving drug-coated balloons than in drug-eluting stents. Severe elastic recoil occurred mainly in lesions of the internal pudendal artery, although the mean vessel diameter was larger (2.6 mm) than the penile artery (2.0 mm). The mean lesion length was significantly longer in the internal pudendal artery (23 mm) than the penile artery (4 mm), suggesting that the severity of elastic recoil may be related to lesion length and plaque load, but this was not investigated further. The authors reaffirmed the safety and feasibility of angioplasty on the internal pudendal artery, especially the penile artery in patients with arteriogenic erectile dysfunction. Given the ~50% incidence of severe elastic recoil lesions in lesions with a length of 23 mm, adequate mechanical scaffolding with stents is important to maintain patency after angioplasty. Despite satisfactory results on immediate angiography, i.e. residual stenosis of 30% and adequate distal flow, a 30-40% incidence of restenosis is consistently found after penile and internal pudendal artery angioplasty.<sup>5</sup>

There are several limitations of the study by Diehm et al. First, the absence of a control group. Second, view of diffuse stenotic lesions of the iliac-pudendal-penile artery system including the accessory pudendal arteries, comprehensive evaluation of the entire pelvic arterial system, and complete revascularization of all obstructive lesions are essential to obtain an adequate clinical response in terms of erectile function. However, the information is not displayed. Third, in addition to the minimum lumen diameter (MLD) obtained 10 minutes after angioplasty to determine the degree of elastic recoil, the final MLD measurement after angioplasty with drug-coated balloons and drug-eluting stents should also be carried out. Without this information, it cannot be determined whether additional angioplasty produces a different outcome. Fourth, looking at the reference mean internal pudendal artery diameter of 2.6 mm, it is interesting how the mean MLD immediately after angioplasty is only 2.0 mm. whereas, the mean MLD after penile artery angioplasty was the same as the reference diameter. Finally, without final MLD angiographic information and follow-up results from invasive pelvic angiography, pelvic CTA, or penile duplex ultrasonography, the long-term efficacy of angioplasty cannot be assessed in detail. Overall Diehm et al concluded that there is promising evidence regarding the safety and feasibility of endovascular revascularization in this obstructive arterial disease. Penile duplex ultrasonography should be performed extensively in patients at high risk of arteriogenic erectile dysfunction, i.e., those who are 50 years of age, have multiple cardiovascular risk factors, or who gradually become unresponsive to phosphodiesterase-5 inhibitors.<sup>6</sup>

### **Success rate of penile revascularization therapy**

Wang et al demonstrated clinically significant improvement in erectile function in 60% of the isolated penile artery stenosis cohort.<sup>7</sup> Identification of flow-blocking lesions relevant to erectile dysfunction and treatment with endovascular stenting showed significant improvement in erectile function. The meta-analysis by Doppalapudi et al reported a clinical success of 63.2% of angioplasties with or without stenting. The most common target vessel was the internal pudendal artery (42.7%) but the iliac and penile arteries could also be used.<sup>8</sup>

Urethral trauma is an important cause of erectile dysfunction in pelvic fracture patients and urethroplasty is usually required. Penile revascularization is one of the most common methods of treating erectile dysfunction in such patients. Several previous studies such as Zuckerman et al have reported 17 patients who underwent penile revascularization and showed a success

of 82%, and in the failed cases, a second surgery was successful. Another study conducted on 125 patients with renal artery bypass graft surgery by Kayigil et al. stated that the success of therapy was 81.8% and 6.6% of patients experienced side effects. Kawanishi et al showed that penile revascularization in 51 patients had an 85.9% success rate and a total of 4 patients experienced side effects. A review by Babaei et al reported that penile revascularization surgery is an effective therapeutic approach, and patients under 30 years of age and non-smokers are the most important factors determining surgical success. A recent study by Sepas et al regarding improvement of erectile dysfunction due to revascularization after urethroplasty in patients with pelvic fractures was a case series of 52 patients. All patients had a normal erection before pelvic fracture and were impotence at least 1 year after pelvic fracture, and all underwent urethroplasty. There were no atherosclerotic risk factors found in all patients, and only 1 patient had a smoking habit. The results of the study showed a success rate of the first surgery of 52%. This is in line with several previous studies. A study of 51 patients in Japan with participants with arteriogenic erectile dysfunction due to local arterial lesions showed successful therapy in 85.9% of patients and a total of 4 patients had complications, in the study of Sepas et al. 2 patients had complications, but this lower effectiveness may be explained by differences in causes. impotence, in which subjects in the Japanese study had small lesions of the penile vasculature, compared with total obliteration and prolonged thrombosis in pelvic fracture patients.<sup>3</sup>

Diehm et al also conducted a study of 50 patients undergoing endovascular revascularization due to erectile dysfunction with >50% stenosis and reported a 1-year outcome with the International Index of Erectile Function (IIEF-6) questionnaire containing 6 questions. At 12 months, 30 (65%) of 46 patients achieved the minimum clinically relevant improvement in the IIEF-6 score. In this registry, revascularization was achieved in high lesions and resulted in a success rate, with improvement in erectile function occurring in more than two-thirds of patients, similar to the previously reported efficacy of sildenafil. Thus, endovascular revascularization can be considered as a therapy for atherosclerotic erectile dysfunction and is safe. The functional outcome was worse in patients with hypertension. The success obtained is in line with the previous technical success data (91-100%). Similarly, improvements in erectile function were comparable to the ZEN study using DES for pudendal artery lesions and the PERFECT registry. In this study, IIEF improvement decreased after 3 months but remained significantly high at 1 year.<sup>6,9</sup>

Although the cause of erectile dysfunction is thought to be an atherosclerotic process, multiple etiologies and other comorbidities may contribute. Age, hypertension, smoking, prostate disease, hypogonadism, and/or distal lesions have an impact on clinical success. It may result from severe endothelial dysfunction, atherosclerosis, peripheral neuropathy, or nerve damage. In addition, antihypertensive drugs such as beta-blockers, thiazide diuretics, aldosterone antagonists, may affect results. The majority of included patients did not respond well to PDE5i and/or intracavernous prostaglandins, suggesting arterial obstruction. Therefore, revascularization includes restoration of erectile function without medication as well as the efficacy of drugs. Recovery by revascularization alone under complex conditions is not always complete, requiring lifestyle modification, reduction of cardiovascular risk factors, and continued medication.

The pelvic vascularization is similar to that of the coronary arteries in terms of angiographic characteristics such as reference diameter and lesion length. However, the rate of restenosis is reported to be higher. Roger et al found a 6-month restenosis rate of 34% in the pudendal arteries with the same type of DES, whereas in the coronary arteries it was only 9%. It is still unknown why, despite the use of modern DES, the rate of restenosis after pudendal or penile angioplasty remains higher than that of angiographic angioplasty. Overall endovascular therapy was safe and effective at a 12-month examination, with predictors of poorer functional outcome including old age, hypertension, distal lesion location; so, it needs to be considered in patient selection.<sup>7</sup>

### **Possible complications of penile revascularization therapy**

Complications that can occur are traumatic disruption of the anastomosis may occur in the first few weeks after surgery. Patients were instructed not to engage in any sexual activity for 6 weeks postoperatively. Other possible complications are decreased penile sensation due to dorsal nerve injury, penile pain, and reduced penile length, although these risks can be prevented by retaining the fundiform ligament. The use of a low dose of PDE5-I at night during the 6-month postoperative period can help improve self-confidence and promote recovery. For optimal results, it is important to restore the patient's psychology during the process. About 2/3 of patients notice a significant improvement in erectile function. In one series, the IIEF score increased from 35.5 to 56.2 and the erectile function domain increased from 14.8 to 23.8 after surgery. A total of 73% of patients with a score of 21 or more in the domain of the erectile function and 89% reported subjective improvement in their sexual function after surgery. The second

revascularization was performed in 10 patients out of 1500, with a success rate of around 60% for the second procedure, not much different from the first procedure.<sup>3</sup>

### Comorbidities and surgical outcomes

Kayigil et al reported the long-term surgical outcome (mean duration of follow-up 73.2 months) of 110 patients with erectile dysfunction with various causes. Serial comparison of revascularization is difficult because of the different pre-and postoperative evaluation techniques and the use of different surgical techniques. The main difference is the use of the CC-EMG method in the preoperative evaluation protocol. CC is composed of smooth muscle cells, interstitial matrix, blood vessels, vascular lamina, and various autonomic nerves. Relaxation of the trabecular smooth muscle allows expansion of the lacunar space and compression of the subtunical venules by retaining blood in the corpora during erection. Therefore, cavernous smooth muscle tone has an important role in modulating erectile capacity. Although young patients with erectile dysfunction and arterial cavernous insufficiency due to trauma-induced arterial occlusive disease are considered ideal candidates for microvascular bypass surgery, the effectiveness of deep dorsal vein arterialization in pure cavernous-occlusive dysfunction (with normal CC-EMG) was also found. In this study, the highest success rate was found in arteriogenic insufficiency (77.7%), followed by cavernous-occlusive dysfunction patients (72.1%) and patients with both (arterial and cavernous-occlusive disorders). The long-term success of revascularization according to Kayigil et al is influenced by diabetes, nicotine abuse, alcoholism, obesity, hyperlipidemia, coronary heart disease, and hypertension. In a study by Manning et al, men with two or more risk factors, including >50 years of age at the time of surgery, reported lower success rates. The study also found that patients with diabetes (43%) and the elderly (39%) had lower success rates than those with risk factors <2 (58%) and age <50 years (69%).<sup>8</sup> In a recent study, the success rate was highest in patients without risk factors (up to 92.8%). The success rates by timeline were, 81.8% at 3 months, 77.2% at year 1, 70% at year 2, 66.3% at year 3, and 63.6% at year 5 follow-up. In a study using the Hauri method of 124 patients with a mean follow-up duration of 54 months, 74 patients (59.7%) had spontaneous erections. Then the patients were classified into satisfied or dissatisfied groups. In the satisfied group, there was a high correlation between graft patency assessed by ultrasound and erectile function.<sup>10</sup>

### Successful penile revascularization surgery

Success was defined as achieving sexual satisfaction without additional therapy. Where patients <28 years showed success at 73% and 23% in patients aged > 28 years. Non-smokers had higher success (57%) than smokers (29%). The presence of venous leakage or the type of procedure did not show a significant effect on success. The exact mechanism by which penile revascularization improves erectile capacity has not been established. Oxygen tension in the corpus cavernosum may play an important role in the outcome of penile revascularization. Another possible reason is increased intracorporeal nitric oxide levels. In addition, improvement of intracavernous pressure with the retrograde arterial flow to the corpus cavernosal via the deep dorsal venous collateral network may promote arterial filling of the corpus cavernosal and reduce venous leakage. Cavernous tissue smooth muscle restoration after penile revascularization was demonstrated by increasing the amplitude and relaxation parameters on CC-EMG. Following the recommendations, arterialization of the deep dorsal vein is considered a third-line treatment if intracavernous injection fails.<sup>11</sup> Penile revascularization surgery is a promising alternative therapy for erectile dysfunction, especially after failed therapy with medications such as PDE5 inhibitors and intracavernous injection of vasoactive drugs.<sup>12,13</sup>

### Conclusion

Surgical techniques for revascularization can be summarized as an end-to-end anastomosis of the IEA to the dorsal artery in various modifications, an IEA anastomosis with the deep dorsal vein at the base of the penis with some modifications, a direct anastomosis to the corpus cavernosal or cavernous artery and a triple anastomosis between the dorsal penile veins. and the dorsal penile artery (side to side) with IEA (side end). Recent surgical developments may be performed laparoscopically and robotically assisted. It can be concluded that penile revascularization surgery is an important alternative therapy for erectile dysfunction, especially after failed therapy with medications.

### Conflicts of interest

No competing interests declared.

### Funding

This research received no specific grant from any funding agency.

### References

1. Benaragama KS, Singh AA, Taj T, et al. Erectile Dysfunction in Peripheral Vascular Disease: Endovascular Revascularization as a Potential Therapeutic Target. *Vasc Endovascular Surg* 2020; 54: 707–711.
2. Dicks B, Bastuba M, Goldstein I. Penile revascularization--contemporary update. *Asian J Androl* 2013; 15: 5–9.
3. Najd Sepas H, Tayyebi Azar A, Bashirian M, et al. Improvement of Erectile Dysfunction by Revascularization Surgery Following Urethroplasty in Patients with Pelvic Fracture. *Men's Heal J* 1970; 2: e10.
4. Babaei AR, Safarinejad MR, Kolahi AA. Penile revascularization for erectile dysfunction: a systematic review and meta-analysis of effectiveness and complications. *Urol J* 2009; 6: 1–7.
5. Munarriz R. Penile microvascular arterial bypass surgery: indications, outcomes, and complications. *ScientificWorldJournal* 2010; 10: 1556–1565.
6. Diehm N, Do D-D, Keo H-H, et al. Early Recoil After Balloon Angioplasty of Erection-Related Arteries in Patients With Arteriogenic Erectile Dysfunction. *J Endovasc Ther an Off J Int Soc Endovasc Spec* 2018; 25: 710–715.
7. Wang T-D, Lee W-J, Yang S-C, et al. Clinical and Imaging Outcomes up to 1 Year Following Balloon Angioplasty for Isolated Penile Artery Stenoses in Patients With Erectile Dysfunction: The PERFECT-2 Study. *J Endovasc Ther an Off J Int Soc Endovasc Spec* 2016; 23: 867–877.
8. Doppalapudi SK, Wajswol E, Shukla PA, et al. Endovascular Therapy for Vasculogenic Erectile Dysfunction: A Systematic Review and Meta-Analysis of Arterial and Venous Therapies. *J Vasc Interv Radiol* 2019; 30: 1251-1258.e2.
9. Diehm N, Marggi S, Ueki Y, et al. Endovascular Therapy for Erectile Dysfunction-Who Benefits Most? Insights From a Single-Center Experience. *J Endovasc Ther an Off J Int Soc Endovasc Spec* 2019; 26: 181–190.
10. Kayigil O, Okulu E, Aldemir M, et al. Penile revascularization in vasculogenic erectile dysfunction (ED): long-term follow-up. *BJU Int* 2012; 109: 109–115.
11. Kawanishi Y, Kimura K, Nakanishi R, et al. Penile revascularization surgery for arteriogenic erectile dysfunction: the long-term efficacy rate calculated by survival analysis. *BJU Int* 2004; 94: 361–368.
12. Metin A, Kayigil O. Electromyographic changes after deep dorsal vein arterialization. *Urol Int* 2005; 75: 67–69.
13. Raynor MC, Davis R, Hellstrom WJG. Robot-assisted vessel harvesting for penile revascularization. *J Sex Med* 2010; 7: 293–297.