



INTERNATIONAL JOURNAL OF CREATIVE RESEARCH THOUGHTS (IJCRT)

An International Open Access, Peer-reviewed, Refereed Journal

Review On Liposuction Surgery

Mr. Hemanshu S. Rathod^[1], Prof. Mukesh M. Nikhade^[2], Mr. Dhiraj N. Chavhan^[3],
Ms. Chanchal P. Kolhe^[4], Ms. Bhagyashali V. Pawar^[5] Mr. Abhishek R. Kale^[6]
Jagadamba Institute of Pharmacy & Research Kalamb, Maharashtra 445001, India

ABSTRACT :-

The most popular cosmetic surgical operation nowadays in Western countries is liposuction. Since A. and G. Fischer's initial experiments with it in the 1970s, this technology has advanced quickly. It is presently frequently utilized in therapeutic settings for a variety of circumstances in the realms of aesthetics, reconstruction, and functionality. Practitioners of medicine and surgery will likely come across these people in their work as liposuction is the second most popular surgical treatment performed on patients between the ages of 35 and 64 in the United States. The function of liposuction and fat transfer in cosmetic and reconstructive surgery is covered in this succinct review, along with important factors, indications, and safety issues. Nowadays, liposuction is frequently performed under tumescent anesthesia with high dosages of lidocaine. The current study's goal was to assess the plasma levels of lidocaine and both objective and subjective symptoms 20 hours after abdominal liposuction under tumescent anesthesia using 35 mg of lidocaine per kilogram of body weight. In these review it is also tried to cover thr measures over consequences or complication which ever documented after liposuction.

KEYWORDS:-

Liposuction, Surgical treatment, Reconstructive surgery, Tumescent anesthesia, Innovative methods.

1. HISTORY :-

Initial liposuction : When two Italian physicians named Arpad and Giorgio Fischer created a blunt tunnelling surgical procedure in 1974, liposuction was born. The operation was advanced by French doctors Yves-Gerard Illouz and Pierre Fournier in 1978 by changing procedures to lower sedation and morbidity risks. Again it was still a relatively new procedure subject to considerable bleeding and occasionally unattractive skin abnormalities was introduced by 1980^[1].

The normal cannula diameter in the early days was between 6mm and 10mm, with a cross-sectional area that was occasionally up to 25 times larger than those used now. Patients were routinely given general anesthesia. The blunt-tipped Illouz and Fournier cannulas decreased bleeding and harm to blood vessels and nerves, which prevented complications and cases of shock or death. Patients experienced reduced postoperative discomfort, and recovery durations were decreased^[1].

Through the 1980s, procedures became increasingly effective when surgeons injected more saline while combining it with local anesthetic lidocaine and the blood vessel-constricting medication epinephrine to lessen bleeding. This method was known as the "wet technique" since it involved using a lot of liquid^[1].

The "super-wet technique" was employed by surgeons to use more saline, epinephrine, and lidocaine fluid, which they hoped would minimize significant blood loss, lessen bruising, and lessen discomfort. The fat would grow and engorge, forcing it and the surrounding tissue to be removed. As liposuction became more and more popular, surgeons started combining several anesthetic strengths, including general anesthesia, epidural regional anesthesia, or strong IV sedation with little local anesthesia^[1].

Dr. Jeffrey Klein's development of the tumescent liposuction procedure in 1985 completely changed the field. Smaller cannulas and local anesthetic were used for the first time, greatly lowering the dangers of severe bleeding and irregular skin tone. Doctors were able to persuade their patients that there were little risks involved with using traditional liposuction techniques^[1].

1.1. The initial client :

Dr. Klein performed the first tumescent liposuction procedure on April 5, 1985. The lady had an excision scar and a localized deposit of fat on her lower abdomen. To remove little under 100ml of fat, Dr. Klein employed undiluted dosages of local anesthesia (500 mg of lidocaine and 1 mg of epinephrine in 50 ml). The epinephrine, which causes capillary vasoconstriction, or the constriction of blood vessels, was attributed with the patient reporting practically little discomfort during the procedure and no surgical bleeding. According to reports, administering the high dose of epinephrine did create a stinging sensation and a tachycardia, or quickening of the heartbeat^[1].

1.2. How tumescent liposuction has changed :

Dr. Klein raised the anesthetic solution's dilution levels for following patients as he improved the method. The degree of dilution permits a more even flow and greater amounts of anesthesia to be injected into the cannulas, which spread more broadly and have a greater impact on a bigger region of the body. The micro cannula eliminates less fat per minute than regular cannulas, but because of their tiny diameter, they may remove more fat overall and leave behind a much smoother, cleaner finish. He observed that the stinging sensation that patients had previously experienced and the tachycardia significantly decreased as dilution rose, despite there being no change in the anaesthetic concentration. Additionally, he saw that more subcutaneous fat was reached^[1].

By the end of 1985, Dr. Klein had mastered this method and identified the ideal anesthetic dosage: 500–1250 mg of lidocaine and 0.5–1.0 mg of epinephrine per litre of solution^[1].

Dermatologists were keen to carry out the procedure under local anesthetic. So they began combining local lidocaine injection with a mild preoperative sedation. The greatest amount of local anesthetic that was advised, nevertheless, only allowed for a few patients with modest treatment regions.

The use of huge doses of extremely dilute anesthetic, which allowed liposuction to be performed in bigger volumes entirely under local anaesthetic without the requirement for sedation or general anesthesia, was originally described by dermatologist Jeffrey Klein in 1987. Prior to liposuction, Klein developed a formula that could be injected into tissue: 0.05% lidocaine, 1:1,000,000 epinephrine, and 10 mL sodium bicarbonate per liter of saline. Klein also showed that the same amount of lidocaine diluted in a big volume of fluid allowed for a good level of anesthetic to be obtained even on wide regions without any signs of systemic toxicity^[2].

Additionally, the presence of epinephrine caused a significant vasoconstriction that significantly lessens bleeding during the surgery, which was a significant issue with liposuction previous to Klein's invention^{[3][4]}.

Therefore, the primary benefit of syringe liposuction is the ability to inject fat in addition to the precision and accuracy of adipose harvested volume assessment. Particularly when significant amounts of fat need to be removed, vacuum-pump assisted liposuction makes the surgical operation more pleasant and less taxing for the physician. For significant lipoplasty treatments where the quantity of fat to be removed is a priority above the topographic, symmetric, and exact distribution of fat harvest, vacuum pump assisted liposuction was often used^[5].

A relatively new development in the treatment of lipodystrophies and abnormalities of adipose tissue is laser-assisted liposuction. Adipose tissue is immediately contacted by the laser beam as it travels there. The adipocyte membrane bursts as a result of the laser's effect, releasing its oily substance into the extracellular fluid. The risks and outcomes of laser-assisted liposuction are comparable to those of other liposuction methods. The laser can also produce neoformations, remodeling of the collagen, and restructuring of the reticular dermis in addition to its cytolytic effects on adipocytes. It is especially recommended for isolated lipodystrophic lesions on the torso or face^{[6][7]}.

The propensity to collect fluids and fat tissue cannot be completely reversed by liposuction, thus it must always be combined with conservative treatments and lymphatic flow regeneration^{[8][9][10][11]}.

Axillary hyperhidrosis^{[12][13][14]} revision of surgical scars^{[15][16][17]} and sexual dysfunctions and genital region (such as the "buried" penis in chubby men)^{[18][19]} are other, less prevalent therapeutic uses.

Following this, a different surgeon by the name of Pierre Fournier modified the surgical incision technique, added the use of compression techniques following surgery, and introduced the use of lidocaine as a local anesthetic. American doctors began experimenting with the procedure in the 1980s and came up with a number of sedative techniques that did not require general anesthesia^[20].

Doctors started using ultrasound around the end of the 1990s to liquefy fat so that it could be removed more quickly. Over the years, developments like these have improved the liposuction procedure, making it easier and less painful to remove fat while also reducing blood loss and other issues^[20].

1.3. Christopher Khorsandi, M.D.:

Up until lately, the most current development in body sculpting, fat junking, and skin tightening was ray liposuction. multitudinous businesses have created ray liposuction bias, specially Cynosure with its well-known SmartLipo™ system and Sciton Aesthetic Laser Company. For the average individual interested in learning further about ray liposuction, the sheer volume of spotlights available on the request really causes a great deal of query. The maturity of these spotlights, when compared only on the base of their manufacturer's name, really have veritably little in common. When choosing which spotlights to use for ray liposuction, Dr. Khorsandi considers the exact wavelengths that are released by those spotlights rather than the brand name of the manufacturer^[21].

In the end, the Dr. Khorsandi, the creator of personality Plastic Surgery, made the decision beforehand in his career to concentrate his practice on cutting edge aesthetic liposuction procedures after learning the swollen fashion from Dr. Jeffrey Klein, the creator of the swollen Liposuction. The thing of Khorsandi was to offer the safest, ultramodern, and least protrusive ornamental treatments. Naturally, Dr. Khorsandi was a colonist in ray technology as he was in liposculpture styles, tools, and operations. In fact, he presently instructs medical professionals from each around the world in ray liposuction styles^[21].

1.4. The tumescent liposuction of today :

Over time, the system has been further bettered and polished. currently, liposuction is carried out with exceptional art and capability exercising just original anesthesia. Giving the case 0.1 mg of clonidine orally before surgery has put an end to the days of surcharging pain and elevated heart rates^[1].

In conclusion, it's inarguable that liposuction, as of 2009, is preferable when carried out exercising the swollen approach in an inpatient terrain. It's also clear that the operation, which has further than simply aesthetic suggestions, is most suitably multispecialty and worldwide. However, instigative and as of yet unimagined developments and uses for this classic system will define the future^[22].

2. Introduction :-

One kind of surgery is liposuction. It employs suction to get relieve of fat from particular body corridor, such the stomach, hips, shanks, buttocks, arms, or neck. These regions are also shaped by liposuction. Contouring is the name of that process. Liposuction is also known as lipoplasty and body sculpting^[23].

Liposuction isn't regarded as a general weight- loss fashion or a weight- loss cover. fat people can lose further weight with diet, exercise, and other types of surgery than they can through liposuction. However, liposuction may be an option for you. If you have a lot of body fat in some areas but generally have a steady body weight^[23].

Why it's done :

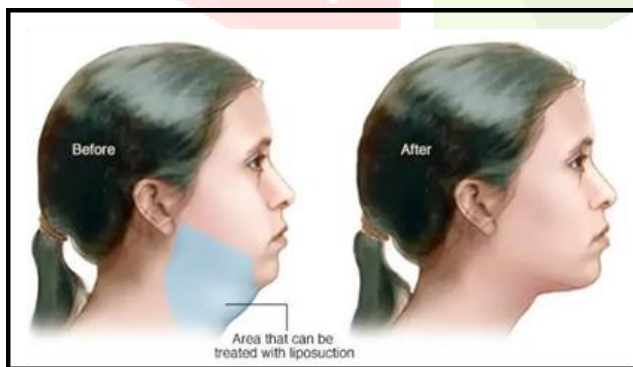

fig 1:-liposuction under chin^[23]

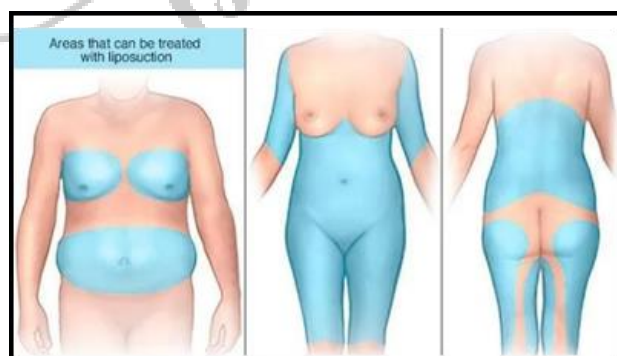


fig 2 :-

liposuction treatment areas^[23]

Fat is removed through liposuction from body corridor that do not reply to diet and exercise. These correspond of :

- Abdomen.
- Upper arms.
- Buttocks.
- Pins and ankles.
- casket and back.
- Hips and shanks.
- Chin and neck
- Inner knees

•sides

In certain cases, liposuction can also be used to treat the gynecomastia problem, which causes males to have excess breast tissue^[23].

The size of fat cells increases with weight growth. In a particular location, liposuction reduces the quantity of fat cells. The area's appearance and the quantity of fat determine how much fat is eliminated. If your weight doesn't alter, the consequent form modifications are typically permanent^[23].

The skin adapts to the changing contours of the treated regions after liposuction. Smooth skin is often a sign of healthy skin tone and elasticity. The skin in the treated regions may appear loose if your skin is thin and lacks elasticity^[23].

Cellulite-related skin dimples and other abnormalities in the skin's surface cannot be treated by liposuction. Stretch marks are not removed by liposuction either. You must be in good health and free from diseases that might complicate surgery in order to get liposuction. Blood flow issues, coronary artery disease, diabetes, or a weakened immune system are a few examples^[23].

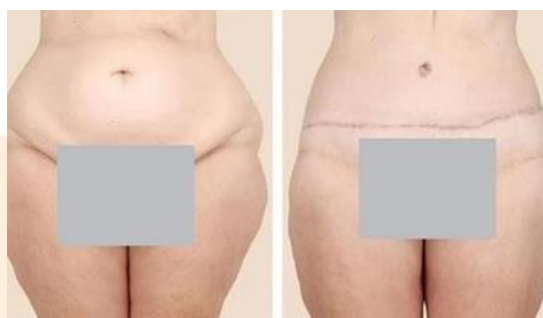


fig 3 :- before and after a liposuction treatment^[24]

2.1. Who qualifies as a liposuction seeker?

campaigners for liposuction should fulfill a number of prerequisites to insure a successful and secure operation. campaigners that are eligible for liposuction include

- grown-ups with weights that are typical or kindly over normal.
- people with well- toned muscles and firm skin that's elastic(rich in the protein elastin).
- grown-ups in generally good health.
- Fat pockets in people who do not reply well to diet and exercise
- Nulliparous.
- People who have reasonable prospects for the procedure's results.

Before prescribing therapy, healthcare professionals assess patients' common qualifications. If liposuction is the best option for you, your doctor will let you know^[24].

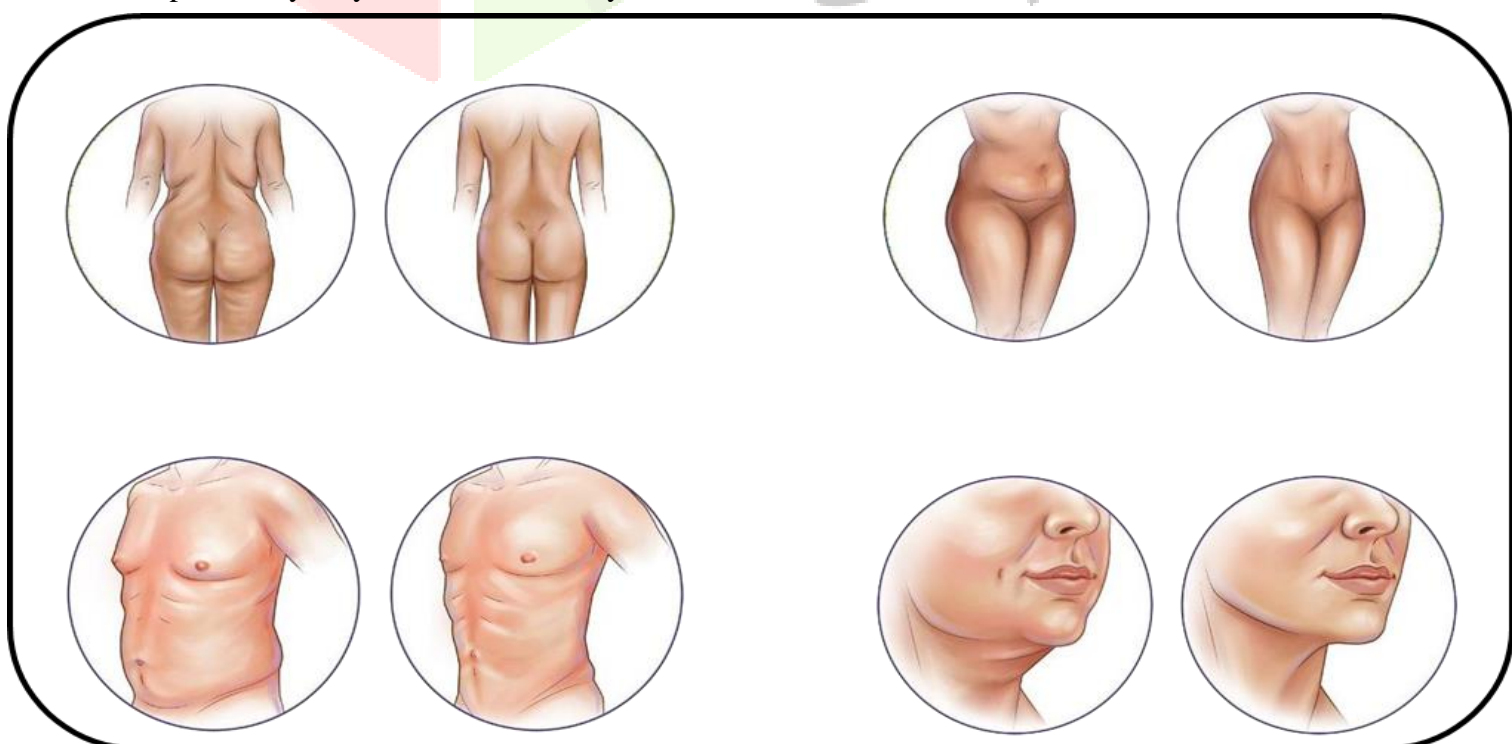


fig 4:-liposuction areas that can be treated^[25]

3. Applications:

Liposuction is typically performed to enhance looks rather than to help physical health. By leading a healthy lifestyle that includes a balanced diet, frequent exercise, and a regular sleep pattern, the majority of people would likely obtain the same or better outcomes^[26].

Liposuction is frequently only suggested if other life adaptations have failed to give the asked issues. It can cure fat deposits that defy diet and exercise^[26].

When a person gains weight, each fat cell enlarges in both size and volume. During liposuction, a few fat cells are eliminated^[26].

Before deciding whether to proceed, patients should consider the advantages and disadvantages of liposuction with their doctor. Liposuction ought to be done only after considerable thought^[26].

People with healthy skin tone and elasticity, where the skin is able to conform to new forms, respond well to liposuction. People with thin, elastic skin may experience loose-looking skin where the treatment was performed^[26].

The aspirant must be at least 18 times old and in excellent health. Liposuction shouldn't be performed on those who have circulatory or blood inflow issues, similar as coronary roadway complaint, diabetes, or compromised vulnerable systems^[26].

4. Benefits:

1. Fat Can Be Removed Safely Through Liposuction

The fact that liposuction is such a safe surgery is maybe one of the main factors contributing to its adding fashionability. Small lacerations are created in the treatment regions of your body, and after a fluid is fitted there to numb the area and break up the fat cells, liposuction is performed. Following this, suction is delivered using a bitsy tube known as a cannula that's placed into the crack. What's taken out is a blood-free, pure type of fat. Liposuction is typically an inpatient operation, and after two days of rest, cases may generally renew normal conditioning^[27].

2. Liposuction Eliminates Fat Cells Permanently

The endless junking of fat cells in the treatment spots is maybe one of Hobart locals' favorite advantages of liposuction. The fat cells can not regrow after being excluded. Just because you lose fat cells in one part of your body does not indicate you can not grow fat in another. Maintaining your weight after a liposuction treatment is pivotal to help weight gain in other body corridor^[27].

3. Losing Weight Can Help Your Health

Maintaining a healthy weight and body mass index (BMI) is crucial, as is common knowledge. Liposuction can help you get closer to your ideal weight and BMI by removing extra fat deposits, which can weigh up to 4 pounds or more per treatment region. This will enhance your health in the long run^[27].

4. Liposuction enhances both your appearance and others' perceptions of you

Numerous individualities in our society make judgments about others grounded solely on their appearance, despite the attempts of certain Hobart citizens to first perceive the beauty that exists within a person. Unfortunately, others may use the fact that you have further body fat to judge you negatively. By giving you a more physically pleasing body and altering how others perceive you, liposuction enhances your look^[27].

5. Liposuction may increase your sense of self.

Numerous people in Hobart feel tone-conscious about their bodies and the obstinate fat deposits they just can not manage to lose. Liposuction constantly gives cases an increase in tone- regard by barring these fat cells and giving them a better contoured appearance, which constantly makes them feel more confident in their vesture and swimming suits^[27].

6. Even diet and exercise can't get rid of all the fat, but liposuction can.

The ability of liposuction to effectively remove stubborn fat deposits that simply won't go away on their own, regardless of how well you eat or how frequently you exercise, may be one of the procedure's major advantages. In fact, many who maintain a balanced diet and engage in regular exercise but still struggle to lose excess fat in troublesome regions like the belly, love handles, arms, and back rolls sometimes turn to liposuction^[27].

Risks and Negative Impacts:

A cosmetic procedure called liposuction removes extra fat from particular body parts. People who have had trouble losing weight via diet and exercise alone frequently choose this alternative. Like any operation, liposuction carries dangers and possible adverse effects, despite the fact that it may be an efficient technique to shape the body and produce a more toned look. Understanding these dangers and weighing them against the possible advantages of liposuction is crucial before choosing to have the operation^[28].

5. Adverse Effects:-

The following are a few of the most typical negative effects of liposuction or other fat removal procedures:

1. Bruising and swelling

The first few days after the treatment are often when swelling and bruises are most noticeable, but they can last for many weeks. A cannula is used by the surgeon to suck away extra fat from the treatment region during liposuction, which might result in tissue damage and set off the body's natural inflammatory reaction.

The damage to the blood vessels and capillaries in the treated region, which might result in bleeding into the surrounding tissues, causes bruising.

The length of the treatment, the patient's age, and general health are a few examples of variables that might affect how severe these side effects are. In order to reduce swelling and bruising following liposuction, patients should adhere to their surgeon's post-operative care guidelines. Wearing compression clothing, refraining from physically demanding activities, taking prescribed medications, and administering ice to the afflicted regions are some examples of this^[28].

2. Discomfort and Pain

After liposuction, patients may feel pain and discomfort. The degree of discomfort varies according on the complexity of the surgery and the patient's pain threshold. Painkillers that are available over-the-counter or those that the surgeon has recommended can be used to treat this discomfort^[28].

3. Dullness

Before creating incisions, an anesthetic injection is used during liposuction treatments to numb the treated region. Numbness is thus a typical and anticipated side effect of liposuction that may linger for a long time. Swelling Numbness may sometimes result from excessive in the treated region, although this kind of numbness often goes away after the swelling goes down^[28].

4. Imperfections in the skin

Uneven skin tone due to the possibility that the surgical operation removed fat unevenly. This harm could be irreversible^[29].

5. Infection

At times, if the surgery is not carried out in a sterile setting, it might result in a serious infection that could possibly be fatal^[29].

6. Obese embolism

This is a medical emergency when fat fragments might become lodged in blood vessels and accumulate in the lungs. The brain is then reached by this^[29].

7. Internal laceration

Sometimes an internal organ might be punctured by a cannula that penetrates too far. Later on, surgery will be needed to remedy this^[29].

8. Fluid encumbrance

Temporary pockets of fluid (seromas) can form under the skin, while it's not a particularly frightening risk. A needle will be required to empty this^[29].

9. Heart and Kidney problems

The kidney and heart are immediately impacted by the change in fluid levels brought on by the injection of fluids and suctioning out of waste products^[29].

5.1. weight and makeup of the body

Liposuction generated a 9.4 1.8 kg drop in body fat (16 2% of total fat mass), which led to decreases in body weight and BMI without a discernible change in fat-free mass, according to body composition studies performed 10 weeks following the liposuction surgery (Table 1). Additionally, 10 weeks after liposuction, the amount of visceral adipose tissue and the volume of the thighs did not change, while the volume of abdominal SAT reduced by 23 7%. At later studies conducted at 27 weeks and between 84 and 208 weeks after liposuction, there were no changes in body weight, BMI, or any aspect of body composition^[30].

	Before liposuction	After liposuction		
		10 Weeks	27 Weeks	84–208 Weeks
BMI (kg/m ²)	39 ± 2	36 ± 2 ^a	36 ± 2 ^a	36 ± 2 ^a
Weight (kg)	108 ± 5	101 ± 5 ^a	102 ± 4 ^a	101 ± 4 ^a
Fat mass (kg)	59 ± 4	49 ± 3 ^a	51 ± 3 ^a	52 ± 3 ^a
Abdominal SAT (cm ²)	3,793 ± 281	2,875 ± 223 ^a	2,844 ± 339 ^a	3,178 ± 266 ^a
VAT (cm ²)	1,736 ± 389	1,604 ± 268	1,608 ± 234	1,716 ± 245
Thigh SAT (cm ²)	1,846 ± 234	1,797 ± 229	1,888 ± 200	1,813 ± 188
Systolic blood pressure (mmHg)	124 ± 5	132 ± 4	122 ± 5	133 ± 10
Diastolic blood pressure (mmHg)	70 ± 3	67 ± 5	65 ± 2	72 ± 5
LDL-cholesterol (mg/dl)	109 ± 14	110 ± 13	117 ± 12	95 ± 13
Triglyceride (mg/dl)	120 ± 29	94 ± 11	116 ± 10	108 ± 6
HDL-cholesterol (mg/dl)	48 ± 4	50 ± 6	44 ± 5	42 ± 5
Glucose (mg/dl)	117 ± 16	105 ± 11	117 ± 18	106 ± 10
Glucose AUC during 2-h OGTT (mg/dl × 120min)	22,390 ± 3,079	20,509 ± 2,177	22,448 ± 3,484	20,857 ± 2,361
HOMA-IR	2.6 ± 0.5	3.0 ± 0.7	3.1 ± 1.0 ^b	2.7 ± 0.7 ^a

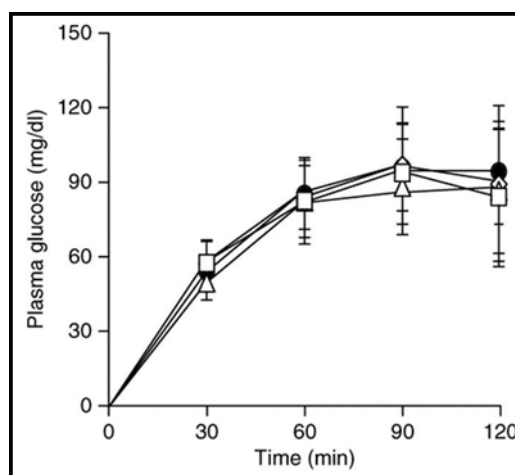
table 1: shows the research participants' body composition and metabolic characteristics both before and after liposuction^[30].

Values are means standard errors

AUC stands for area under the curve; HDL stands for high-density lipoprotein; HOMA-IR stands for homeostasis model assessment of insulin resistance; LDL stands for low-density lipoprotein; OGTT stands for oral glucose tolerance test; SAT stands for subcutaneous adipose tissue; VAT stands for visceral adipose tissue. There are just five subjects' worth of data. There are just six subjects' worth of data.

5.2. CHD risk elements:

At the outset, three patients had type 2 diabetes that was solely being managed with oral hypoglycemic medications, whereas four subjects had normal oral glucose tolerance. Throughout the course of the trial, liposuction did not affect fasting blood glucose levels, plasma LDL-cholesterol, TG, HDL-cholesterol, or blood pressure (Table 1). Additionally, after 10, 27, and 84–208 weeks following liposuction, plasma glucose concentrations during the oral glucose-tolerance test were comparable to those measured before to



liposuction^[30].

Graph between plasma glucose level according to time^[30]

Plasma glucose levels after a 2-hour oral glucose tolerance test taken before (filled circle), 10, 27, and 84–208 weeks following large-volume liposuction (open triangle, open diamond, and open square). Absolute values above the baseline (time 0) represent plasma glucose concentrations^[30].

6. Indications :-

Liposuction is utilized to remove extra fat deposits from troublesome body parts in order to accomplish body sculpting. Fat is suctioned out of defined body parts that may be contoured. The belly, flanks, trochanteric region, lumbar region, and gluteal region are the areas most often treated with liposuction between the inframammary fold and gluteal fold (Figure 5). The thighs, calves, and breasts (such as through breast reduction surgery) are other regions where fat can be removed. The position of the incision is crucial in terms of anatomy, and the surgeon should choose areas that allow for wide cannula fanning during the treatment and where the surgical scar, while modest, may be covered by clothes^[31].

The following are typical liposuction indications :

- arthritis in the lower limbs and obesity
- The metabolic syndrome and obesity
- Lipedema and the condition of lipodystrophy
- Multiple symmetric lipomatosis (also known as Launois-Bensaude syndrome or Madelung illness)
- HIV-related cervicodorsal lipodystrophy and insulin-induced lipohypertrophyLipoma
- Giantomasticism, gigantomastia, and gynecomastia
- Dercum illness
- Cystic lymphangioma and lymphphangioma
- Body deformity on an aesthetic level^[32]

Even when done correctly, diet and exercise are insufficient to lessen the imbalance between the upper and lower body. In fact, on occasion, they increase the visibility of the anesthetic administration since the patient only glides in the upper body^{[33][34]}. The size and contour of the limbs are greatly improved by skin and subcutaneous excision, although there might be serious side effects. Given the widespread nature of lipedema adipose hypertrophy, suction-assisted lipectomy may be a useful surgical choice. In situations of chronic superfluous skin, it may be supplemented with restricted skin and subcutaneous tissue excision^{[34][35]}.

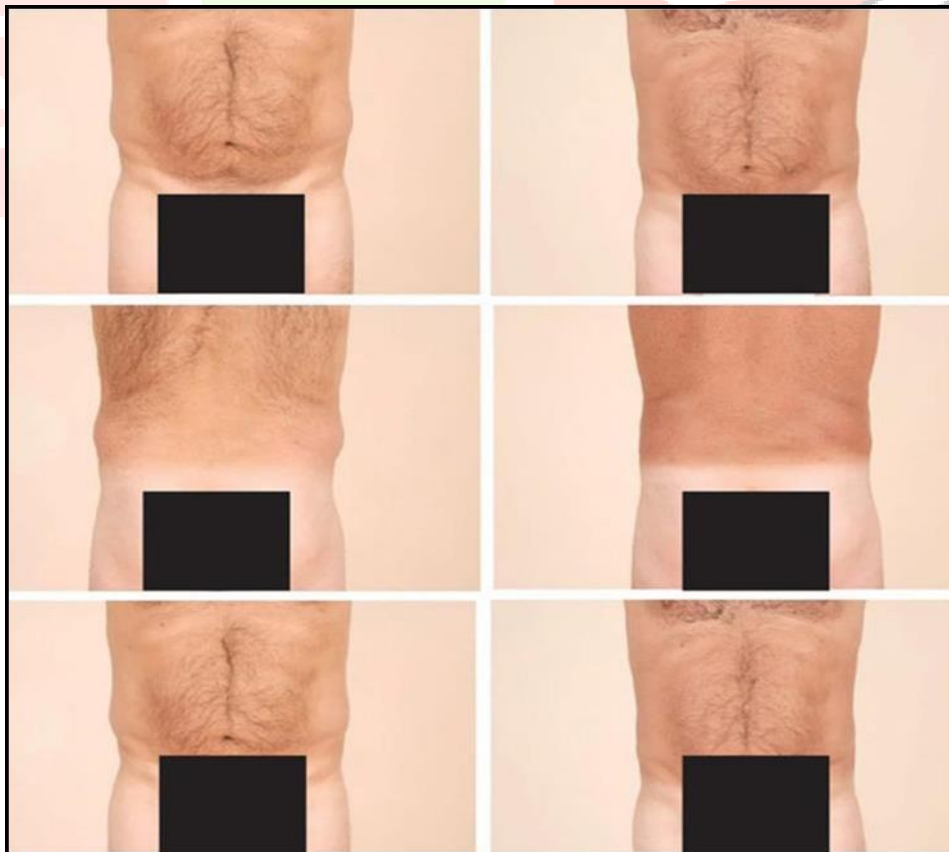

figure 5: left : shows the preoperative look of a 52-year-old man who had liposuction for localized obesity in the bilateral flanks and belly. right: The same patient six months later, 1.4 L of adipose tissue had been removed^[31].

The lateral gluteal depression (depression in buttocks surface), gluteal crease, distal posterior thigh, midmedial thigh, and inferolateral iliotibial tract are the five zones where superficial subcutaneous tissues attach to the underlying deep fascia of muscle. Suctioning from these zones raises the risk of contour abnormalities since they determine the body's natural shape^[36]. To get desirable cosmetic results, patients should ideally have good skin elasticity and have 20% to 30% of their optimal body weight^[37].

For postsurgical bariatric patients, liposuction is also increasingly being utilized as an adjuvant to improve other aesthetic treatments including breast augmentation, cervicoplasty, abdominoplasty, gluteal fat transfer, and body contouring (Figures 6 and 7)^[38]. Also possible with liposuction is enhancing gender-specific characteristics^[39]. The objectives of liposuction in women are to support the shapely contours of the buttocks, waist, hips, and breasts. In order to attain upper body dominance in males, liposuction is used to remove extra flank adipose tissue (also known as "love handles").

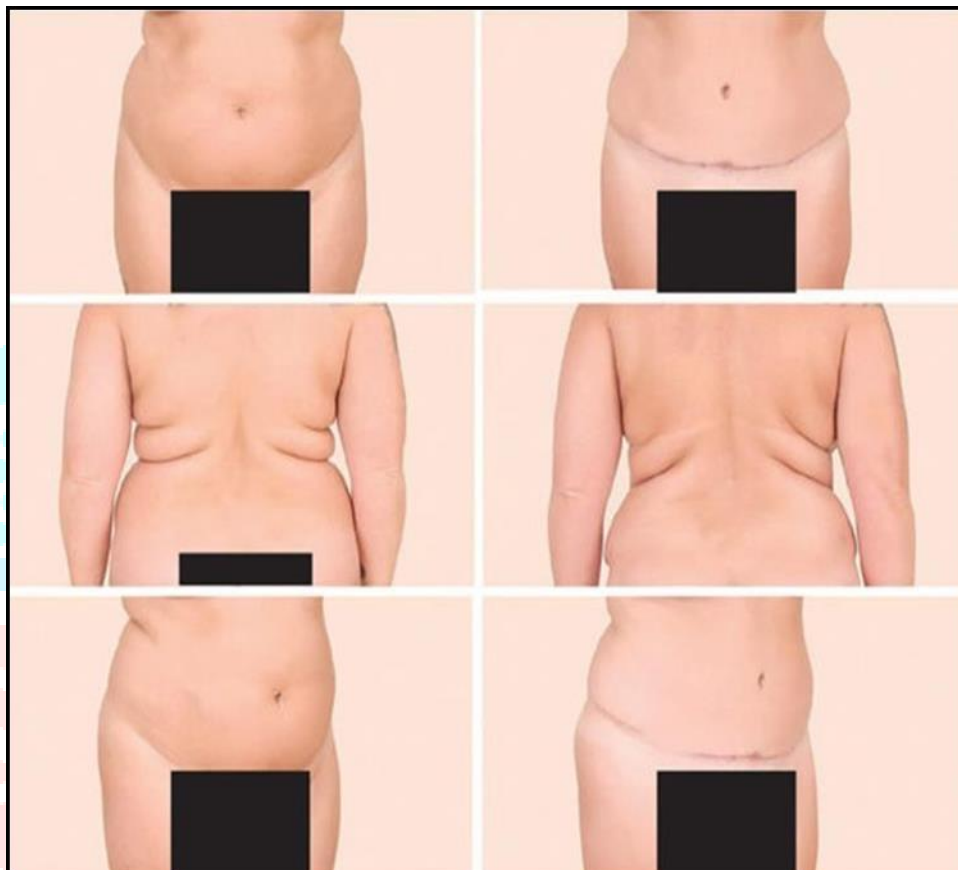


figure 6: left: A 38-year-old lady with extra skin and fat in the anterior belly as well as extra fat in both the upper back and hips. right: The same patient 5 months later following a complete cosmetic abdominoplasty and liposuction of the bilateral upper back and hip regions (with a total of 2 L of tissue removed). this image demonstrates how both operations can be combined safely and provide pleasing outcomes^[31].

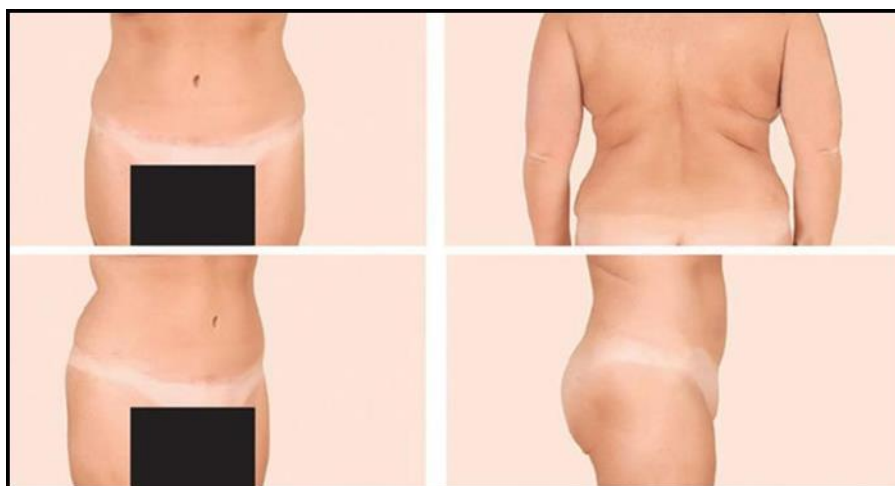

figure 7:the same patient from Figure 6 is showing sustained long-term outcomes after abdominoplasty and liposuction almost 19 months after surgery while also losing weight.Take note of the steady decrease in the adiposity on the bilateral flanks and upper back^[31].

The most prevalent benign tumor of soft tissues, lipomas have a wide range of sizes. Simple surgical excision is still the best and most common form of therapy, although removing big or many tumors can be challenging and leave unsightly scars.^[40]

However, liposuction has been documented in the literature as a method for removing bulky lipomas or numerous lipomas.^{[40][41][42]} The drawback of this method is that it frequently results in inadequate resection and has a high recurrence rate.^[41]

You can pick the region where the scar will be placed since the minor liposuction incision can be placed in a location that is less apparent than the lipoma-affected area. Additionally, in the event of multiple lipomatosis, a single incision may be used to treat several lesions, the tiny incision heals quickly, and postoperative pain is limited^[43]. The many-lipoma syndromes and the well-known multiple lipomatosis linked to some hereditary disorders can both be treated with liposuction.^{[44][45]}

There is a significant increase in the breast fat component in female macromastia and gigantomastia. Significant symptoms including neck and back ache, rashes, and skin irritations are frequently brought on by large and heavy breasts. Combining liposuction with conventional resection mammoplasty enables volume reduction prior to excision and refinement of results following reconstruction with a simpler surgical approach and superior cosmetic outcomes.^{[46][47][48]}

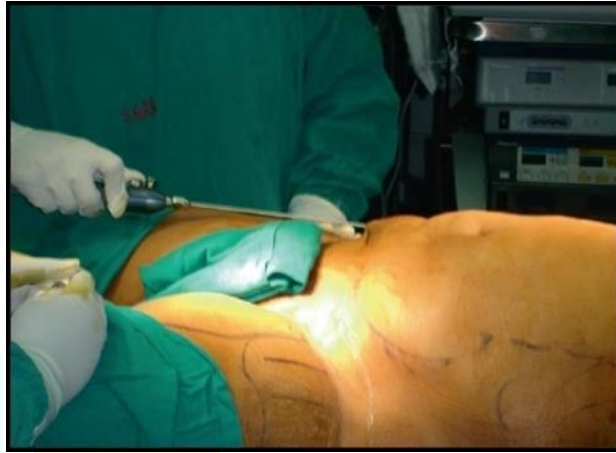The most frequent cause of lymphedema is the loss of one or more lymph nodes due to neoplastic illness. Lymphedema has a wide range of etiologies. consists of an obstruction to the lymphatic flow that causes lymphatic fluid to build up in the dermis and subcutaneous tissues. Hypercellularity, increasing fibrosis, and cutaneous dermal thickening are all effects of lymphatic fluid that has been accumulating over time. Lipids accumulate in adipocytes and macrophages as a result of reduced lipid transport caused by restricted lymph flow, leading to an increase in adipose tissue.^{[49][50][51][52]}

In chronic lymphedema, adipose tissue buildup, not fluid, is primarily responsible for the area's increased volume. Conservative treatments and lymphatic flow restoration are thus ineffective at this point. Prior to the need for surgical removal of the subcutaneous tissues that are large. While liposuction offers good long-term cosmetic and functional results with a low risk of problems, traditional surgical excision leaves an unsightly scar and produces undesirable consequences.^{[53][54][55]}

The initial surgical method of choice for pseudogynecomastia and gynecomastia is liposuction subcutaneous mastectomy. The fatty tissue in the area of the male breast develops more rapidly in pseudogynecomastia. However, in real gynecomastia, the male breast gland's bulk increases along with a thick vascular and fibrous stroma, which makes suction more challenging. The periareolar or transareolar incision is typically used in conjunction with the gynecomastia liposuction procedure to remove the glandular tissue under direct view. After that, for a few days, it's required to wear a compression garment and limit activity to prevent bruising and hematoma development and promote the skin's adhesion to the chest in a healthy manner.^{[56][57][58]}

7. Challenges with anesthesia:-

As more people become aware of cosmetic surgery, liposuction has become a frequent plastic surgery practice. A cannula and a powerful vacuum are used in the procedure known as liposuction to remove fat from deposits under the skin. In the US, more than 341,000 liposuction procedures were performed in 2008^[59]. The anesthesiologist should be aware of the dangers and have a thorough understanding of the pathophysiology of obesity as well as fluid management during liposuction because there have been reports of negative outcomes^{[60][61][62]}. This procedure is getting more and more widespread in India, despite the lack of statistics. Daily liposuction operations are carried out in our institution, ranging from extremely large volume procedures for the legs to extremely small volume procedures for the arms, thighs, and midsection[Figure 8].



From 2008 to 2010 (3 years), 273 liposuction operations were completed at our facility.
figure 8:liposuction of abdomen and thighs^[63]

8. Anaesthesia Technique:

Liposuction can be done under either local, regional, or general anesthesia. There isn't a single anesthetic technique that has been demonstrated to be superior to the others. The extent and location of the liposuction, as well as the patient's preferences, influence the anesthetic technique. The anesthetic strategy will vary according on the body areas being operated on— arms, thighs, abdomen, or buttocks—and the quantity of liposuction being performed. Patients must rapidly restore their psychomotor and cognitive abilities since these therapies are typically administered in a day care environment, allowing for early discharge.

8.1. Supervised anesthetic treatment

This is a practical system for liposuction of bitsy volumes. Vasoconstrictor and original anesthetic infiltration, independently, drop bleeding and offer intraoperative analgesia. As a result, it enables liposuction to be carried out under minimum sedation, performing in a speedy recovery, earlier release, and lower case costs. But if infiltration is uneven, certain places will not have enough analgesia, challenging farther sedation.^{[64][65]}

For small volume liposuction, sedation with midazolam(1- 3 mg) and analgesia with fentanyl(25- 50 mg) or remifentanil(12.5- 25 mg) are constantly used. For supervised anesthesia treatment, propofol(0.5 – 1 mg/ kg) may be administered on an as- demanded base. Low tablets of ketamine(0.25-0.50 mg/ kg) in combination with midazolam effectively reduce intraoperative opioid use and postoperative analgesic use. 2 – 5 mg/ kg of clonidine, is a helpful adjunct in dreamy styles as well.^{[66][67][68]}

8.2. Epidural lumbar anesthesia

To give analgesia during abdominal liposuction, this is frequently utilized. The analgesia is of a higher caliber than that produced by local infiltration. However, a significant epidural blockade must only be used in individuals with a strong cardiac reserve since it is typically accompanied by hypotension.^[69]

8.3. The subarachnoid block

This kind of liposuction is effective below the umbilical region. This method is risk-free, inexpensive, and has little adverse effects under certain circumstances. The anesthesia and muscle relaxation are of the highest caliber, and the first 24 hours after surgery, when opioids are injected into the subarachnoid space, there is good analgesia.^[70]

8.4. Overall sedation

This is suggested for liposuction of high volumes or if the case wants it. Due to its pharmacokinetic profile and ingrain antiemetic characteristic, which guarantees a speedy case recovery, propofol is the preferred induction agent.^[71] A supraglottic device, proseal LMA(PLMA), or I- gel can be used to save airway. A nondepolarizing drug, similar as atracurium, rocuronium, or vecuronium, can relax muscles. Short- acting opioids like fentanyl and remifentanil, as well as the injection of lignocaine into subcutaneous towel, offer analgesia.^{[72][73]}

9. Liposuction surgeries:-

In liposuction surgery, individual tastes and variations may show aesthetic flare in addition to technical advancement. A surgeon builds their unique method to liposuction by first studying the procedures and approaches of other surgeons, copying the good components, and discarding the problematic ones.^[74]

Three criteria may be used to assess any surgeon's tumescent technique: safety, aesthetic results, and ethics. All patients should be aware of the surgeons' aesthetic results. It might be more difficult to evaluate safety and ethics. If one surgeon's approach appears to give a greater level of patient safety than that of another surgeon, it has to be assessed and criticized. The usage of the phrase "tumescent technique" by a surgeon to attract future patients is unethical and warrants condemnation really carrying out an extremely dangerous and dated procedure.^[74]

When utilizing microcannulas, either a local or systemic anesthetic can be employed. Microcannular liposuction has a number of advantages, but two in particular stand out: the results are exceptionally smooth, and fewer extra touch-up procedures are required to fix flaws. The second liposuction technique to be reviewed uses a microcannular tumescent technique, which includes a number of modest modifications designed specifically to make it simpler to do liposuction fully under local anesthesia. For instance, if surgeons do not penetrate gently and correctly or do not use microcannulas, it will be difficult for them to accomplish liposuction under local anesthesia.^[74]

Today's options include tumescent anesthetic, dry, moist, superwet, and wet. The primary differences among these approaches are in the amount of infiltrating solution injected into the tissues and the percentage of aspirated fluid that is lost as a result of blood loss. The dry method, which excludes the use of infused fluid, results in a 25–40% blood loss of the volume removed. Blood loss during tumescent and superwet liposuction operations is estimated to be 1% of the aspirate volume.^{[75][76]}

All medical specialities have increasingly adopted Klein's tumescent approach^[77] due to its benefits, particularly its ability to reduce bleeding.^{[78][79]}

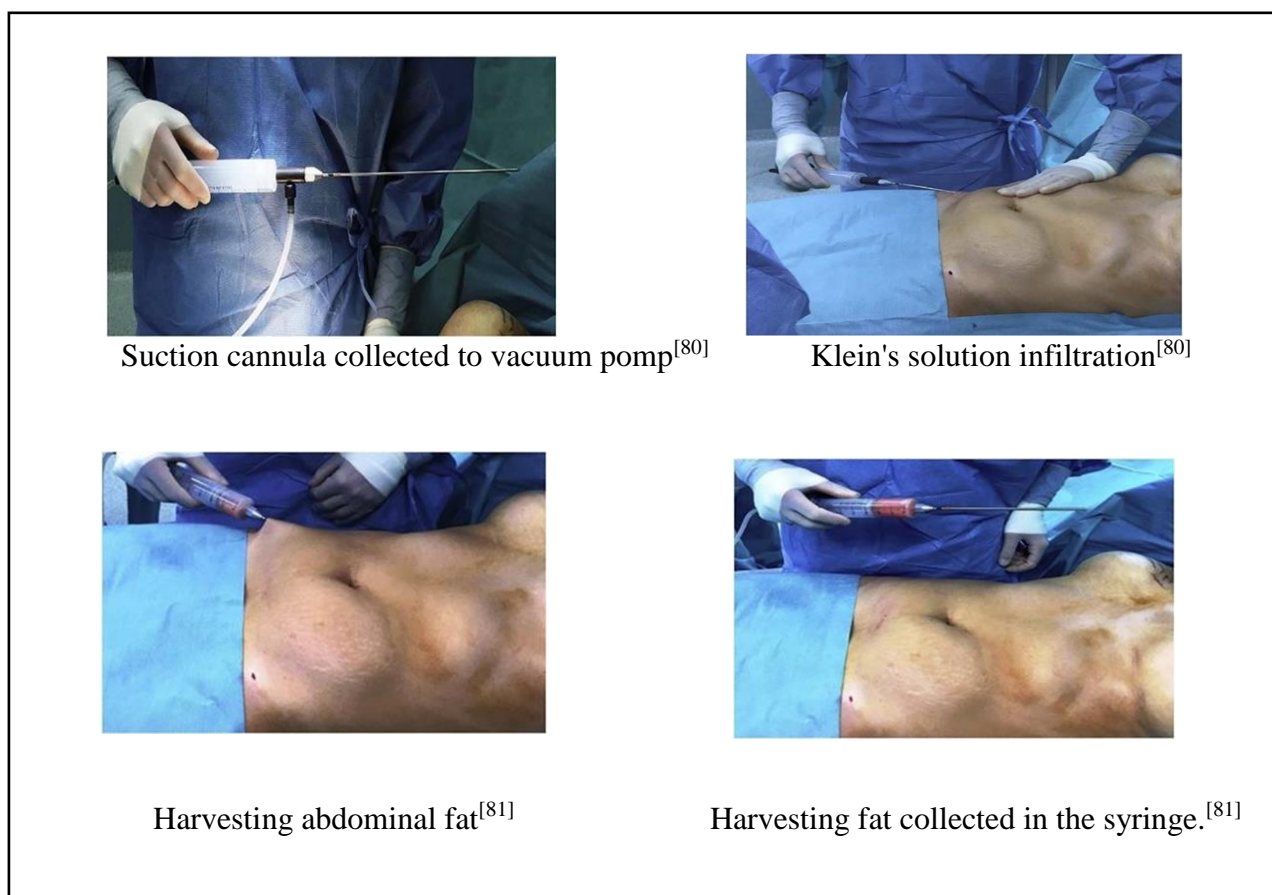
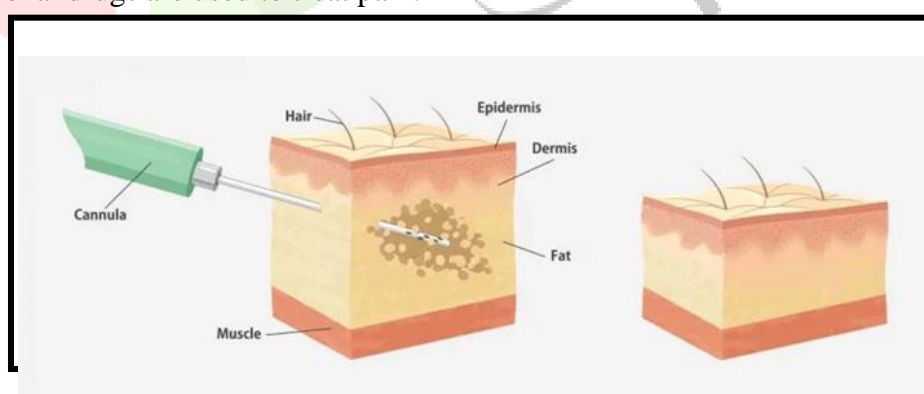


Fig 9

Different liposuction methods are available to meet specific therapeutic goals. There are several types of liposuction, including:

9.1. Liposuction with tumescence:

The most popular liposuction technique is tumescent liposuction. A saline (salt water) solution is injected by the surgeon into your problem regions. The cocktail includes drugs like the blood vessel-contracting epinephrine. This treatment lessens blood loss and makes it easier for your surgeon to remove fat. There are situations when additional drugs are used to treat pain.^[82]

fig 10 : tumescent liposuction^[84]

9.2. Liposuction with ultrasound assistance / Ultrasound assisted liposuction (UAL):

Your surgeon will use ultrasonic energy to liquefy your fat before extracting it from your body using a metal rod that is inserted beneath your skin.^[82]

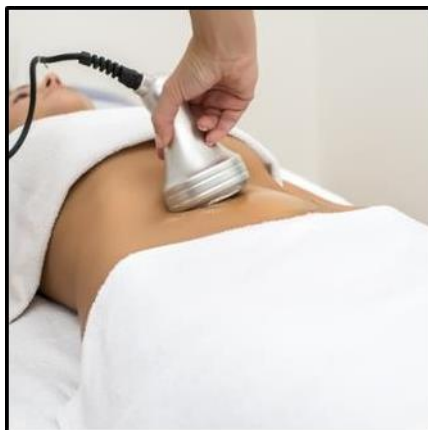


fig 11 : ultrasound assisted liposuction ^[85]

A specific emitter can be used to apply ultrasound above the skin, or an ultrasonic cannula can be used to apply ultrasound below the skin's surface.^[83]

Two different kinds of ultrasound cannulae exist:^[83]



1. fig 12 :a solid probe:^[86]



2. fig 13 : a hollow-core probe:^[87]

Under the skin, the solid probe gathers emulsified fat and tumescent solution, which is subsequently suctioned out using a regular cannula. The hollow-core has the dual function of emulsifying and eliminating fat.^[83]

The UAL procedure is appropriate for places with fibrous tissue, such as the male breast, the back, and locations where liposuction has already been performed.^[83]

9.3. Vibration Amplification of Sound Energy at Resonance (VASER) / Resonance- based Vibration Amplification of Sound Energy :

With VASER liposuction, fat and fat cells are easily broken up and removed from your body using an ultrasonic device and a stainless steel instrument (cannula) with grooves. This kind of UAL exists.^[82]

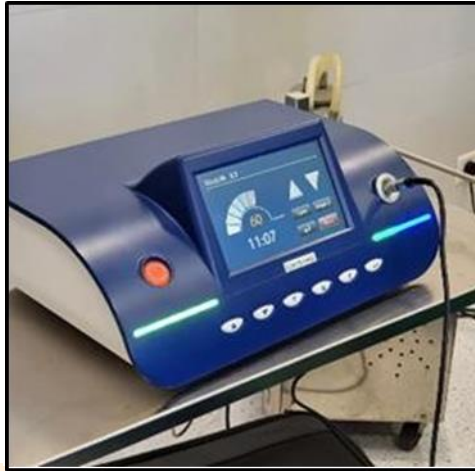


fig 14 : vibration amplification of sound energy at resonance ^[88]

9.4. Liposuction using suction :

A vacuum is used in the classic method of liposuction known as suction-assisted liposuction to remove fat from your body.^[82]

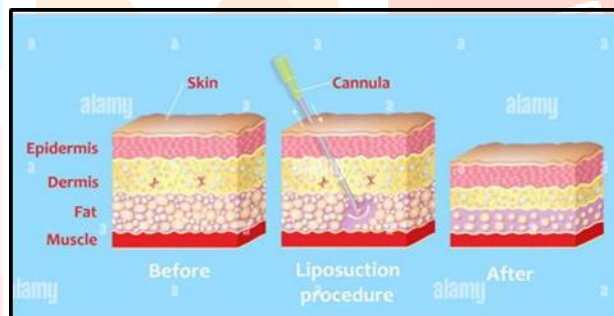


fig 15 : suction-assisted liposuction ^[89]

9.5. Power-assisted liposuction (PAL)/Liposuction with power assistance:

Power-assisted liposuction breaks up your fat by moving a small stainless steel tool (cannula) back and forth across it. The cannula makes your surgeon's job easier and the procedure more precise.^[82]

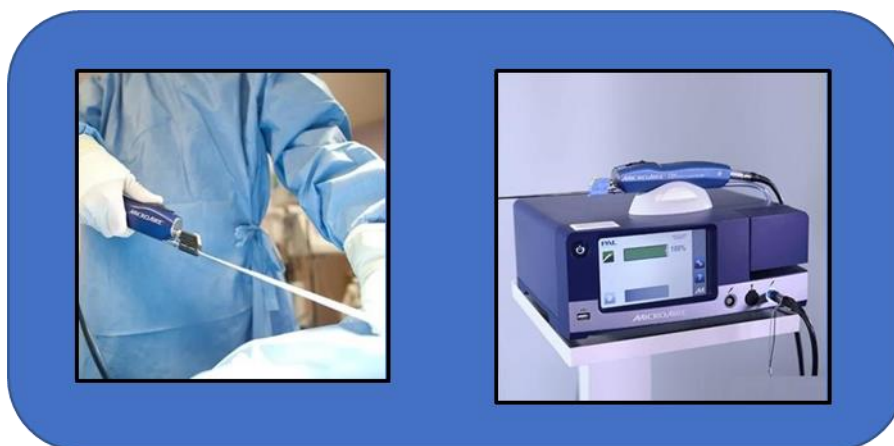

fig 16 : power-assisted liposuction ^[90]

9.6. Liposuction with laser assistance (Smartlipo™ and SlimLipo™):

Your doctor will use a strong laser beam on a short, flexible fiber to liquefy your fat in order to break it down and facilitate removal. The laser-assisted liposuction procedure just needs a small skin incision.^[82]

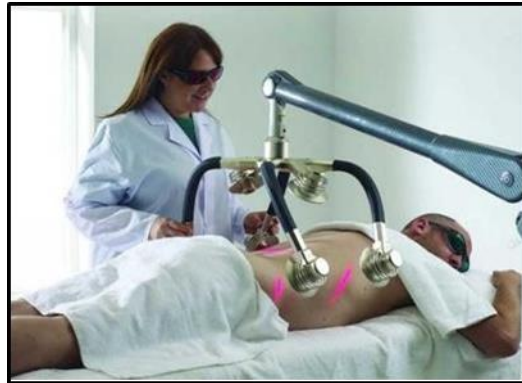

fig 17 : laser-assisted suction^[91]

This technique, sometimes referred to as laser guided lipo, uses the strength and sophistication of medical laser beams to liquefy fat. It uses a laser beam to break adipocytes and then uses various cannulae to suck out the dissolved fat from the treated region. As the first laser for lipolysis, neodymium-doped yttrium aluminum garnet (Nd:YAG) 2064 nm has been developed.^[83]

10. Complications:-

Among the potential side effects of liposuction are:^[92]

- Thermal burns or other heat-related injuries to deeper tissues or the skin caused by the ultrasonic machine used to liquefy fat cells. With ultrasound-assisted liposuction, this is possible.
- Lignocaine toxicity (if there is too much lignocaine in the solution). Tumescence and super-wet liposuction may cause this.
- Fluid buildup in the lungs (if too much fluid is administered). Tumescence and super-wet liposuction may cause this.
- Excessive fluid loss might result in shock; fluid buildup.
- Infection—this is a major consequence since it is challenging to treat infections that form in fatty tissues.
- Delayed recovery
- Friction burns or other nerve or skin damage
- Uneven skin surface, rippling, or uneven curves
- An uneven or baggier skin surface
- A change in how the skin feels, such as numbness
- Alterations in skin pigmentation, discoloration, or edema
- Serious scarring
- Injury to more deeply seated tissues such as the nerves, blood vessels, muscles, lungs, and abdominal organs
- Pain that could be persistent
- Drug-related allergic responses
- The development of blood or fat clots, which may spread to the lungs and result in death.
- Legs that are always swollen

•lung, heart, and deep vein thrombosis problems.

•Additional surgery could be required to treat problems^[92]

10.1. Major Complications(serious difficulties):

10.1.1. Pulmonary embolism and deep vein thrombosis :

One of the most terrifying side effects is deep venous thrombosis (DVT), which can lead to pulmonary embolism (PE) and its catastrophic outcomes. One-fourth of all fatalities among patients having cosmetic surgery have been attributable to PE.[93] Healthy people can avoid venous thrombosis with a thorough preoperative evaluation to identify risk factors for thrombosis, the use of preventive measures (stockings, pneumatic intermittent compression systems, etc.), early mobilization, appropriate hydration, and anticoagulation when necessary, as well as early mobilization. Early movement (six to eight hours after surgery) and the use of compression clothing are essential during the first 24 hours following surgery. Massage and lymphatic drainage may also be regarded as adjuvant treatments. These signs Sharp chest discomfort, shortness of breath, chest pain that gets worse with deep breathing or coughing, coughing up blood, tachycardia, sweating, and anxiety are all signs of pulmonary embolism.^[96]

10.1.2. Toxic effects of lidocaine and epinephrine :

The recommended dosages of lidocaine are 4-5 mg/kg for lidocaine alone and 7 mg/kg when combined with epinephrine. When used in high volume infiltration as a tumescent fluid, doses up to 33-35 mg/kg have been described as safe in the literature.[94] The drug's pharmacokinetics, with a peak concentration between 8 and 12 hours after infiltration, is the next crucial component to take into account. Prior to liposuction treatments involving the infiltration of lidocaine, the liver metabolism should be evaluated since any medication interactions that influence it might have a negative impact on the patient's normal ability to remove the drug.^[96]

The epinephrine impact should be taken into account as an additional component in determining how stressful an operation is overall. During the history and physical, cardiac function should be questioned and, if required, adequately examined. Patients who have pheochromocytoma, hyperthyroidism, severe hypertension, heart illness, or peripheral vascular disease should not take epinephrine. Additionally, when epinephrine is used with halothane anesthesia or in people who are prone to them, cardiac arrhythmias might happen. Particularly in hyperthyroid individuals, changes in the pace and force of contraction as well as hypertension and irritability of the heart can happen.^[95]

10.1.3. cardiac arrest & fluid changes :

To maximize excellent perfusion and reduce the risk of cardiac problems and mortality, proper preoperative, intraoperative, and postoperative fluid management is crucial. To minimize the excessive third spacing that might endanger the capacity to correct for fluid shifts on the average patient, fluid aspirations should be kept to a maximum of 5 L each session. Other guidelines include treating no more than 30% of the body's surface and aspirating no more than 5% of the body weight.^[96]

10.1.4. Sepsis and infection :

It is important to take erythema, discharge, and even edema seriously. Infections that are localized should be quickly evaluated and treated. Infections that go unnoticed or untreated may threaten a significant surface area or possibly result in necrotizing fasciitis and other more serious systemic symptoms. In addition, since there is always a chance that an intra-abdominal organ can become perforated, systemic symptoms without local proof need to be addressed. Careful aseptic procedure is necessary, including appropriate tool handling and skin preparation. Antibiotics used during surgery have a big impact on liposuction. The total regions treated are typically large, and appropriate antibiotic distribution during the surgeries is crucial, even if the treatment may be regarded as being of modest complexity.^[96]

10.1.5. Visceral Injury and Intra-Abdominal Perforation :

An organ damage within the abdominal cavity is often treatable with quick detection and without major long-term consequences. However, the results of a liposuction cannula puncturing the intestine might be lethal if the diagnosis is delayed until the infection has spread throughout the abdominal cavity. Any intestinal damage will instantly produce extreme pain when liposuction is entirely performed under local anaesthetic, which

should prompt a rapid diagnosis. The patient and the physician, however, might not be aware of the harm until it is too late if the liposuction is performed while the patient is under general anesthesia.^[97]

10.1.6. Seroma or Hematoma :

After liposuction, it is possible for bleeding into a closed area under the skin (hematoma) or for serum to leak into a closed space under the skin (seroma). Obesity, excessive liposuction

using a big cannula, and ultrasonic aided liposuction (UAL) all enhance the likelihood of severe problems.^[97]

10.1.7. Emphysema or swelling :

The natural healing process involves temporary swelling in the liposuctioned regions, which typically goes down in 4 to 12 weeks. It is possible to achieve post-operative drainage of the leftover, blood-tinged local anesthetic solution by leaving incision sites exposed (and not closing them with sutures). The amount and severity of postoperative swelling and edema are reduced by promoting this outflow of inflammatory fluid. A significant quantity of inflammatory material is retained under the skin when the surgeon sutures up the incision sites, speeding up the swelling process.^[97]

10.1.8. Dermato-Necrosis :

Skin necrosis, or the death of skin cells in a defined region, may be caused by thermal injury (burn or freezing), infection, or damage to the blood vessels that provide the skin with oxygen. If the surgeon purposefully injures the skin with the liposuction cannula (some surgeons mistakenly assume that purposely hurting the skin will stimulate contraction of the skin), skin necrosis may result after liposuction. The burning of the skin or blood vessels that feed the skin by ultrasonic energy during ultrasonic assisted liposuction (UAL) frequently results in skin necrosis. Finally, skin necrotizing fasciitis can result from a rare but serious bacterial infection, and with the application of Reston foam following liposuction to the skin in an effort to lessen bruising.^[97]

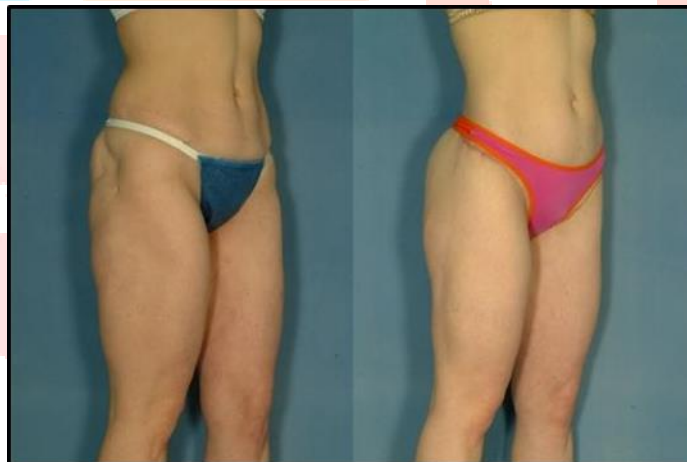

fig 18 : skin surface irregularities corrected by spiral lift and rotational dermal-fat flap with fat injection^[96]

10.1.9. Edema of the lungs :

It has been shown that high intravenous fluid dosages administered before, during, or after liposuction can result in an excessive buildup of fluid in the lungs. Death can result from severe pulmonary edema. Due to the significant amount of diluted local anesthetic fluid injected beneath the skin during tumescent liposuction, intravenous fluids are neither necessary nor recommended. Any fluid lost during liposuction can be replaced with tumescent local anesthetic fluid. Any extra fluid administered via an IV is unneeded and perhaps excessive.^[97]

10.1.10. Negative drug reactions(toxicity or allergic reactions) :

Any drug can cause this to happen. Complications during or following liposuction might arise from both local anesthetic and general anesthesia.^[97]

10.1.11. Death :

One fatality occurred in every 5000 cases of liposuction, according to a survey of surgeons who perform the procedure under general anesthesia in the year 2000. In a more recent analysis of doctors who solely perform tumescent liposuction under local anesthetic, there were no fatalities in 65,000 instances.^[97]

10.1.12. Skin hyperpigmentation on the face :

This issue is brought on by the accumulation of hemosiderin, which is produced when hemoglobin is exposed to UV radiation and degrades. The pigments get fixed to the skin's outermost layers as a result of this process. Avoiding the sun's rays while the ecchymosis is still present is considered prevention. Hyperpigmentation instances are frequently linked to vasculopathies. Ecchymosis and hyperpigmentation have diminished with the introduction of more recent technology like LAL.^[96]

11. Conclusions :-

After more than 40 years of development, liposuction is now one of the most sophisticated cosmetic procedures available.

The chance of complications during surgery is relatively low and the procedure is easy. However, you need to have solid technical knowledge and excellent expertise if you want to get good cosmetic outcomes and prevent the biggest number of issues (Fig 19 and Fig 20).

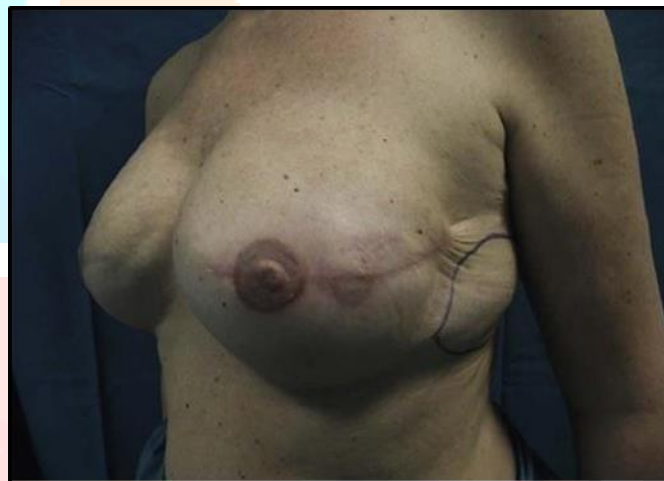

fig 19 : following oncologic breast surgery, a 53-year-old patient had body remodeling of the left axillary pillar. pictures of the liposuction treatment before and after.

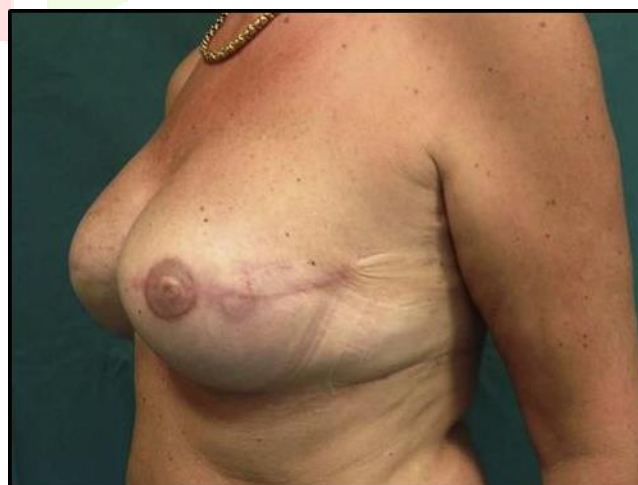

fig 20 : after undergoing oncologic breast reconstruction, a 53-year-old patient's left axillary pillar underwent body remodeling. pictures of the liposuction treatment before and after.

Both aesthetic surgery and functional and reconstructive surgery both have several clinical uses for liposuction. The once-clear excluding factor of obesity was no longer taken into consideration.^[98]

Liposculpture is a fantastic technique for patients who experience significant weight reduction to redefine their body's profile. However, excision surgery to remove extra skin must always be combined in order to get excellent cosmetic outcomes. Adipose tissue can be suctioned to create empty spaces, which speeds up and simplifies surgery while also lowering the risk of problems.^[99-101]

According to a recent study, abdominal lipectomy is sometimes combined with other treatments to help bariatric surgery patients lose weight permanently.^[102]

Liposuction has grown in significance as a technique for obtaining autologous fat and adipose- derived stem cells in recent years. Lipofilling is a commonly employed procedure in a variety of therapeutic conditions, including the improvement of retrograde or atrophic scars, loss of lumen, and regenerative medicine for the treatment of chronic wounds.^[103-113]

Adipose tissue has drawn a lot of attention lately. Numerous research conducted over the past few decades have shown how diversely differentiated and regeneratively capable adipose- derived stem cells are.^[114-119]

The current method of harvesting uses modest amounts of the conventional liposuction procedure using syringes to minimize harm to adipocytes. Adipose-derived stem cells have significant potential for use in a variety of medical and surgical specialties, which justifies current and future efforts to develop innovative methods for separating, gathering, and optimizing these stem cells.^[120-124]

12.Reference:-

- 1.<https://www.drpuneetgupta.co.uk/blog/history-of-liposuction/#:~:text=The%20origins%20of%20liposuction%20date,reduce%20s edation%20and%20morbidity%20risks.>
- 2.Klein J.A. The tumescent technique for liposuction surgery. *Am. J. Cosmet. Surg.* 1987;4:263–267. [Google Scholar]
- 3.Klein J.A. Tumescent technique for local anesthesia improves safety in large volume liposuction. *Plast. Reconstr. Surg.* 1993;92:1085–1098. [PubMed] [Google Scholar]
- 4.Klein J.A. Tumescent technique for regional anesthesia permits lidocaine doses of 35 mg/kg for liposuction. *J. Dermatol Surg. Oncol.* 1990;16:248–263. [PubMed] [Google Scholar]
- 5.Lewis C.M. Comparison of the syringe and pump aspiration methods of lipoplasty. *Aesth. Plast. Surg.* 1991;15:203–208. [PubMed] [Google Scholar]
- 6.Sterodimas A., Boriani F., Magarakis E., Nicaretta B., Pereira L.H., Illouz Y.G. Thirtyfour years of liposuction: past, present and future. *Eur. Rev. Med. Pharmacol. Sci.* 2012;16:393–406. [PubMed] [Google Scholar]
- 7.Valizadeh N., Jalaly N.Y., Zarghampour M., Barikbin B., Haghghatkah H.R. Evaluation of safety and efficacy of 980-nm diode laser-assisted lipolysis versus traditional liposuction for submental rejuvenation: a randomized clinical trial. *J. Cosmet. Laser Ther.* 2016;18:41–45. [PubMed] [Google Scholar]
- 8.Jensen M.R., Simonsen L., Karlsmark T. Lymphoedema of the lower extremities- background, pathophysiology and diagnostic considerations. *Clin. Physiol. Funct. Imaging.* 2010;30:389–398. [PubMed] [Google Scholar]
- 9.Brorson H. From lymph to fat: complete reduction of lymphoedema. *Phlebology.* 2010;25:52–63. [PubMed] [Google Scholar]
- 10.Brorson H. Liposuction in arm lymphedema treatment. *Scand. J. Surg.* 2003;92:287–295. [PubMed] [Google Scholar]

11. Greene A.K., Slavin S.A., Borud L. Treatment of lower extremity lymphedema with suction-assisted lipectomy. *Plast. Reconstr. Surg.* 2006;118:118–121. [PubMed] [Google Scholar]
12. Shenaga S., Spira M. Treatment of bilateral axillary hyperhidrosis by suction assisted lipolysis technique. *Ann. Plast. Surg.* 1987;19:548–551. [PubMed] [Google Scholar]
13. Li Y., Li W., Li X. A refined minimally invasive procedure for radical treatment of axillary osmidrosis: combined tumescent liposuction with subcutaneous pruning through a small incision. *J. Plast. Reconstr. Aesthet. Surg.* 2012;65:320–321. [PubMed] [Google Scholar]
14. Lee D., Cho S.H., Kim Y.C. Tumescent liposuction with dermal curettage for treatment of axillary osmidrosis and hyperhidrosis. *Dermatol Surg.* 2006;32:505–511. [PubMed] [Google Scholar]
15. Atiyeh B.S. Non-surgical management of hypertrophic scars (Hss): evidence- based therapies, standard practices and emerging modalities. *Aesth. Plast. Surg.* 2007;31:468–492. [PubMed] [Google Scholar]
16. Lei H., Ma G., Chen J. Combination excision and liposuction in a single-stage treatment of various skin disorders. *Int. J. Dermatol.* 2010;49:311–316. [PubMed] [Google Scholar]
17. Ibrahim A.E., Dibo S.A., Shady S.H. Reverse tissue expansion by liposuction deflation for revision of post-surgical thigh scars. *Int. Wound J.* 2011;8:622–631. [PMC free article] [PubMed] [Google Scholar]
18. Alter G.J. Pubic contouring after massive weight loss in men and women: correction of hidden penis, mons ptosis, and labia majora enlargement. *Plast. Reconstr. Surg.* 2012;130:936–947. [PubMed] [Google Scholar]
19. Mokhless I.A., Abdeldaeim H.M., Rahman A. Penile advancement and lengthening for the management of post-circumcision traumatic short penis in adolescents. *Urology.* 2010;76:1483–1487. [PubMed] [Google Scholar]
20. By Dr. Ananya Mandal, MD, Reviewed by Sally Robertson, B.Sc. <https://www.news-medical.net/health/History-of-Liposuction.aspx>
21. <https://www.vegasiliposuction.com/liposuction/history/>
22. https://cdn.mdedge.com/files/s3fs-public/issues/articles/vol28_i4_History_Lipo.pdf
23. <https://www.mayoclinic.org/tests-procedures/liposuction/about/pac-20384586>
24. <https://my.clevelandclinic.org/health/treatments/11009-liposuction>
25. <https://www.plasticsurgery.org/cosmetic-procedures/liposuction>
26. <https://www.medicalnewstoday.com/articles/180450#uses>
27. <https://robertfrankmd.com/blog/6-benefits-of-liposuction/>
28. <https://drrajatgupta.com/is-liposuction-safe-what-to-expect-risks-and-side-effects/>
29. <https://pharomeasy.in/blog/liposuction-benefits-and-risks/>
30. B. Selma Mohammed¹, Samuel Cohen¹, Dominic Reeds¹, V. Leroy Young¹ and Samuel Klein <https://onlinelibrary.wiley.com/doi/epdf/10.1038/oby.2008.418>
31. <https://consultqd.clevelandclinic.org/cosmetic-and-noncosmetic-indications-for-liposuction/>
32. <https://cosmoderma.org/indications-and-techniques-of-liposuction/#:~:text=Following%20are%20the%20common%20indications,Lipe,dema%20and%20lipodystrophy%20syndrome>
33. Todd M. Lipoedema: presentation and management. *Br. J. Community Nurs.* 2010;15:S10–S16. [PubMed] [Google Scholar]
34. Schmeller W., Hueppe M., Meier-Vollrath I. Tumescent liposuction in lipoedema yields good long-term results. *Br. J. Dermatol.* 2012;166:161–168. [PubMed] [Google Scholar]

35. Fischer G. Liposculpture: the correct history of liposuction: Part I. *J. Dermatol Surg. Oncol.* 1990;16:1087. [PubMed] [Google Scholar]
36. Rohrich RJ, Smith PD, Marcantonio DR, Kenkel JM. The zones of adherence: role in minimizing and preventing contour deformities in liposuction. *Plast Reconstr Surg* 2001; 107(6):1562–1569. doi:10.1097/00006534-200105000-00043CrossRefPubMedGoogle Scholar
37. Matarasso A, Hutchinson OH. Liposuction. *JAMA* 2001; 285(3):266– 268. doi:10.1001/jama.285.3.266CrossRefPubMedGoogle Scholar
38. Salibian AA, Frey JD, Bekisz JM, Choi M, Karp NS. Fat grafting and breast augmentation: a systematic review of primary composite augmentation. *Plast Reconstr Surg Glob Open* 2019; 7(7):e2340. doi:10.1097/GOX.0000000000002340CrossRefGoogle Scholar
39. Tabbal GN, Ahmad J, Lista F, Rohrich RJ. Advances in liposuction: five key principles with emphasis on patient safety and outcomes. *Plast Reconstr Surg Glob Open* 2013; 1(8):e75. doi:10.1097/GOX.000000000000007CrossRefGoogle Scholar
40. Stebbins W.G., Hanke C.W., Petersen J. Invasive removal of large lipoma after laser lipolysis with 980 nm diode laser. *Dermatol Ther.* 2011;24:125–130. [PubMed] [Google Scholar]
41. Medina C.R., Schneider S., Mitra A. Giant submental lipoma: case report and review of the literature. *Can. J. Plast. Surg.* 2007;15:219–222. [PMC free article] [PubMed] [Google Scholar]
42. Choi C.W., Kim B.J., Moon S.E. Treatment of lipomas assisted with tumescent liposuction. *J. Eur. Acad. Dermatol Venereol.* 2007;21:243–246. [PubMed] [Google Scholar]
43. Field L., Asken S., Caver C. Liposuction surgery: a review. *J. Dermatol Surg. Oncol.* 1984;10:530–538. [PubMed] [Google Scholar]
44. Coleman W. Noncosmetic applications of liposuction. *Dermatol Surg. Oncol.* 1988;14:1085–1090. [PubMed] [Google Scholar]
45. Ross M., Goodman M. Multiple symmetric lipomatosis (Launois-Bensaude syndrome) *Int. J. Dermatol.* 1992;31:80–82. [PubMed] [Google Scholar]
46. Habbema L. Breast reduction using liposuction with tumescent local anesthesia and powered cannulas. *Dermatol Surg.* 2009;35:41–50. discussion 50–52. [PubMed] [Google Scholar]
47. Lejour M. Vertical mammoplasty and liposuction of the breast. *Plast. Reconstr. Surg.* 1994;94:100–114. [PubMed] [Google Scholar]
48. Aiache A. Lipolysis of the female breast. In: Hetter G., editor. *Lipoplasty: the Theory and Practice of Blunt Suction Lipectomy.* Little, Brown; Boston: 1984. pp. 227–231. [Google Scholar]
49. Peled A.W., Slavin S.A., Brorson H. Long-term outcome after surgical treatment of lipedema. *Ann. Plast. Surg.* 2012;68:303–307. [PubMed] [Google Scholar]
50. Brorson H. From lymph to fat: liposuction as a treatment for complete reduction of lymphedema. *Int. J. Low. Extrem Wounds.* 2012;11:10–19. [PubMed] [Google Scholar]
51. Jensen M.R., Simonsen L., Karlsmark T. Lymphoedema of the lower extremities- background, pathophysiology and diagnostic considerations. *Clin. Physiol. Funct. Imaging.* 2010;30:389–398. [PubMed] [Google Scholar]
52. Brorson H. Surgical treatment of postmastectomy lymphedema - liposuction. In: Lee B.B., Bergan J., Rockson S.G., editors. *Lymphedema: a Concise Compendium of Theory and Practice.* Springer; London, UK: 2011. pp. 409–418. [Google Scholar]
53. Brorson H. From lymph to fat: complete reduction of lymphoedema. *Phlebology.* 2010;25:52–63. [PubMed] [Google Scholar]

54. Brorson H. Liposuction in arm lymphedema treatment. *Scand. J. Surg.* 2003;92:287–295. [PubMed] [Google Scholar]
55. Greene A.K., Slavin S.A., Borud L. Treatment of lower extremity lymphedema with suction-assisted lipectomy. *Plast. Reconstr. Surg.* 2006;118:118–121. [PubMed] [Google Scholar]
56. Dolsky R., Fetzek J. Gynecomastia: treatment by liposuction. *Am. J. Cosmet. Surg.* 1987;4:27–34. [Google Scholar]
57. Rosenberg G. Gynecomastia: suction lipectomy as a contemporary solution. *Plast. Reconstr. Surg.* 1987;8(386) 80:379-85, and discussion per Cohen I, 386. [PubMed] [Google Scholar]
58. Cigna E., Tarallo M., Fino P. Surgical correction of gynecomastia in thin patients. *Aesth. Plast. Surg.* 2011;35:439–445. [PubMed] [Google Scholar]
59. Stephan PJ, Kenkel JM. Updates and advances in liposuction. *Aesthetic Surg J.* 2010;30:83–97. [PubMed] [Google Scholar]
60. Lehnhardt M, Homann HH, Daigevlev A, Hauser J, Palka P, Steinau HU. Major and lethal complications of liposuction: A review of 72 cases in Germany between 1998 and 2002. *Plast Reconstr Surg.* 2008;121:396e–403e. [PubMed] [Google Scholar]
61. Rigel DS, Wheeland RG. Deaths related to liposuction. *N Engl J Med.* 1999;341:1001–2. [PubMed] [Google Scholar]
62. Hanke CW, Coleman WP. 3rd Morbidity and mortality related to liposuction. Questions and answers. *Dermatol Clin.* 1999;17:899–02. [PubMed] [Google Scholar]
63. <https://www.ncbi.nlm.nih.gov/pmc/articles/PMC3141144/#ref2>
64. Mantse L. Liposuction under local anaesthesia: A retrospective analysis of 100 patients. *J Dermatol Surg Oncol.* 1987;13:1333–8. [PubMed] [Google Scholar]
65. Lillis PJ. Liposuction surgery under local anaesthesia: Limited blood loss and minimal lidocaine absorption. *J Dermatol Surg Oncol.* 1988;14:1145–8. [PubMed] [Google Scholar]
66. Regatieri FL, Masquera MS. Liposuction anaesthesia techniques. *Clin Plastic Surg.* 2006;33:27–37. [PubMed] [Google Scholar]
67. MacKenzie N, Grant IS. Propofol for intravenous sedation. *Anaesthesia.* 1987;42:3–6. [PubMed] [Google Scholar]
68. Bauer KP, Dom PM, Ramirez AM, O’Flaherty JE. Preoperative intravenous midazolam: Benefits beyond anxiolysis. *J Clin Anesth.* 2004;16:177–83. [PubMed] [Google Scholar]
69. Knize DM, Fishell R. Use of preoperative subcutaneous “wetting solution” and epidural block anaesthesia for liposuction in the office- based surgical suite. *Plast Reconstr Surg.* 1997;100:1867–74. [PubMed] [Google Scholar]
70. Regatieri FL, Masquera MS. Liposuction anaesthesia techniques. *Clin Plastic Surg.* 2006;33:27–37. [PubMed] [Google Scholar]
71. Greets WH, Bergqvist D, Pineo GF, Heit JA, Samama CM, Lassen MR, et al. Prevention of venous thromboembolism: American College of Chest Physicians evidence-based practice guidelines. *Chest.* 2008;133:381s–453s. [PubMed] [Google Scholar]
72. Stephan PJ, Kenkel JM. Updates and advances in liposuction. *Aesthetic Surg J.* 2010;30:83–97. [PubMed] [Google Scholar]
73. Regatieri FL, Masquera MS. Liposuction anaesthesia techniques. *Clin Plastic Surg.* 2006;33:27–37. [PubMed] [Google Scholar]

74. <https://liposuction101.com/liposuction-textbook/chapter-28-surgical-technique-microcannular-tumescent-liposuction/>
75. R.J. Rohrich, S.J. Beran, P.B. Fodor, The role of subcutaneous infiltration in suction-assisted lipoplasty: a review, *Plast. Reconstr. Surg.* 99 (1997) 514–519 discussion 520–526.
76. A. Matarasso, Superwet anesthesia redefines large-volume liposuction, *Aesthet. Surg. J.* 17 (1997) 358–364.
77. W.P. Coleman 3rd, The history of liposuction and fat transplantation in America, *Dermatol Clin.* 17 (1999) 723–727.
78. J.A. Klein, Tumescent technique for local anesthesia improves safety in large volume liposuction, *Plast. Reconstr. Surg.* 92 (1993) 1085–1098.
79. J.A. Klein, Tumescent technique for regional anesthesia permits lidocaine doses of 35 mg/kg for liposuction, *J. Dermatol Surg. Oncol.* 16 (1990) 248–263.
80. J.A. Klein. The tumescent technique for liposuction surgery. *Am. J. Cosmet. Surg.*, 4 (1987), pp. 263–267. View article CrossRef Google Scholar.
81. A.J. Sumrall. A review of liposuction as a cosmetic surgical procedure. *J. Natl. Med. Assoc.*, 79 (1987), pp. 1275–1279. View in Scopus Google Scholar
82. <https://my.clevelandclinic.org/health/treatments/11009-liposuction>
83. <https://luxorhospital.com/types-methods-of-liposuction/>
84. <https://www.drdebello.com/procedures/body/liposuction/>
85. https://www.google.com/url?sa=i&url=https%3A%2F%2Fwww.drwilcox.com%2Fultrasonic-liposuction%2F&psig=AOvVaw1aA9xpFPI3_a0pL4aMptuJ&ust=1693315914254000&source=images&cd=vfe&opi=89978449&ved=0CBAQjRxqFwoTCJDKq767_4ADFQAAAAAdAAAAABAQ
86. <https://koelis.com/ultrasound-probes/>
87. https://www.researchgate.net/figure/A-Components-of-the-biopsy-needle-include-1-Trocar-2-Cutting-cannula-3-Clearing_fig1_221921803
88. https://www.google.com/url?sa=i&url=https%3A%2F%2Ftechnomed.net%2Fproduct%2Fultrasound-assisted-liposuction-ual-liposaver-ls-2000%2F&psig=AOvVaw1aA9xpFPI3_a0pL4aMptuJ&ust=1693315914254000&source=images&cd=vfe&opi=89978449&ved=0CBAQjRxqFwoTCJDKq767_4ADFQAAAAAdAAAAABAZ
89. https://www.google.com/url?sa=i&url=https%3A%2F%2Fwww.pixtastock.com%2Fphoto%2F79915949&psig=AOvVaw135uKI8Wfmt_1b38ZGwkay&ust=1693316479039000&source=images&cd=vfe&opi=89978449&ved=0CBAQjRxqFwoTCMIs18u9_4ADFQAAAAAdAAAAABAE
90. https://www.google.com/url?sa=i&url=https%3A%2F%2Ftechnomed.net%2Fproduct%2Fpower-assisted-liposuction-pal%2F&psig=AOvVaw0XPWLMRYVth_YVgZ1uCNcA&ust=1693316599721000&source=images&cd=vfe&opi=89978449&ved=0CBAQjRxqFwoTCPCEoYW-_4ADFQAAAAAdAAAAABAK
91. https://www.google.com/url?sa=i&url=https%3A%2F%2Ferchonia-emea.com%2Flaser-lipomachines%2F&psig=AOvVaw3VoHa2y9fi1gTbec4uodYc&ust=1693316800455000&source=images&cd=vfe&opi=89978449&ved=0CBAQjRxqFwoTCNDtoeW-_4ADFQAAAAAdAAAAABAb
92. <https://www.betterhealth.vic.gov.au/health/conditionsandtreatments/liposuction>

93. de Jong RH: 2000 Mega-dose lidocaine dangers seen in "tumescent" liposuction. *J Clin Monit Comput*, 16:17779
94. Fodor PB, Watson JP: 1999 Wetting solutions in ultrasound-assisted lipoplasty. *Clin Plast Surg*, 26:2289-293ix.
95. Rubin J, P. Bierman C, C. E. Rosow, Arthur G, R. Chang Y, Courtiss E, H. May J, W. 1999 The tumescent technique: the effect of high tissue pressure and dilute epinephrine on absorption of lidocaine. *Plast Reconstr Surg*, 103:3990-996discussion 997-1002.
96. <https://www.intechopen.com/chapters/19143>
97. <https://www.liposuction.com/complications-risks-html>
98. A. Sterodimas, F. Boriani, E. Magarakis, B. Nicaretta, L.H. Pereira, Y.G. Illouz, Thirtyfour years of liposuction: past, present and future, *Eur. Rev. Med. Pharmacol. Sci.* 16 (2012) 393–406.
99. M. Grieco, E. Grignaffini, F. Simonacci, D. Di Mascio, E. Rapisio, Post-bariatric body contouring: our experience, *Acta Biomed.* 87 (2016) 70–75.
100. E. Grignaffini, M.P. Grieco, N. Bertozzi, M. Gandolfi, D. Palli, F.G. Cinieri, M. Gardani, E. Rapisio, Post-bariatric abdominoplasty: our experience, *Acta Biomed.* 86 (2015) 278–282.
101. M. Grieco, E. Grignaffini, F. Simonacci, E. Rapisio, Analysis of complications in postbariatric abdominoplasty: our experience, *Plast. Surg. Int.* 2015 (2015) 209173.
102. M. Gardani, N. Bertozzi, M.P. Grieco, M. Pesce, F. Simonacci, P.L. Santi, E. Rapisio, Breast reconstruction with anatomical implants: a review of indications and techniques based on current literature, *Ann. Med. Surg.* 21 (2017) 96–104.
103. T.M. Abbed, R. Gonzalez-Heredia, L. Sanchez-Johnsen, E.F. Elli, M.N. Cohen, Impact of body contouring procedures on post-bariatric surgery weight loss, *Ann. Plast. Surg.* (2017).
104. F. Simonacci, N. Bertozzi, M.P. Grieco, E. Grignaffini, E. Rapisio, Autologous fat transplantation for breast reconstruction: a literature review, *Ann. Med. Surg. (Lond)* 12 (2016) 94–100.
105. E. Rapisio, N. Bertozzi, Autologous fat grafting and processing after breast re-construction, *Surg. Chron.* 22 (2017) 66–72.
106. G. Caruana, N. Bertozzi, E. Boschi, M. Pio Grieco, E. Grignaffini, E. Rapisio, Role of adipose-derived stem cells in chronic cutaneous wound healing, *Ann. Ital. Chir.* 86 (2015) 1–4.
107. J. Fan, E. Rapisio, J. Wang, R.E. Nordström, Development of the inframammary fold and ptosis in breast reconstruction with textured tissue expanders, *Aesth. Plast. Surg.* 26 (2002) 219–222.
108. E. Rapisio, S. Bonomini, F. Calderazzi, Isolation of autologous adipose tissue-derived mesenchymal stem cells for bone repair, *Orthop. Traumatol. Surg. Res.* 102 (2016) 909–912.
109. E. Rapisio, N. Bertozzi, S. Bonomini, G. Bernuzzi, A. Formentini, E. Grignaffini, M. Pio Grieco, Adipose-derived stem cells added to platelet-rich plasma for chronic skin ulcer therapy, *Wounds* 28 (2016) 126–131.
110. E. Rapisio, F. Calderazzi, Fat grafting for chronic heel pain following surgery for adult flatfoot deformity: pilot study, *Foot (Edinb)* 31 (2017) 56–60.
111. F. Simonacci, N. Bertozzi, M.P. Grieco, E. Grignaffini, E. Rapisio, Procedure, applications, and outcomes of autologous fat grafting, *Ann. Med. Surg.* 20 (2017) 49–60.
112. I. Porro, A. Schenone, M. Fato, E. Rapisio, E. Molinari, F. Beltrame, An integrated environment for plastic surgery support: building virtual patients, simulating interventions, and supporting intraoperative decisions, *Comput. Med. Imaging Graph* 29 (2005) 385–394.

- 113.N. Bertozzi, M. Pesce, P.L. Santi, E. Raposio, Oncoplastic breast surgery: comprehensive review, *Eur. Rev. Med. Pharmacol. Sci.* 21 (2017) 2572–2585.
- 114.F. Simonacci, N. Bertozzi, M.P. Grieco, E. Grignaffini, E. Raposio, Autologous fat transplantation for breast reconstruction: a literature review, *Ann. Med. Surg. (Lond)* 12 (2016) 94–100.
- 115.N. Bertozzi, F. Simonacci, M.P. Grieco, E. Grignaffini, E. Raposio, The biological and clinical basis for the use of adipose-derived stem cells in the field of wound healing, *Ann. Med. Surg.* 20 (2017) 41–48.
- 116.C. Scanarotti, A.M. Bassi, M. Catalano, C. Guida, R. Coradeghini, C. Falugi, M. Aluigi, P. Santi, E. Raposio, Neurogenic-committed human pre-adipocytes express CYP1A isoforms, *Chem. Biol. Interact.* 184 (2010) 474–483.
- 117.E. Raposio, C. Guida, I. Baldelli, F. Benvenuto, M. Curto, L. Paleari, F. Filippi, R. Fiocca, G. Robello, P.L. Santi, Characterization and induction of human pre-adipocytes, *Toxicol Vitro* 21 (2007) 330–334.
- 118.R. Coradeghini, C. Guida, C. Scanarotti, R. Sanguineti, A.M. Bassi, A. Parodi, P.L. Santi, E. Raposio, A comparative study of proliferation and hepatic differentiation of human adipose-derived stem cells, *Cells Tissues Org.* 191 (2010) 466–477.
- 119.M.G. Aluigi, R. Coradeghini, C. Guida, C. Scanarotti, A.M. Bassi, C. Falugi, P. Santi, E. Raposio, Pre-adipocytes commitment to neurogenesis 1: preliminary localization of cholinergic molecules, *Cell Biol. Int.* 33 (2009) 594–601.
- 120.E. Raposio, C. Guida, R. Coradeghini, C. Scanarotti, A. Parodi, I. Baldelli, R. Fiocca, P.L. Santi, In vitro polydeoxyribonucleotide effects on human pre-adipocytes, *Cell Prolif.* 41 (2008) 739–754.
- 121.E. Raposio, G. Caruana, M. Petrella, S. Bonomini, M.P. Grieco, A standardized method of isolating adipose-derived stem cells for clinical applications, *Ann. Plast. Surg.* 76 (2016) 124–126.
- 122.E. Raposio, G. Caruana, S. Bonomini, G. Libondi, A novel and effective strategy for the isolation of adipose-derived stem cells: minimally manipulated adipose-derived stem cells for more rapid and safe stem cell therapy, *Plast. Reconstr. Surg.* 133 (2014) 1406–1409.
- 123.E. Raposio, N. Bertozzi, Isolation of ready-to-use Adipose-derived Stem Cell (ASC) pellet for clinical applications and a comparative overview of alternate methods for ASC isolation, *Curr. Protoc. Stem Cell Biol.* 16 (41) (2017) 1F.17.1-1F.17.
- 124.E. Raposio, F. Simonacci, R.E. Perrotta, Adipose-derived stem cells: comparison between two methods of isolation for clinical applications, *Ann. Med. Surg.* 20 (2017) 87–91.