



Effects of Postoperative Zinc Supplementation on Improving the Quality of Wound Healing in Primary Colonic Anastomosis with Peritonitis Model (New Zealand Rabbit Study)

¹N Wisnu Sutarja, ²Ariandi Setiawan, ²IGB Adria Hariastawa

¹Pediatric Surgery Resident, Airlangga University – Dr. Soetomo General Hospital ²Pediatric Surgeon – Lecturer, Airlangga University – Dr. Soetomo General Hospital

Abstract: Background and Aims: Colon have highest prevalence for leakage anastomosis (40%), in intraabdominal infection this risk of leakage will increase 2.5 times. For prevent leakage, there should be modality to support wound healing in anastomosis. Zinc is a drug which is cheap and easy to get. This mineral has multiple function in reducing morbidity and mortality from sepsis, it also has beneficial in wound healing of colonic anastomosis. We have investigated the effect of daily oral zinc supplementation on the rabbit's colon anastomosis with peritonitis.

Materials and methods: 36 male *New Zealand* rabbits (median 2.5 kg) were induced for peritonitis, 6 hours after induction we do peritoneal lavage and colonic anastomotic. After that divide 2 groups, 1st group (intervention) was given Zinc syrup everyday and 2nd group (control) was given normal saline (without Zinc). In the 6th days, we terminate the rabbit and examine for histological score of anastomotic in colon (Collagen density, neovascularization, and inflammation)

Results: 4 Rabbits was *drop out*. The remaining 32 sample divided into 2 groups where in each group was 16 sample. There is significant difference between rabbits with zinc supplementation (n = 16) and without zinc supplementation (n = 16). Histological score in intervention group has better result in healing process of anastomotic than control group (Collagen density p = 0.24, $\alpha < 0.05$; Neovascularisation p = 0.34, $\alpha < 0.05$; Inflammation, p = 0.43, $\alpha < 0.05$). The score variation which is not linear as theory could be caused by other wound healing factors.

Conclusion and Suggestion: There is significant difference in histologic healing score (collagen density, neovascularization, inflammation) between subject with zinc supplementation and without zinc supplementation. There should be another study to examine the effective dosage, subject weight, and rute of zinc supplementation.

Keywords: Colon, Anastomotic, Peritonitis, Zinc

I. INTRODUCTION

Anastomotic leaks in the intestine are still causing high rates of morbidity and mortality in patients. Morbidity and mortality rates in patients with leaky colonic anastomoses alone range from 7-39%¹. In addition to the high rate of patient morbidity, a study by Hammond during 2008 to 2010 in the United States showed anastomotic leaks that increased financial expenses up to 2.5 times compared to no leakage. This makes it difficult for both the patient and the hospital². Of the various types of bowel that were anastomotic, the colon had the highest prevalence of anastomotic leakage at 40%, followed by gastroduodenal anastomotic leak in the second place at 32%³. Anastomotic leaks can be influenced by various factors, both local and systemic. One example of systemic factors that influence this is the condition of peritonitis. In patients with peritonitis who underwent anastomotic resection of the colon, the leakage rate was increased to 2.5 times. This is because peritonitis causes disruption of the wound healing process both locally and systemically. In the evaluation of intestinal anastomotic wound healing, the investigators used histopathological scores. This score is a semiquantitative method used to assess wound healing, which consists of collagen density, neovascularization, and inflammation (neutrophil infiltration). This causes a decrease in the amount of zinc in the periphery associated with impaired wound healing in the colon. Various innovations and therapies have been carried out to minimize the incidence of anastomotic leakage, one of which is the use of zinc (Zn) mineral components which play a role in increasing wound healing ability⁷. Zn is a material that is cheap and easily available around us. This substance has various functions in collagen metabolism and has recently been found to be beneficial in the healing of colonic anastomoses⁸. This mineral also contributes as a wound healing coordinator, especially in its role in platelet formation and hemostasis, inflammation and immunity, granulation and re-epithelization, and regulation of Matrix Metallo Proteinase (MMP)^{7,9}. Zinc as a cofactor of superoxide dismutase also has a role as an antioxidant, anti-inflammatory, and regulation of apoptosis. This enzyme can reduce the production of free radicals so that it plays a role in the balance of oxidants and antioxidants and prevents oxidative stress that can cause cell death. In addition to its role in wound healing, zinc is also beneficial in reducing morbidity and mortality in patients with sepsis through regulation of cytokines. Zinc has been shown to decrease proinflammatory cytokine levels and increase anti-inflammatory cytokines in patients with sepsis¹⁰.

II. Material and Methods

A total of 36 male Newzealand white rabbits aged 6-9 months with a weight of 2-3 kilograms were randomized into two treatments with 18 rabbits each, then adapted for seven days. Each rabbit was placed in a separate cage, with a 12/12 hour lighting cycle. Feeding and drinking during the adaptation period and ad libitum treatment.

After being adapted for seven days, the rabbits were made peritonitis by introducing 10% autologous feces solution, ie 2 grams of feces collected from each rabbit and dissolved in 20 ml of 0.9% NaCl, an amount of 4 ml/kgBW into the intra-abdominal cavity. After 6 hours from the injection, a laparotomy was performed under general anesthesia using ketamine 20-40 mg/kg body weight intramuscularly. During the induction of anesthesia, the therapeutic antibiotics Ceftriaxone 25 mg/kgBW and Metronidazole 10 mg/kgBW were also given¹. Each rabbit was shaved on the stomach, then disinfected with 10% povidone iodine and the operating field was narrowed with a sterile drape. A longitudinal longitudinal incision in the midline of the abdomen is 4 centimeters long, deepened to reach the peritoneum. Then the abdominal cavity was washed with a 0.9% NaCl solution of 300 ml/kgBW until clean. The Colon was cut and then we do end to end anastomosis with simple interrupted suture methode using non absorbable suture material (*silkam*®). The laparotomy wound is then sutured. The layers of the peritoneum, fascia, and muscle were sutured simply with absorbable multifilament sutures (Polyglycolic Acid 4.0), while the skin was sutured continuously with non-absorbable monifalmen (Nylon 4.0) and the wound was closed with gauze.

Postoperatively, all rabbits were given a combination of advanced therapeutic antibiotics Ceftriaxone 25 mg/kgBW every 12 hours and Metronidazole 10 mg/kgBW every 8 hours, as well as analgesic Paracetamol at a dose of 10 mg/kgBW every 8 hours. Daily zinc supplementation was given to the treatment group at a dose of 10 mg/kgBW/day started after surgery and continued for 5 days. The rabbits were observed on day 6, at which time the rabbits were terminated to take the anastomotic tissue from the colon. Collagen, Neovascularisation, and Inflammation was obtained by anastomotic tissue margin biopsy (± 1 cm) on the 6th day. Histopathological examination was performed on the submucosal layer of the mesenteric side. Collagen, Neovascularisation, and Inflammation was examined and the density score was measured at the wound edges with a light microscope with 100x magnification. The location for observing the collagen, neovascularisation, and inflammation is in the area of the incision scar. Furthermore, the it's density is interpreted semiquantitativel. If the rabbit dies before 6 days, it is considered a drop out.

The slide was read and evaluate for collagen, neovascularization, and inflammation using histopathological scoring by Novriansyah for Collagen¹ and Khotiya for Neovascularisation and inflammation² as we can see in tabel 2.1. and 2.2.

Tabel 2.1. Scoring for Collagen¹

Score	Collagen
0	< 10%
1	<10-25%
2	25 – 50%
3	50 – 75%
4	>75%

Tabel 2.1 Scoring for Inflammation and Neovascularisation²

Score	Inflammation (Neutrofil Infiltration),%	Neovascularisation
0	-	None
1	< 25%	Moderate
2	25 – 50%	Severe
3	50 – 75%	
4	>75%	

Comparisons between treatment and control group specimens were performed using the Mann-Whitney U non-parametric test. All statistical analyses were carried out using the SPSS version 25.0 data analysis system. p-Values < 0.05 were considered to be statistically significant for all comparisons

III. RESULTS AND DISCUSSION

Four rabbits were dropped out because of death. Two rabbits, each from control and treatment group, died at three hours and four hours after peritonitis induction (before laparotomy). A rabbit from the control group died on the second post-operative day and a rabbit from the treatment group died on the fourth post-operative day. All rabbits that died after the procedure were evaluated for their intra-abdominal conditions and all of them found that their gastrointestinal organs were intact, no pus, and there were no leakage of anastomosis. Their deaths were probably due to sepsis as a result of peritonitis. On the 6th post-operative day, specimens were harvested from the colon anastomosis and sent for histopathological examination.

Of all rabbits, in the control and treatment groups, the weight range was between 2100-3100 grams with an average weight of the control group 2500+278.01 grams and the zinc group 2487.50+305.23 grams. Based on statistical calculations, it was found that the distribution of weight data was normally distributed, and the homogeneity test of the subjects with the parametric T-Test test of two independent samples obtained p value = 0.904 and = 0.05. While the age range in this study was 6-9 months with an average age of the control group 7.13 1.09 months and the zinc group 6.94+1.06 months. From the results of the normality test, it was found that the age distribution in this study was not normally distributed, and the results of the homogeneity test with the Mann-Whitney U non-parametric test obtained p values = 0.606 and = 0.05. Based on statistical calculations of the two groups, there were no significant differences in weight and age (table 3.1).

Tabel 3.1. Statistic of Sample Age and Body Weight

Demography		Control	Treatment	p-value
Age (month)	Range	6 – 9	6 – 9	0,606
	Mean ± SD	7,13 ± 1,08	6,94 ± 1,06	
Body Weight (gram)	Range	2100 – 3100	2100 – 3100	0,904
	Mean ± SD	2500 ± 278,08	2487,50 ± 305,23	

3.1 Analysis of Collagen Score in Zinc Group Compared to Control

From 32 samples, collagen density was examined and scored 0 to 4 with a score of 0 indicating low collagen density to 4 with very dense collagen density. It is known that there is a dominant score distribution on scores of 2 (43.75%) and 3 (37.5%) for the treatment group (with zinc) and the dominance of scores 1 (25%) and 2 (37.5%) for the control group (without zinc) (tabel 3.2). The median value of this distribution of collagen scores was 2.0 with a standard deviation (SD) of 0.806 (2.0 ± 0.885) in the treatment group, and 0.885 in the control group (2.0 ± 0.885) as we can see in tabel 3.2 and figure 3.1. From the results of the Mann-Whitney difference test, there was a significant difference in collagen density between the group with Zinc compared to the group without Zinc with $p=0.024$ ($\alpha=0.05$)

Tabel 3.2. Distribution data of Collagen Score

Score	Treatment (Sample)	Control (Sample)
0	0 (0%)	2 (12.5%)
1	2 (12.5%)	4 (25%)
2	7 (43.75%)	8 (37.5%)
3	6 (37.5%)	2 (12.5%)
4	1 (6.25%)	0 (0%)

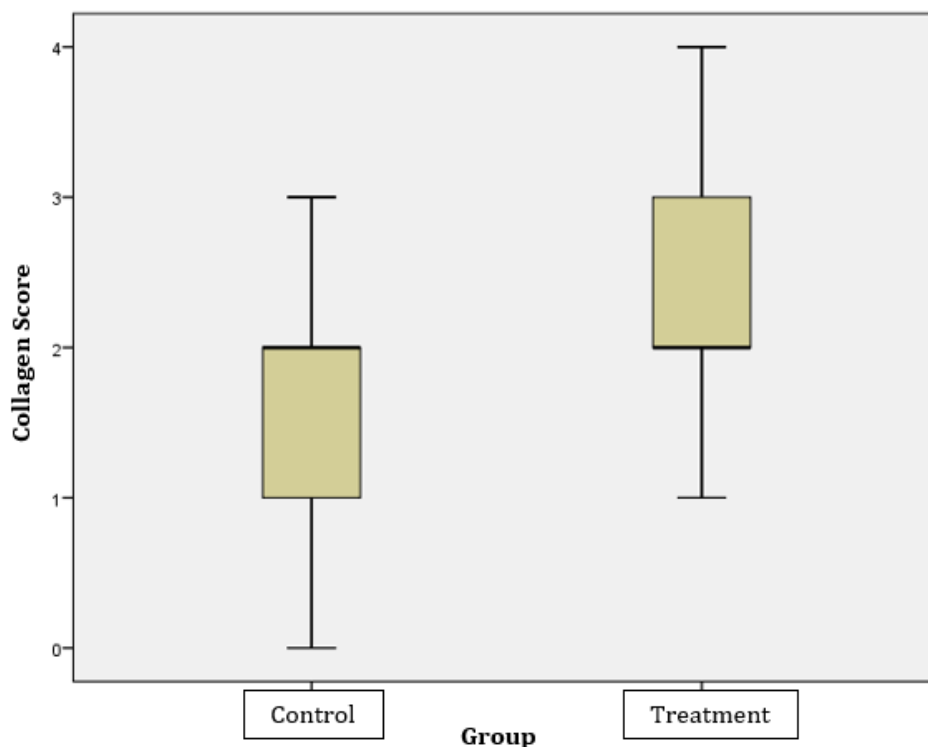


Figure 3.1. Barr Graph Collagen Distribution Score

3.2 Analysis of Neovascularisation Score in Zinc Group Compared to Control

From 32 samples, the study was examined for neovascularization and scored 0 to 2 with a score of 0 indicating the least neovascularization to 2 with the most neovascularization. It is known that there is a dominance of the same 1 score (57.25%) in both treatment and control groups (tabel 3.3). The median value for this neovascularization score was 1 in both the treatment and control groups, with an SD in the treatment group of 0.602 and an SD of 0.655 in the control group as we can see in tabel 3.5 and figure 3.2. From the results of the Mann-Whitney difference test, there was a significant difference in neovascularization between the group with Zinc compared to the group without Zinc with $p=0.035$ ($\alpha=0.05$)

Tabel 3.3. Distribution data for Neovascularisation Score

Score	Treatment	Sample
0	1 (6.25%)	5 (31.25%)
1	9 (57.25%)	9 (57.25%)
2	6 (37.5%)	2 (12.5%)

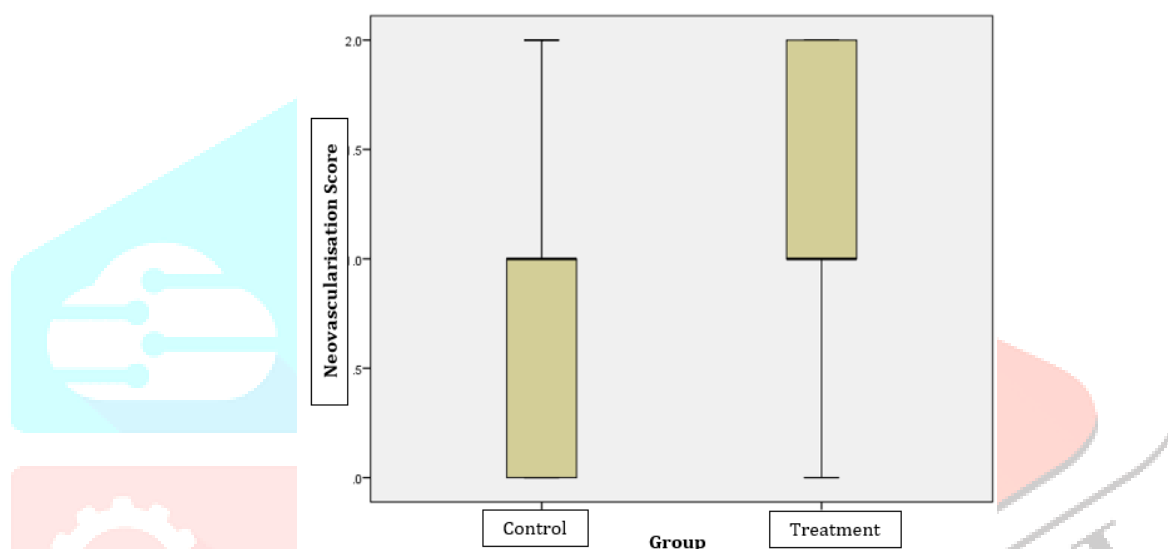


Figure 3.2. Barr Graph Neovascularisation Distribution Score

3.3 Analysis of Inflammation Score in Zinc Group Compared to Control

From the 32 research subject data, the amount of inflammation in the visual field was examined and a score of 0 to 4 was carried out with a score of 0 indicating slight inflammation to 4 with a lot of inflammation. It is known that there is a dominance of the distribution of inflammation scores at scores of 2 (50%) and 3 (37.5%) for the treatment group (with zinc) and the dominance of scores 1 (25%) and 2 (50%) for the control group (without zinc)(Tabel 3.4). The median value for this neovascularization score was 2.0 in both the treatment and control groups, with SD in the treatment group 0.727 and SD in the control group 0.719 as we can see in tabel 3.5 and figure 3.3. From the results of the Mann-Whitney difference test, there was a significant difference in inflammation scores between the group with Zinc compared to the group without Zinc with $p = 0.043$ ($\alpha=0.05$)

Tabel 3.4. Distribution data of Inflammation Score

Inflammation Score	Treatment (Sample)	Control (Sample)
0	0 (0%)	0 (0%)
1	1 (6.25%)	4 (25%)
2	8 (50%)	8 (50%)
3	6 (37.5%)	3 (18.75%)
4	1 (6.25%)	0 (0%)

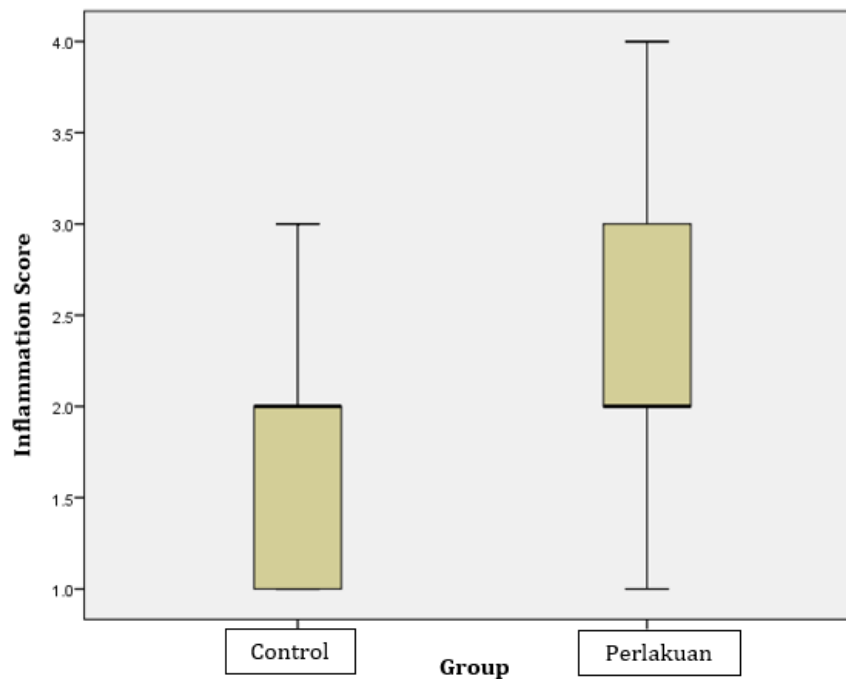


Figure 3.3. Barr Graph Inflammation Distribution Score

Tabel 3.2. Table of Wound Healing Histological Distribution

Anastomotic Healing		Control	Treatment
Collagen	Range	3	3
	Median \pm SD	2.00 \pm 0.885	2.00 \pm 0.806
Neovascularisation	Range	2	2
	Median \pm SD	1 \pm 0.655	1 \pm 0.602
Acute Inflammation	Range	2	3
	Median \pm SD	2 \pm 0.719	2 \pm 0.727

IV. Discussion

Peritonitis is a known cause of anastomotic dehiscence in the colon, yet the mechanism by which this occurs is not fully understood². In the process of wound healing, macronutrients and micronutrients are needed in sufficient quantities to prevent disruption of the wound healing process³. The micronutrient needed in almost every stage of wound healing is zinc⁴. In the hemostasis phase, zinc plays a role in increasing platelet activity and aggregation which is regulated through Protein kinase C-mediated phosphorylation of platelet protein tyrosine^{5,6}. In the inflammatory phase, zinc plays a role in the recruitment and activation of non-specific immune cells to the wound site by inducing the release of alpha-granule platelets which contain a number of pro-inflammatory enzymes so as to initiate the inflammatory phase of wound healing⁶. Zinc also affects the activity of several nonspecific immune cells such as neutrophils, monocytes, macrophages, in the process of eliminating bacteria and damaged tissue, cytotoxicity, and apoptosis.

The adaptive immune system that participates in the wound healing process is also influenced by zinc. In the proliferative phase, zinc plays a role in the migration of fibroblasts and keratinocytes to the wound tissue and increases angiogenesis and stem cell activation. In the remodeling phase, zinc plays a role in extracellular matrix remodeling and scar tissue formation⁴. Septic conditions, such as in patients with peritonitis, are known to reduce serum zinc levels by redistributing zinc into the liver⁷. While increasing the need for zinc in the peritoneum⁸. While in wound healing the need for zinc in the peripheral wound edges increases⁴. The relative condition of peripheral zinc deficiency in this condition of peritonitis can interfere with the wound healing process⁹. From previous studies, zinc supplementation in experimental animals with zinc deficiency can accelerate the wound healing process¹⁰. Zinc also have significant effect on decreased mortality effect in sepsis¹¹.

Oral zinc preparations were preferred over intravenous considering the drug availability, oral zinc could be found in many place. Although the subjects in the study were in peritonitis conditions, the systemic zinc administrations were expected to improve the overall condition of the subjects simultaneously. Although the toxicity of zinc is said to be quite low, from a study it is known that the effect of zinc supplementation depends on the dose of zinc given. Doses above 30 mg/kgBW were said to have a pro-inflammatory effect¹². It could prolong wound healing. In this study, we used a dose of 10 mg/kgBW to avoid the proinflammatory effect of zinc.⁶

In this study, a peritonitis model was used in rabbits that were given zinc supplementation in the treatment group and then performed a comparative analysis of the incidence of wound dehiscence. Four rabbits died in this study. From the examination of the rabbits that died after laparotomy, there was no intestinal perforation in the abdominal cavity. So that the death of the rabbits was most likely due to the sepsis condition they experienced.

There was significant difference in the colon anastomosis histopathological distribution scoring of collagen, neovascularisation, and inflammation from 16 sample in each group. From previous studies⁵, zinc was found to play a role in helping wound healing. In that study, zinc was thought to act as a cofactor in activating anti-inflammatory enzymes so as to help wound healing. Our study can demonstrate the role of zinc in higher score of collagen and neovascularisation where it means better

healing. In the theory, Zinc played a role in higher inflammation response in inflammation phase and also reducing proinflammatory after that, but in our case there is significant higher inflammation in the 6th day. This could be because other factor influencing the inflammation or the abundance of inflammation in inflammation phase were it had not yet reduce well in 6th day. Unfortunately, we didn't do research of histopathological scoring of the inflammation phase to prove it. Zinc played a role in wound healing, but in a smaller portion, as a cofactor. To better understand the role of zinc in wound healing, further research needed.

II. ACKNOWLEDGMENT

REFERENCES

1. Badea I, Santini A. Abdominal Sepsis : An Update. 2018;4(4):120–5.
2. Kothiya PK, Sharma DB, Solanki FS, Tiwari AK, S. K. C. Effect of Vitamin C Supplementation on Colonic Anastomotic Healing in the Presence of Peritonitis- An Experimental Study in Rats. *J Evol Med Dent Sci.* 2020;9(23):1730–3.
3. Ågren MS, Andersen L, Heegaard AM, Jorgensen LN. Effect of parenteral zinc sulfate on colon anastomosis repair in the rat. *Int J Colorectal Dis.* 2008;23(9):857–61.
4. Lin PH, Sermersheim M, Li H, Lee PHU, Steinberg SM, Ma J. Zinc in wound healing modulation. *Nutrients.* 2018;10(1):1–20.
5. Lansdown ABG, Mirastschijski U, Stubbs N, Scanlon E, Ågren MS. Zinc in wound healing: Theoretical, experimental, and clinical aspects. *Wound Repair Regen.* 2007;15(1):2–16.
6. Taylor KA, Pugh N. The contribution of zinc to platelet behaviour during haemostasis and thrombosis. *Metallomics.* 2016;8(2):144–55.
7. Alker W, Haase H. Zinc and sepsis. *Nutrients.* 2018;10(8):1–17.
8. Kudrin A V. Trace element levels in the experimental peritonitis. *J Trace Elem Exp Med.* 2002;15(2):79–84.
9. Binnebösel M, Grommes J, Koenen B, Junge K, Klink CD, Stumpf M, et al. Zinc deficiency impairs wound healing of colon anastomosis in rats. *Int J Colorectal Dis.* 2010;25(2):251–7.
10. Bradbury S. Wound healing : is oral zinc supplementation beneficial ? 2006;2(1):4–8.
11. Utomo MT. During study , two rodents were dead in LPS group at the 8 th and 24 th hour . In this study the minimal sample for each group was 5 and duplicated to 10 , because there was blood collection more than 2 times in 24 hours . Sample characteristics between g. :46–50.
12. Braunschweig CL, Sowers M, Kovacevich DS, Hill GM, August DA. Parenteral zinc supplementation in adult humans during the acute phase response increases the febrile response. *J Nutr.* 1997;127(1):70–4.

