



The Reconstruction of Mandible Defect with Pectoralis Major Osteomyocutaneous Flap in Ameloblastoma Patient

¹Fahriansyah Mega Pratama, ²Nina Irawati, ²Marjono Dwi Wibowo

¹Department of Surgery, Faculty of Medicine Universitas Airlangga/ Dr. Soetomo General Hospital, Surabaya, Indonesia

²Division of Head and Neck Surgery, Department of Surgery, Faculty of Medicine Universitas Airlangga/ Dr. Soetomo General Hospital, Surabaya, Indonesia

Abstract: The mandible defect reconstruction aims to maintain the function of the mandible as well as preserving the cosmetic aspects of mandible. A well-functioned mandible is the main goal in mandible reconstruction surgery. In this study, we described the use of pectoralis major myocutaneous flap incorporating the sixth rib for mandibular reconstruction surgery in patients with ameloblastoma following the complication of plate exposure six months after previous reconstruction surgery. The rib was used to replace the amputated bone structure and prevent collapse of the mandible's structure, while the pectoralis major myocutaneous flap was used to close the defect and replace the soft tissue. This procedure has advantage in single stage without changing patient position during surgery. In this study, the pectoralis major osteomyocutaneous flap established the patient's functional and aesthetic aspects. This reconstruction method can also be a choice in the era of microvascular surgery.

Keyword: ameloblastoma, mandibula resection, pectoralis major osteomyocutaneous flap

Introduction

Ameloblastoma is a locally invasive odontogenic neoplasm arising in the jaw. Ameloblastoma is a benign tumor develops from dental lamina cells and usually unicentric. The incidence is reported to be 0.92 cases per 1,000,000 population with equal prevalence between male and female [1]. The most common predilection is in the posterior mandible area. Currently, there are several treatment options for ameloblastoma, including surgical management and conservative treatment such as bone curettage, decompression and enucleation [2,3]. Surgical resection is the main modality of therapy for ameloblastoma. Mandibular resection is one of the modalities used to treat ameloblastoma [4].

Mandibular resection is a part of the surgical operations for ameloblastoma case. However, mandibular resection results in large facial defect and significant alteration in function. Therefore, the reconstruction of the mandibular defect aims to maintain the function of the mandible while preserving a good cosmetic appearance. A good functional status of the mandible is something that must be taken into consideration in mandibular reconstruction related to the selection of materials to be used [5].

Mandibular reconstruction should not only result in good aesthetics and structural integrity but also restores the functional ability to chew, speak and swallow. There are several ways to reconstruct the mandible defect including the use of a reconstruction plate and autogenous bone graft, either vascularized or non-vascularized as well as the use of a flap [6]. In this case report, we present a case of ameloblastoma patient underwent mandibular reconstruction with a pectoralis major osteomyocutaneous flap. This method was used to reconstruct a LC-type defect involving extensive soft tissue and bone defects resulting from ameloblastoma mandibular resection. This reconstruction method was chosen due to the failure of the previous reconstruction and as an alternative to reconstruction using the free flap.

Case Presentation

18 years old male patient complained of a lump in his right lower jaw since approximately 5 years ago (Figure 1). The lump was getting bigger slowly. The patient did not complain of pain at the location of the lump. The patient complains of difficulty opening the mouth and chewing. The patient also felt uncomfortable cosmetically. The patient did not experience weight loss. From physical examination, the mass was located on the right mandible. The mass was fragile and there was no pain in the mass. The panoramic photo is shown in Figure 2. The panoramic radiograph showed an expansive lytic lesion that formed a soap bubble appearance in the right mandible from the angle to the left mandibular parasymphiseal. Radiologic examination showed typical features of ameloblastoma.

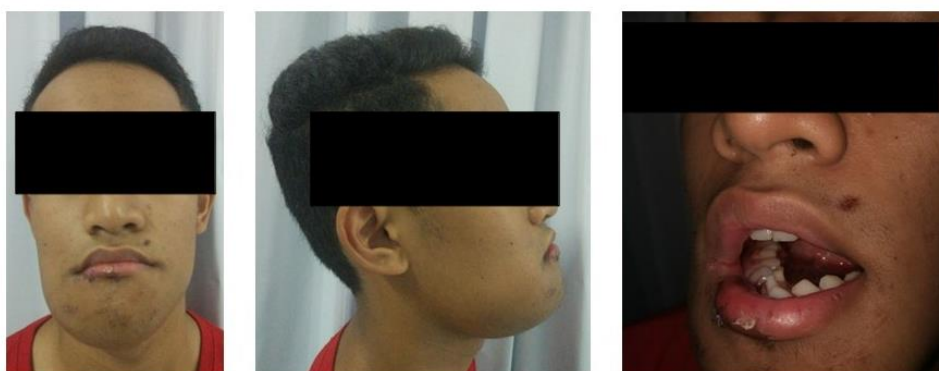

Figure 1. Clinical condition of the patient

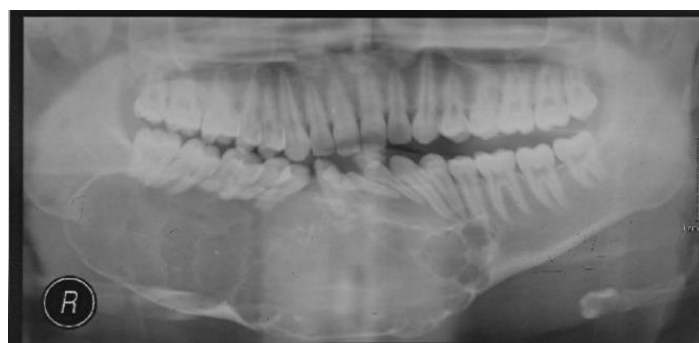

Figure 2. Panoramic X-ray showed lytic lesion of Ameloblastoma

The patient underwent the first surgery in October 2018. In this operation, a mass of the mandible was resected from the right angle of the mandible to part of the left mandibular parasymphiseal (Figure 3). On histopathological examination, it was concluded that it was an ameloblastoma, plexiform type. This procedure left a LC-type defect on the mandible. Therefore, mandible reconstruction using plates was performed.

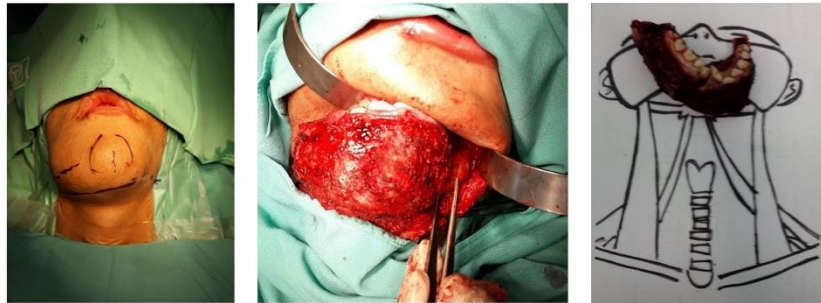

Figure 3. Specimen and finding during the first surgery

Six months of postoperative, the patient complained that the plate was felt in the patient's mouth. Based on physical examination, an exposed plate was found on the mucosal side, then the plate was removed without reconstruction. The patient came back four months after the removal of the plate complaining of cosmetic problems, difficulty eating, talking, and closing his mouth. Physical examination of the patient showed asymmetrical mandible with mandibular defect to the left side (Figure 4).

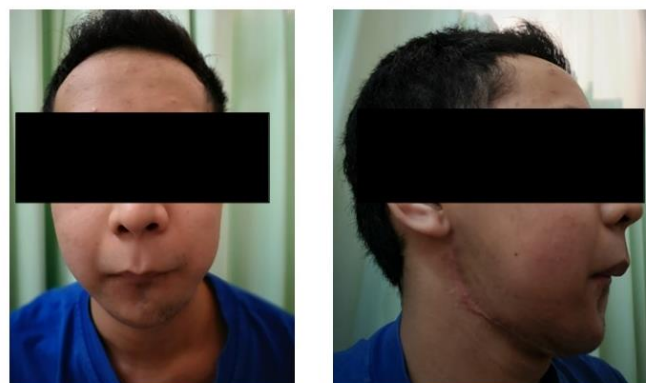

Figure 4. Clinical condition after plate removal

A 3D reconstruction CT scan was done and the results showed an amputated lesion in the right angle of the mandible to part of the left mandibular body (Figure 5). Another reconstruction surgery was planned to regain the functional aspect of this patient.

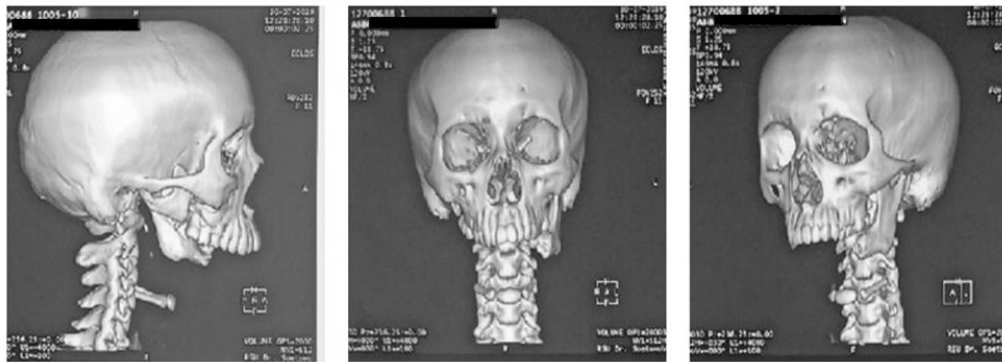

Figure 5. 3D Reconstruction CT scan of the patient

The patient underwent reconstruction surgery in August 2019. The reconstruction carried out by closing the defect using a pectoralis major osteomyocutaneous flap. The resected mandibular bone structure was replaced with patient's 6th rib and the soft tissue structure was reconstructed using a pectoralis major myocutaneous flap. The incision design is depicted in Figure 6.

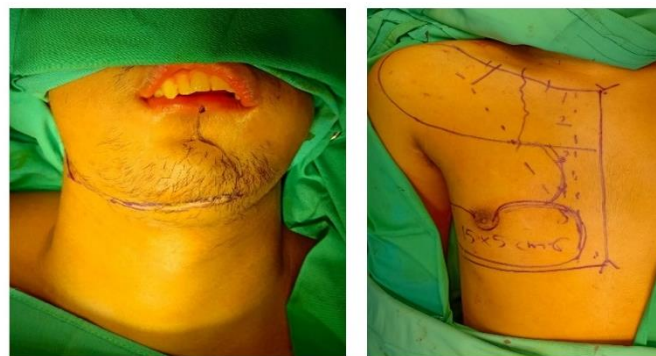

Figure 6. Incision in pectoralis major osteomyocutaneous flap reconstruction An incision according to the design of the pectoralis major osteomyocutaneous flap was done, harvesting of pectoralis major osteomyocutaneous flap accompanied by removal of the 6th rib with preservation of the right thoracoacromial and periosteal veins (Figure 7)

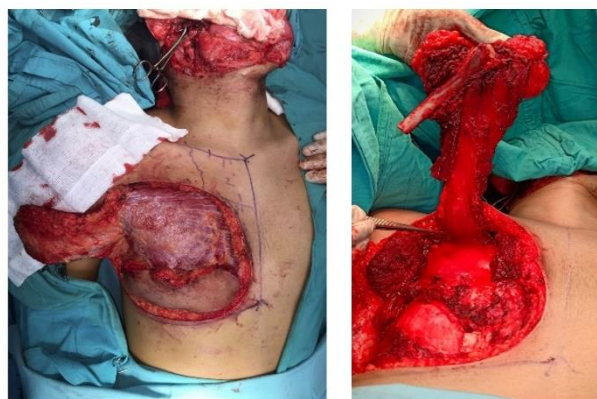

Figure 7. Harvesting pectoralis major osteomyocutaneous flap

In the existing mandibular defect, a plate with no. 8 and 12 screw was installed then the rib cortex was split and attached to the plate with screw no. 8. The existing pectoralis major myocutaneous flap was used to

close the side defect of the buccal mucosa through rotation and tunneling flap techniques on the clavicular (Figure 8). After that, the redon drain was installed in the neck and right thoracic area.

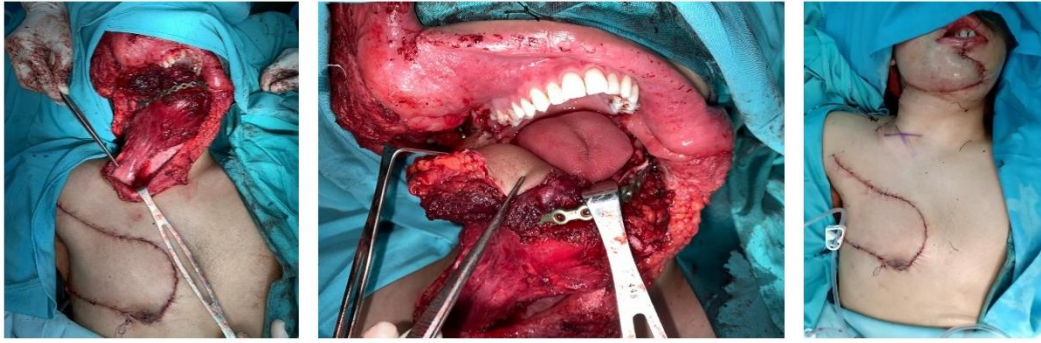


Figure 8. Defect closure with plate and pectoralis major osteomyocutaneous flap

After undergoing the second reconstructive surgery procedure, the patient was evaluated clinically and then discharged without any complaints. At the next follow up, the patient was able to open his mouth, chew and speak well. The patient is satisfied with the reconstruction that has been done with adequate cosmetic result (Figure 9).

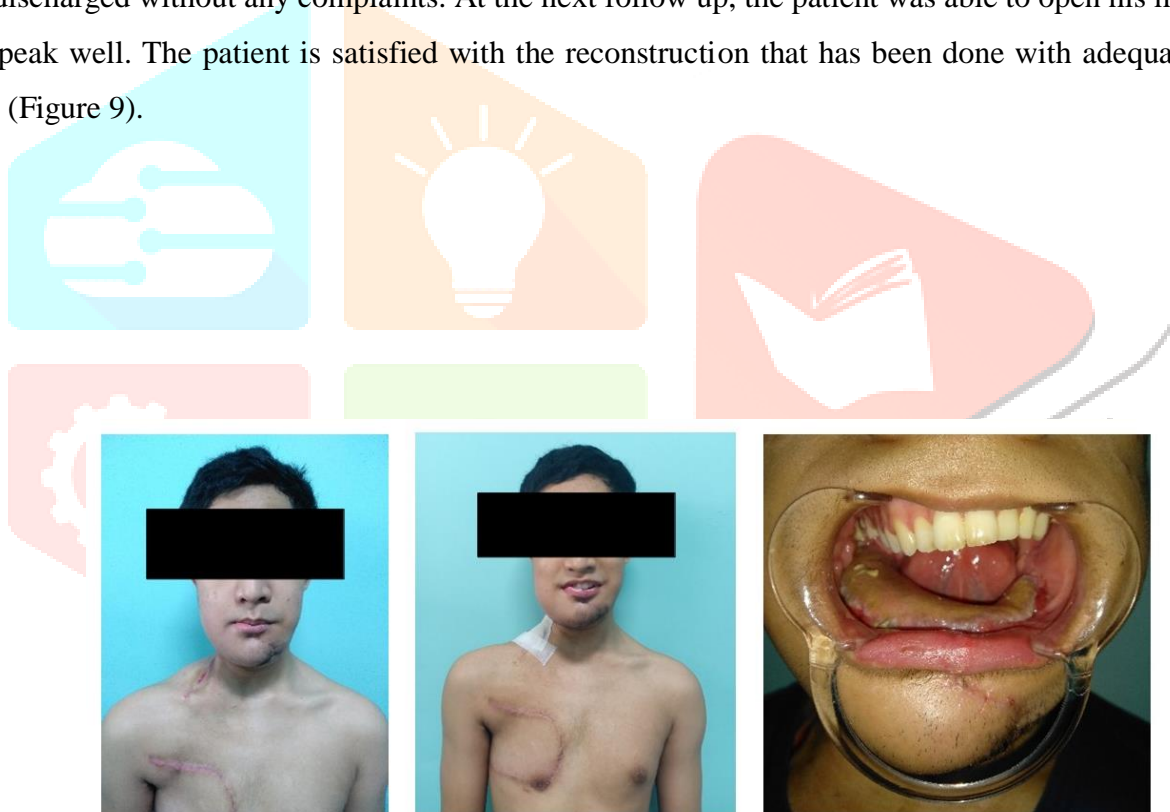

Figure 9. Clinical condition at first follow-up after reconstruction with plate and pectoralis major osteomyocutaneous flap

A follow up examination was also performed in the form of a panoramic examination and skull AP view at 1 month after surgery (Figure 10). From the results of the examination, we found that the bone graft is attached to the right angle of the mandible to the left side which is fixed by internal fixation in a good position and accompanied by callus formation.

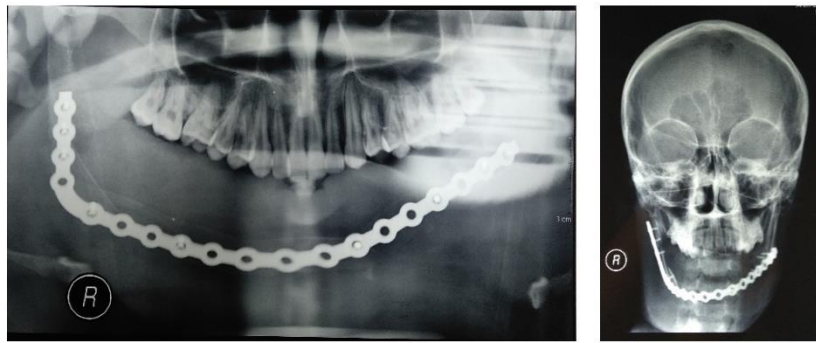


Figure 10. Panoramic X-ray (left) and Skull AP view (right) 1 month after surgery

Discussion

Ameloblastoma is a type of odontogenic epithelial neoplasm that develops from undifferentiated enamel tissue [7]. Mandibular resection is one of the treatment options because ameloblastoma is mostly found in the mandible. The goal of mandibular defect reconstruction is to keep the mandible functional while maintaining the mandible's cosmetic appearance. A good functional status of the mandible is something that must be considered when carrying out mandibular reconstruction in terms of material selection. Following mandibular resection, mandibular reconstruction is required. The mandible helps to maintain the shape of the face. Furthermore, the mandible aids in the maintenance of the airway as well as the support of the tongue, muscles, and teeth. Reconstruction required not only the repair of the bone, but also the complete restoration of mastication, speech, and oral movement function.

In this case report, we used a pectoralis major osteomyocutaneous flap. This approach was chosen because in this case segmental resection of the mandible was performed with a LC-type mandibular defect and involving extensive soft tissue and bone defects. Pectoralis major osteomyocutaneous flap has strong pedicles with persistent anatomy. Harvesting pectoralis major osteomyocutaneous flap does not require changing the patient's position. One flap can reconstruct both bone and soft tissue at the same time. The pectoralis major osteomyocutaneous flap has bulky muscles and extensive skin pedicles that can replace soft tissue defects in the floor of mouth, so that Andy Gump syndrome can be corrected. The use of pectoralis major myocutaneous flap has been acknowledged as one of standard procedure for various head and neck surgery [8]. The variants of the pectoralis major flap that included the use of bone has been reported to be a potential approach for mandibular reconstructions. In the osteomyocutaneous flap, several bone parts such as rib bone and segment of sternum has been used for zygoma, mandibular or temporomandibular joint reconstruction [9].

In this study, reconstruction surgery was indicated due to the complication of previous mandibular reconstruction using plate. Plate is indicated especially for defects in the lateral segment of mandible. However, the disadvantage of the plate method is that common complications such as extrusion, plate fracture, screw fracture and exposure of the plate may occur [10]. There are several factors that may lead to exposure complication, such as thin soft tissue on the plate surface, dead space beneath the plate and dead space due to plate displacement and surrounding tissue. In addition, previous study also suggested to consider the mechanical stress on the plate to prevent the occurrence of plate fracture [11].

In this study, the reconstruction using plate was combined with pectoralis major osteomyocutaneous flap in order to reduce the complications that occurred in the form of exposure to the subsequent reconstruction surgery. The sixth rib bone was used for pectoralis major osteomyocutaneous flap. The use of this method for segmental mandibular reconstruction has the advantage that the pectoralis major osteomyocutaneous flap provides lining to the mucosal impact for a successful flap, adequate blood supply, supports from the rib, minimal donor site morbidity and good cosmetics like micro flap [12]. The use of muscle tissue in mandibular reconstruction is due to the fact that muscle tissue is considered very resistant to infection and the pressure exerted by the plate. The pectoralis major myocutaneous flap combines the advantages of a simple technique and procedure, with minimal morbidity. In addition, previous study also reported that pectoralis major rib osteomyocutaneous flap was a good choice of methods for mandibular reconstruction due to less morbidity, good cosmetic and functional outcome [5]. Technically, this method does not require the involvement of microvascular surgery and can be performed in relatively short duration procedure. Therefore, this reconstruction procedure can also be an option in the current era of microsurgery.

Conclusion

The pectoralis major osteo-myocutaneous flap is one of the best flap options for mandibular reconstruction surgery. The main advantage of this flap is that the flap is carried out in one step, the patient's position does not need to be changed during the procedure, flexibility, reliability, ease of use and multiple pieces of skin can be collected together to cover large defects. Reconstruction of the mandibular defect with a pectoralis major osteomyocutaneous flap in the case of ameloblastoma provides good aesthetic and functional results. The reconstruction can also be an option in the current era of microsurgery.

Conflicts of interest

No competing interests declared.

Funding

This research received no specific grant from any funding agency.

Authors' Contribution

F.M.P. conceptualized, interpreted, and wrote the manuscript. M.D.W., and N.I. reviewed the manuscript, supervised the study, and involved in the case management. F.M.P. reviewed and revised the manuscript. All authors read and agreed to published version of the manuscript.

References

1. Hendra FN, Van Cann EM, Helder MN, Ruslin M, de Visscher JG, et al. (2020) Global incidence and profile of ameloblastoma: A systematic review and meta-analysis. *Oral Dis* 26: 12-21.
2. Dandriyal R, Gupta A, Pant S, Baweja HH (2011) Surgical management of ameloblastoma: Conservative or radical approach. *Natl J Maxillofac Surg* 2: 22-27.
3. Kim SW, Jee YJ, Lee DW, Kim HK (2018) Conservative surgical treatment for ameloblastoma: a report of three cases. *J Korean Assoc Oral Maxillofac Surg* 44: 242-247.
4. Sarlabous M, Psutka DJ (2018) Treatment of Mandibular Ameloblastoma Involving the Mandibular Condyle: Resection and Concomitant Reconstruction With a Custom Hybrid Total Joint Prosthesis and Iliac Bone Graft. *J Craniofac Surg* 29: e307-e314.
5. Gadre KS, Gadre P, Sane VD, Halli R, Doshi P, et al. (2013) Pectoralis major myocutaneous flap--still a workhorse for maxillofacial reconstruction in developing countries. *J Oral Maxillofac Surg* 71: 2005.e2001-2005.e2010.
6. Funayama A, Kojima T, Yoshizawa M, Mikami T, Kanemaru S, et al. (2017) A simple technique for repositioning of the mandible by a surgical guide prepared using a three-dimensional model after segmental mandibulectomy. *Maxillofac Plast Reconstr Surg* 39: 16.
7. Masthan KM, Anitha N, Krupaa J, Manikkam S (2015) Ameloblastoma. *J Pharm Bioallied Sci* 7: S167-170.
8. Bussu F, Gallus R, Navach V, Bruschini R, Tagliabue M, et al. (2014) Contemporary role of pectoralis major regional flaps in head and neck surgery. *Acta Otorhinolaryngol Ital* 34: 327-341.
9. Jones NF, Sommerlad BC (1983) Reconstruction of the zygoma, temporo-mandibular joint and mandible using a compound pectoralis major osteo-muscular flap. *Br J Plast Surg* 36: 491-497.
10. Kawasaki G, Imayama N, Yoshitomi I, Furukawa K, Umeda M (2019) Clinical Study of Reconstruction Plates Used in the Surgery for Mandibular Discontinuity Defect. *In Vivo* 33: 191-194.
11. Sakakibara A, Hashikawa K, Yokoo S, Sakakibara S, Komori T, et al. (2014) Risk factors and surgical refinements of postresective mandibular reconstruction: a retrospective study. *Plast Surg Int* 2014: 893746.
12. Shunyu NB, Medhi J, Laskar HA, Lyngdoh N, Syiemlieh J, et al. (2014) 5th Rib Osteo-pectoralis Major Myocutaneous Flap-Still a Viable Option for Mandibular Defect Reconstruction. *Indian J Otolaryngol Head Neck Surg* 66: 414-417.