



Analgesic Efficacy Of Ropivacaine In Ultrasound Guided Transversus Abdominis Plane Block And Quadratus Lumborum Block and transversus After Lower Segment Saesarean section under spinal anaesthesia: An Observational Study

Authors

*Abdul Hakeem¹, Anju Parihar²

1. Professor, Department of Anesthesiology & Critical Care, Govt. Medical College, Srinagar, India.
2. Senior Resident, Department of Anesthesiology & Critical Care, Govt. Medical College, Srinagar, India.

Abstract:

Background: An analgesic regimen is required which meets the goal of providing safe and effective postoperative analgesia for the mother, simultaneously ensuring minimal side effects for both the mother and neonate after Caesarean section. **Objective:** This prospective study was undertaken to observe the Degree of postoperative pain relief via Visual Analogue Score (VAS) {time frame: 48 hours}, Duration of postoperative analgesia and Time of request for first rescue analgesia and total consumption of rescue analgesia in first 48 hours. **Methods:** we observed 100 patients over a period of twenty months who had received either TAP block or QL Block. The patients enrolled in the study were clinically assessed, evaluated and investigated as per the normal hospital protocol and proforma. The patients who had received TAP block were assigned group A and the patients who had received QL block were assigned group B. **Group A:** This group consisted of the patients who had received ultrasound guided TAP block with 20 ml of 0.2% ropivacaine. **Group B:** This group consisted of the patients who had received ultrasound guided QL block with 20 ml of 0.2% ropivacaine. **Results:** In our study, the mean duration of analgesia for Ultrasound guided transversus abdominis plane block was 8.5 hours and for Quadratus Lumborum Block it was 16.5 hours. Total dose of rescue analgesia consumption was greatly reduced in QLB (group B) compared to TAPB (group A). The difference was statistically significant ($p < 0.05$). No systemic complications were reported from either of the

two groups. **Conclusion:** From the present study it can be concluded that Ultrasound Guided nerve blocks (TAP block and QL block) can be used as a part of multimodal analgesia for better postoperative pain relief in lower abdominal surgeries like LSCS especially when given before the resolution of spinal anaesthesia. As QLB provides good quality analgesia for longer duration without side effects but proper understanding of the sono-anatomy and technical aspects of quadratuslumborum block are essential for its effective and safe use.

Keywords: Caesarean section, transversus abdominis plane block, Quadratus Lumborum Block, spinal anaesthesia, post operative pain

Introduction:

Caesarean section, a very commonly performed surgical procedure accounting for about 15% births worldwide and 21.1% in developed countries.¹ The rate is on a rising trend in developing countries too. Caesarean section being a major surgical procedure is associated with substantial postoperative discomfort and moderate to severe pain for 48 hours postoperatively.^{2,3} Post-operative analgesia is also important to avoid various complications such as venous thromboembolism, respiratory complications and prolonged hospital stay.⁴ So provision of an effective postoperative analgesia is of key importance in these patients in order to facilitate early ambulation, infant care (including breastfeeding, maternal infant bonding) and prevention of postoperative morbidity.² Multimodal approach to post caesarean pain is preferred over single mode analgesia as it provides better pain control in the postoperative period and reduces complications that may arise from using single mode of analgesia.⁵ The trend of utilizing peripheral nerve blocks as part of multimodal analgesia regime has increased in the past two decades.^{6,7,8} Abdominal field blocks have been followed for many years and extensively used for pain management following abdominal surgeries such as laparotomies and appendicectomies.^{9,10} As the use of ultrasound by anaesthesiologists is increasing, newer techniques are being pioneered and used worldwide. Conventional approaches to TAP block is one of the options that creates satisfactory somatic analgesia with minimal or no visceral blockade.¹¹

Methods:

This prospective observational study “**Ultrasound guided quadratuslumborum block and transversus abdominis plane block for postoperative analgesia after lower segment caesarean section under spinal anaesthesia**” was conducted at Government Medical College Srinagar in the Department of Anaesthesiology. Hundred patients belonging to ASA class I & II and a normal singleton pregnancy with a gestation of at least 37 weeks posted for elective caesarean delivery under spinal anaesthesia.

PREANESTHETIC PREPARATION

The patients enrolled in the study were clinically assessed, evaluated and investigated as per the normal hospital protocol and proforma. The Visual Analogue Scale (VAS) as the method of rating pain was explained to all the patients prior to the surgery.

On arrival to operating room, consent was checked and fasting confirmed. Standard monitoring including ECG, blood pressure and pulse oximetry was instituted. Intravenous access using 18 G i.v. cannula was established.

Patient received inj. Ranitidine 50 mg and inj. Metoclopramide 10mg i.v. as premedication.

In all patients, spinal anaesthesia was performed. With the patient in the sitting position the midline and level of L3-4 and L4-5 intervertebral spaces were identified. Using 26 G Quincke's spinal needle hyperbaric bupivacaine 15 mg was injected intrathecally. Patient was immediately placed in the supine position with left uterine displacement. Spinal Anaesthesia was considered successful when a bilateral block to T6 assessed by loss of cold and touch (blunt pin) discrimination, was established 5 min after the spinal injection.

Anaesthetic and surgical treatments were performed in usual manner.

At the end of the surgery, with the patient in supine position, still fully monitored and after the abdomen was cleaned with 10% betadine solution and under all aseptic precautions, the TAP and QL blocks were performed by an experienced anaesthesiologist.

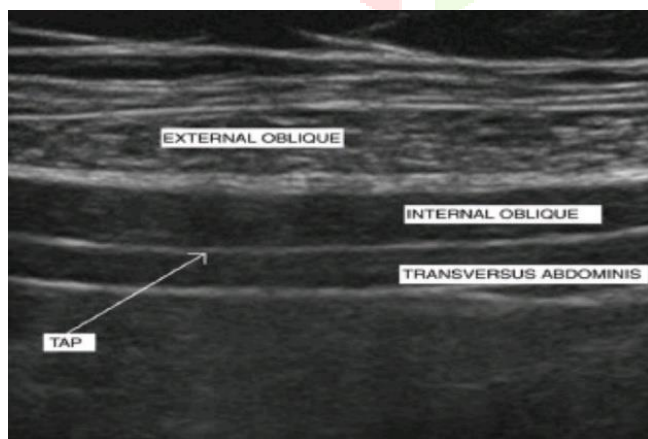
TAP block technique

A transversely oriented linear ultrasound probe (6-12 MHz) was applied to visualize the anterolateral abdominal wall where the three muscle layers were most distinct.

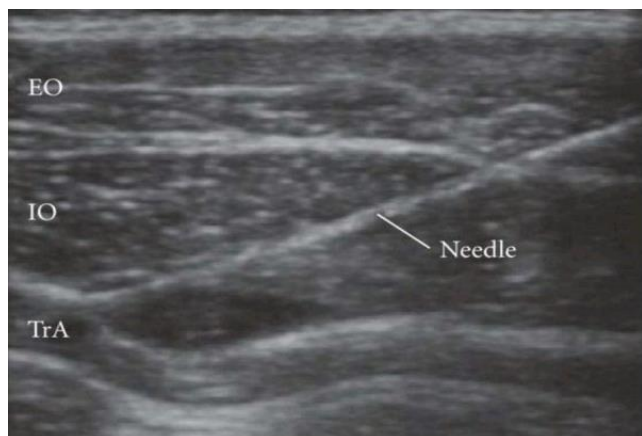After identification of the transversus abdominis plane between the internal oblique and transversus abdominis muscle, the probe was moved posterolaterally to lie across the mid axillary line midway between the costal margin and iliac crest.

A 50 mm 23 G spinal needle was used in our study, the block needle was introduced anteriorly and advanced in an in plane approach, i.e the needle was held parallel to the long axis of ultrasound probe. A hypo-echoic layer, created by injection of a small amount of normal saline was easily visualized creating a lens shaped / fish mouth appearance.

The needle tip was directed into the plane between the internal oblique and transversus abdominis muscle and was followed by insertion of 20 ml of 0.2% Ropivacaine. The TAP block was performed on the opposite side too using similar technique.



Ultrasound visualization of the layers of the abdominal wall and transversus abdominis plane.

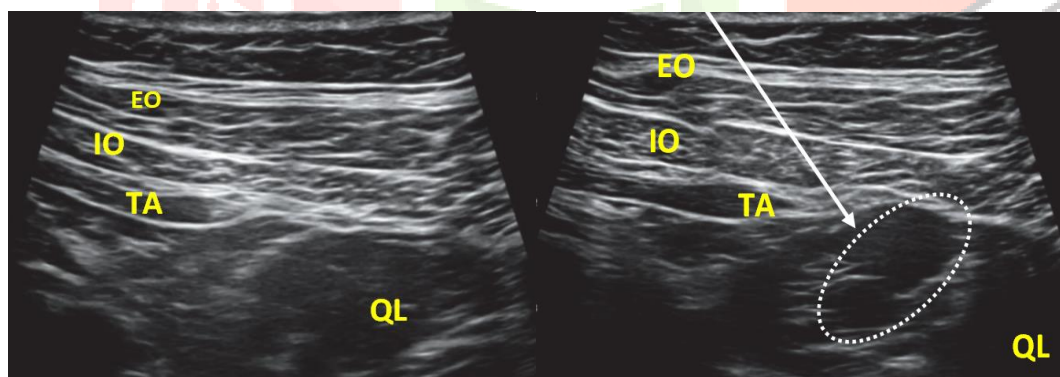


Ultrasound image during initial injection of a small amount of test solution, with a lens shaped appearance.

Technique for QL block

For QL block the transducer probe was placed at the level of anterosuperior iliac spine and moved cranially until the 3 abdominal muscles were clearly identified. The external oblique muscle was followed posterolaterally until its posterior border was visualized (hook sign), leaving underneath the internal oblique muscle, like a roof over the quadratus lumborum muscle. The probe was tilted down to identify a bright hyperechoic line that corresponded with the middle layer of the thoracolumbar fascia.

The needle (23 G, spinal needle) was inserted in plane from anterolateral to posteromedial. The optimal point of injection for QL block was determined over the lumbar interfascial triangle using hydrodissection and 20ml 0.2% Ropivacaine was inserted. Using similar technique QL block was performed on the other side too.



Pre-injection

Post-injection

Ultrasound images of lateral QL B

EO: external oblique muscle, IO: internal oblique muscle, TA: transversus abdominis, QL: quadratus lumborum, white arrow: needle trajectory, and white dotted line: spread of local anesthetic.

For statistical purposes the patients who had received either TAP block or QL block were assigned two groups. The patients who had received TAP block were assigned group A and the patients who had received QL block were assigned group B.

Group A: This group consisted of the patients who had received ultrasound guided TAP block with 20 ml of 0.2% ropivacaine.

Group B: This group consisted of the patients who had received ultrasound guided QL block with 20 ml of 0.2% ropivacaine.

Postoperative assessment

Immediately after the performance of block, all the patients were observed for 1 hour to ensure cardio-respiratory stability. Serial measurements of heart rate, blood pressure and respiratory rate were taken at every 5 min for first 30 minutes, and then every 10 min until 1 hour post procedure.

The pressure and severity of pain was assessed systematically using Visual Analog Scale (VAS) at 0 hour, 1 hour 2,4,8,12,18,24,36 and 48 hours. Further at the end of 48 hours, patients were evaluated with respect to time to first rescue analgesia, total analgesia consumption and post-operative nausea/vomiting.

Statistical Methods

The recorded data was compiled and entered in a spreadsheet (Microsoft Excel) and then exported to data editor of SPSS Version 20.0 (SPSS Inc., Chicago, Illinois, USA). Continuous variables were expressed as Mean \pm SD and categorical variables were summarized as frequencies and percentages. Graphically the data was presented by bar diagrams and line diagrams. Student's independent t-test was employed for comparing continuous variables. Chi-square test or Fisher's exact test, whichever appropriate, was applied for comparing categorical variables. A P-value of less than 0.05 was considered statistically significant. All P-values were two tailed.

Conflict of interest: nil

Funding: nil

Results:

This prospective observational study was done over a period of 20 months from October 2017 to May 2019 at LalDed hospital an associated hospital of Government Medical College Srinagar. Patients were comparable regarding their demographic profile (Table 1).

Table 1: Demographic profile of the study population.

Parameters	Group A n=50	Group B n=50	P value
Age (yrs)	27.5 \pm 3.28	26.7 \pm 3.67	0.248*
Weight (kg)	63.7 \pm 4.35	63.5 \pm 3.55	0.172*
ASA I/II	43/7	41/9	0.576*
Height (cm)	166.3 \pm 4.61	168.4 \pm 5.54	0.264*
Duration of surgery	38.5 \pm 5.63	36.9 \pm 6.42	0.306*

(Mean, SD= standard deviation,* = level of significance)

Comparison between two groups based on VAS pain score postoperatively at 0,1,3,6,9,18,24,36 and 48 hours. The VAS pain scores between two groups shows significant difference ($p < 0.001$). the overall VAS score in group B was lower than in group A (Table 2).

Table 10: Comparison based on VAS in two groups at various intervals of time

Time Interval	Group A	Group B	P value
0 Hour	0.52±0.540	0.39±0.276	0.225
1 Hour	1.13±0.646	0.63±0.241	<0.001*
3 Hour	2.13±0.646	0.91±0.493	<0.001*
6 Hour	3.26±1.102	1.43±0.583	<0.001*
9 Hour	4.02±1.677	2.30±0.726	<0.001*
12 Hour	2.46±1.463	3.39±1.064	0.002*
18 Hour	3.02±1.205	3.17±1.981	0.514
24 Hour	3.91±1.457	2.52±1.786	<0.001*
36 Hour	2.76±1.822	1.72±1.905	0.006*
48 Hour	1.15±1.053	0.78±0.66	0.045*

(Mean, SD= standard deviation, * = level of significance)

The duration of analgesia in Group A was 8.5 ± 1.998 hours and In Group B the duration was 16.5 ± 3.096 hours. The difference in duration of analgesia between the two groups was statistically significant ($p < 0.001$) (Fig 1).

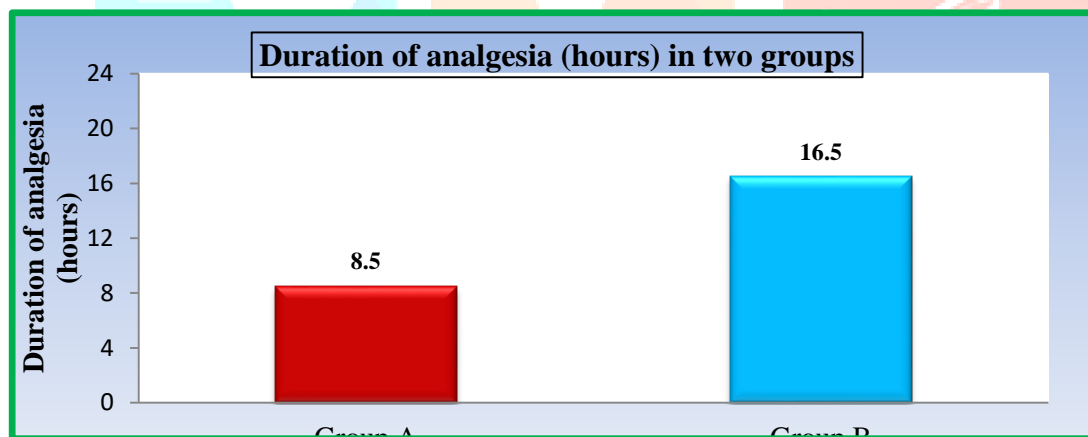


Fig 1. Duration of analgesia

In group A the mean analgesic consumption dose was 1.07 ± 0.264 grams at 12 hours, 2.11 ± 0.317 grams at 24 hours and 2.67 ± 0.673 at 48 hours. In group B it was 0.43 ± 0.501 grams at 12 hours, 1.35 ± 0.567 grams at 24 hours and 1.65 ± 0.604 grams at 48 hours. The difference was statistically significant ($p < 0.001$) (Fig 2).

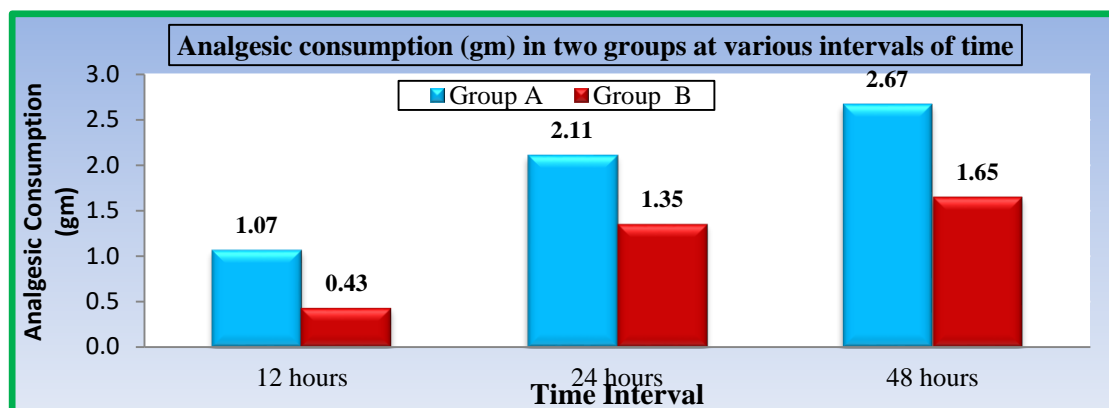


Fig 2: Total rescue analgesia consumption between the two groups

Discussion:

Relief from pain is part of the fundamental human right to health.¹² Pain relief after caesarean varies from a single suppository to high tech invasive analgesia techniques for 48 hours. Parturients are not always considered as 'patients' because there is no disease involved. Not infrequently, pain relief is restricted because of the incorrect belief that this is the best way to avoid sedation, to optimise breast feeding and mobilise the patient eager to care for her baby while preventing thromboembolism.

Compared to traditional techniques, ultrasound-guided peripheral nerve block procedures enable anaesthesiologists to reliably inject local anaesthetic at a target location with a decreased risk of needle trauma to the nerve and surrounding structures.

The present study compared the Ultrasound guided Transversus Abdominis Plane block and Quadratus Lumborum block after LSCS under spinal anesthesia with regard to their duration of analgesia, quality of analgesia, hemodynamic parameters, total dose of analgesia consumption and complications.

In our study the mean duration of analgesia for US guided TAP block was 8.5 hours (6-12 hours) and for QL block it was 16.5 hours (9-24 hours) with p value <0.001 which shows statistically significant difference.

Blanco R et al.¹³, in a randomized controlled trial done in 2016 concluded that QLB produces more prolonged analgesia than TAP block. Similar results have been published in other studies and the major advantage of QL block was considered to be its analgesic action similar to opioid analgesics, yet avoiding the adverse effects such as nausea and vomiting.

Murouchi T et al.¹⁴ investigated the relationship between the local anesthetics blood level and the efficacy of the QLB type 2 and TAP block in adults, and they found that in TAP block, the local anesthetic blood levels were higher than QLB type 2, but the analgesic effect was better with QLB type 2 than with TAP block, and this result was explained by the following, during QLB, some of the administered drug is thought to move from the intermuscular space into the paravertebral space which is filled with adipose tissue and the local

tissue perfusion of the adipose tissue is low which results in low absorption speed of a local anesthetic into the blood.

In our study pain was assessed using Visual Analog Scale. The VAS scores were significantly better at every observation time in the QLB group than in the TAPB group. BaidyaDK et al.¹⁵ performed single injection QL transmuscular block between the QL and psoas major in lateral position on five children undergoing pyeloplasty, and they reported that it was associated with good postoperative analgesia. Oksuz Get al.¹⁶, who compared TAP block and QLB in pediatric patients undergoing lower abdominal surgery and reported that TAP block group showed significantly higher postoperative FLACC scores than QLB group ($P < 0.05$); furthermore, the number of patients who received rescue analgesia in the first 24 h postoperatively was significantly higher in TAP block group than in QLB group ($P < 0.05$). Parent's satisfaction scores were lower in TAP block group than in QLB group.

Rescue analgesia was provided if the VAS score was equal to or more than 4. Injection Paracetamol 1 gm intravenous infusion was used as rescue analgesia. In our study the time to request for first rescue analgesia and the total consumption of rescue analgesia in 48 hours was observed.

Patients who received QL block had significantly less cumulative rescue analgesia doses than patients who received the TAP block ($p < 0.001$) at 12 hours (mean - 0.43 ± 0.50 gms vs 1.07 ± 0.26 gms; $p < 0.001$), 24 hours mean - 1.35 ± 0.56 gms vs 2.11 ± 0.31 gms; $p < 0.001$) and 48 hours (mean - 1.65 ± 0.060 gms vs 2.67 ± 0.67 gms; $p < 0.001$). YousefNK¹⁷ conducted a study in 2018 in which he compared TAP and QL blocks in women who underwent total abdominal hysterectomy. Fentanyl and morphine requirement was less in the QL block group. A meta-analysis published in 2016 compared eight trials studying the lateral technique of TAP block (the widely recognized TAP block in between internal oblique and transverses abdominis muscles) versus four trials studying the posterior technique for a TAP block (which is similar to QLB type 1) and reported that patients who had the posterior TAP block had less postoperative morphine consumption during 12–24h and 24–48h intervals.

In our study none of the patients developed any complication in both the study groups. Kumar GD et al.¹⁸ compared TAP block versus QL block for postoperative analgesia following lower abdominal surgeries and concluded that The adverse events associated with escalating doses of morphine, such as pruritus, nausea, somnolence, and respiratory depression can also be avoided by lower doses required with QL block.

References:

1. **McMorrow RC, Ni Mhuircheartaigh RJ, Ahmed KA, Aslani A, Ng SC, et al.** Comparison of transversusabdominis plane block vs spinal morphine for pain relief after caesarean section. *Br J Anaesth* 2011; 106 (5): 706-712.
2. **Farragher RA, Laffey JG. Postoperative pain management following caesarean section, In: Shorten G, Carr D, Harmon D, et al., eds.** Postoperative pain management: an evidence- based guide to practice. 1st ed. Philadelphia, PA: Saunders Elsevier, 2006: 225-38.
3. **Samina Ismail.** What is new in postoperative analgesia after caesarean sections ... editorial view. *Anaesth, Pain & Intensive Care* 2012; Vol. 16(2): 123-126.
4. **Mankikar MG, Sardesai SP, Ghodki PS.** Ultrasound-guided transversusabdominis plane block for postoperative analgesia in patients undergoing caesarean section. *Indian J Anaesth* 2016;60:253-7.
5. **Shaaban M, Esa WA, Maheshwari K, Elsharkawy H, Soliman LM.** Bilateral Continuous Quadratuslumborum block for acute abdominal pain as a rescue after opioid induced respiratory depression. *A&A Case Reports* 2015;5:107-11.
6. **McDonnell JG, O'Donnell B, Curley G, Hefferman A, Power C, Laffey JG.** The analgesic efficacy of transversusabdominis plane block after abdominal surgery: a prospective randomised trial. *Anesth&Analg* 2007;104(1):193-197.
7. **McDonnell JG, Carney J, Laffey JG.** The transversusabdominis plane block provides effective postoperative analgesia in patient undergoing total abdominal hysterectomy. *Anesth&Analg* 2008; 107(6):2056-2060.
8. **Marhofer P, Harrop-Griffiths W, Willschke H.** Fifteen years of ultrasound guidance in regional anaesthesia: Part 2- Recent developments in block techniques. *Br J Anaesth* 2010;104(6):673-683.
9. **Muktar K.** TransversusAbdominis Plane (TAP) Block. *Journal of NYSORA* 2009;12: 28-33.
10. **Suresh S, Chan VW.** Ultrasound guided transversusabdominis plane block in infants, children and adolescents: a simple procedural guidance for their performance. *PaediatrAnaesth* 2009;19(4):296-299.
11. **Abrahams MS, Horn JL, Noles LM, Aziz MF et al.** Evidence-based medicine: Ultrasound guidance for truncal blocks. *RegAnesth Pain Med* 2010;35(2 Suppl):S36-S42.
12. **Brennan F, Carr DB, Cousins M.** Pain management: a fundamental human right. *AnesthAnalg.* 2007;105(1):205-21.
13. **Blanco R, Ansari T, Riad W, Shetty N.** QuadratusLumborum Block versus TransversusAbdominis Plane Block for Postoperative pain after cesarean delivery A Randomised Controlled Trial. *RegAnesth Pain Med* 2016;41:757- 62.

14. **Murouchi T, Iwasaki S, Yamakage M.** Quadratuslumborum block:Analgesic effects and chronological ropivacaine concentrations afterlaparoscopic surgery. RegAnesth Pain Med 2016;41:146-50.
15. **Baidya DK, Maitra S, Arora MK, Agarwal A.**Quadratuslumborum block: An effective method of perioperative analgesia in children undergoing pyeloplasty. J ClinAnesth 2015;27:694-6
16. **Oksuz G, Bilal B, Gürkan Y. Urfalioglu A, Arslan M, GisiG, et al.**Quadratuslumborum block versus transversusabdominis plane block in children undergoing low abdominal surgery: A Randomized controlled trial. RegAnesth Pain Med 2017;42:674-9.
17. **Yousef NK.**Quadratuslumborum block versus transversusabdominis plane block in patients undergoing total abdominal hysterectomy: A randomised prospective controlled trial. Anesth Essays Res 2018;12:742-7.
18. **Kumar GD, Gnanasekar N, Kurhekar P, Prasad TK.** A comparative study of transversusabdominis plane block versus quadratuslumborum block for postoperative analgesia following lower abdominal surgeries: A prospective double blinded study. Anesth Essays Res 2018;12;919-23.

