



ANGLE CLOSURE PRESENTED WITH MODERATE MYOPIA

Debarati Ghosh¹, Saptarshi Mukherjee², Sweety Sharma³

¹Clinical Optometrist, ²Faculty Optometrist, ³Clinical Optometrist, Glaucoma Department
Dr Shroff's Charity Eye Hospital, New Delhi, India

ABSTRACT

Angle closure in a myopic patient is rare. Here is presented a report of one 37- years old female patient who presented with cloudiness of vision in both eyes (OU) since two months, associated with occasional ocular pain and heaviness around temporal region for one year. There was no history of ocular trauma. On presentation, her best corrected visual acuity was 6/9[-4.50/-1.25x120] in Right eye and 6/9[-5.25DS] in Left Eye. Slit Lamp examination demonstrated a shallow anterior chamber [Van Herick Grade I] in both eyes. Moreover both the eyes exhibited shorter axial length with increased Lens vault and thickness. The intraocular pressures (IOP) recorded were 14mm Hg for right eye and 16 mm Hg for Left eye respectively. Gonioscopy revealed completely closed angles for both the eyes. However she was successfully treated with Peripheral Laser Iridotomy in both eyes to completely open her angles.

This case demonstrates the uncommon presentation of narrow angles in a moderately myopic patient. The age and refractive error of this patient should immediately raise the possibility of an atypical cause of angle narrowing. In this case, the examination findings point to Microspherophakia with increased Lens vault as a cause of angle narrowing.

BACKGROUND

Microspherophakia (MSP) is a rare form of crystalline lens disorder. The disease can be present as an isolated condition or can be associated with several systemic disorders.⁽¹⁾ Microspherophakia is characterized by increased anteroposterior diameter and reduced equatorial diameter.^(2,3) In these cases the zonules are under developed and abnormally weak and are unable to exert enough traction on the lens leading it to a more spherical configuration rather than forming a typical oval or biconvex form.⁽⁴⁾ I hereby described a case of 37 years old female with bilateral moderate myopia with angle closure presented in Dr Shroff's Charity Eye Hospital.

CASE PRESENTATION

A 37 years old female presented at Dr Shroff's Charity Eye Hospital with complaints of diminution of vision in both eyes since two months, and occasional ocular pain and heaviness around temporal region for one year. She had last been checked for glasses two years back. She had no history of ocular trauma. Her family history was unremarkable. Priorly she visited one hospital at Lucknow, India, where Optical Coherence Tomography (OCT) and Ultrasound Bio-microscopy (UBM) were performed. Where OCT reports were stable and UBM showed shallow anterior chamber depth and increased lens thickness.

On examination in our hospital, presenting best corrected visual acuity with Snellen Chart for Right eye was 6/9 with a refractive error of [-4.50/-1.25x120] and for Left eye was 6/9 [-5.25DS]. Near vision was N6 for both eyes. The intraocular pressures (IOP) recorded were 14mm Hg for right eye and 16 mm Hg for Left eye respectively.

The Slit- Lamp examination was noted for bilaterally shallow anterior chambers [Van Herick Grade I] and iridodonesis in both eyes (Figure 1). Both corneas were clear .The Pupils were round and reacted normally to light. The crystalline lenses were clear. The cup disc ratio was 0.5 for both eyes (OU) with healthy neuroretinal rim (Figure 2). There were no other abnormalities noted in anterior and posterior segment.

(A)

(B)




Figure 1: The slit lamp examination of the patient’s Right eye (A) and Left eye (B) demonstrates shallow anterior chamber.

(A)

(B)

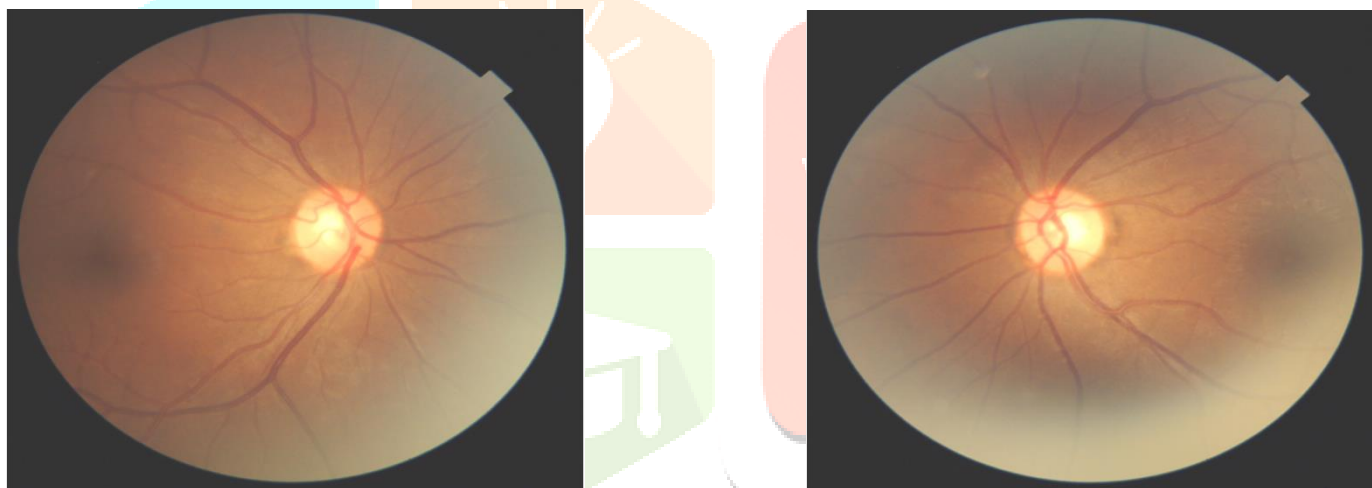


Figure 2: (A) Right eye and (B) Left eye with healthy disc.

On undilated non indentation Gonioscopy all the angles were completely closed for both the eyes. Compression opened the angles to the Scleral spur, but no Peripheral Anterior Synecchia (PAS) were detected(Figure 3) (Figure 4).

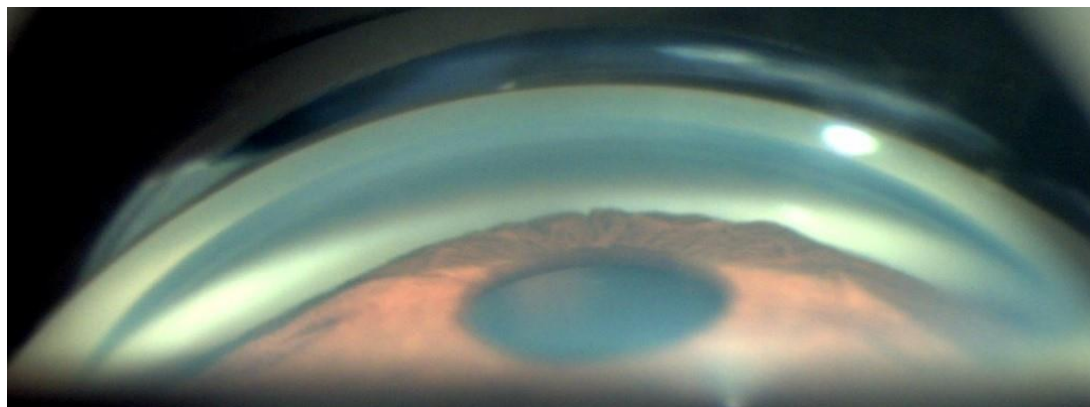


Figure 3: Convexity of iris in Gonioscopy.






Figure 4: Gonioscopy pictures.

IOL master recorded Axial Length (AXL) of 20.40mm and Anterior chamber depth (ACD) of 2.11mm in right eye. And for Left Eye Axial length (AXL) was 20.50mm and ACD was 2.23mm. This clearly shows that the ACD was very shallow and AXL was very short. Lens Thickness noted was 4.40mm for right eye and 4.50mm for left eye which was quite thicker than the normal (Figure 5). And Lens Vault was 1529um for the Right Eye and 1164um for Left Eye (Figure 6) .Due to this steepness of the lens and shallow Anterior Chamber a diagnosis of bilateral moderate myopia with angle closure was made. This triad of lenticular myopia, shallow Anterior Chamber, greater lens thickness with angle closure shows possible diagnosis of microspherophakia with increased lens vault. Later Peripheral Laser Iridotomy was performed in both eyes and patient was asked to follow up after one week.

(A)



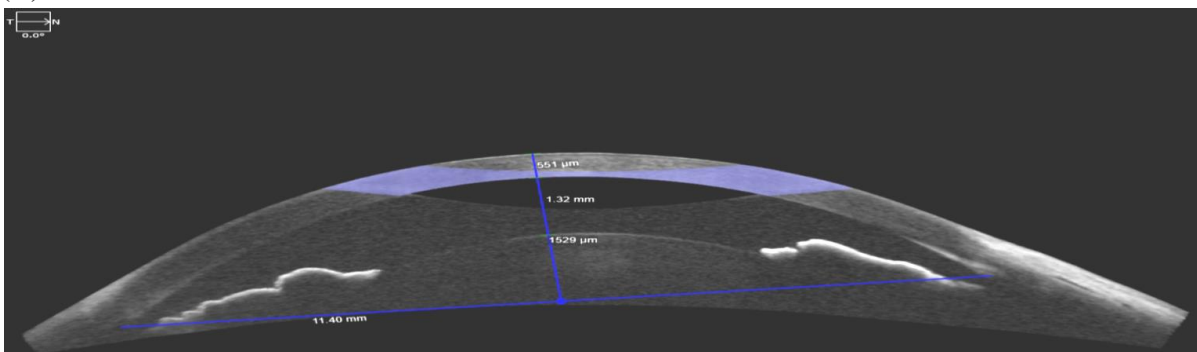
(B)

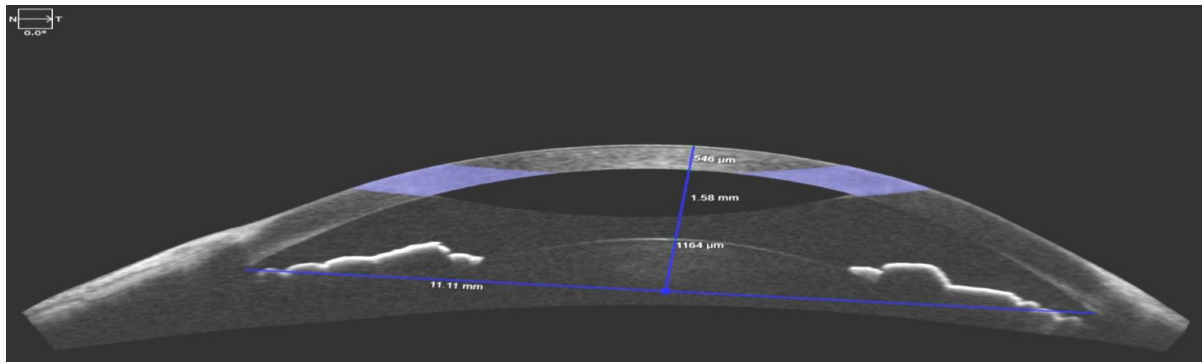


Figure

5: IOL Master of the patient’s right(A) and Left(B) eyes demonstrates increased lens thickness.

(A)





(B)

Figure 6: ASOCT of Right eye (A) and Left eye (B) showing shallow anterior chamber with increased Lens Vault.

After 1 week again the patient reported in our hospital and undilated non indentation Gonioscopy was again performed, and this time Posterior Trabecular Meshwork (PTM) was visible in all four quadrants and iris convexity was also present for both eyes.

DISCUSSION

This case demonstrates the uncommon presentation of narrow angles in a moderately myopic patient.⁽⁵⁾ In this case, the history and examination findings point to microspherophakia as the cause of angle narrowing. Microspherophakia is usually a bilateral,⁽⁶⁾ rare condition occurs due to the under developed zonules causing abnormality of the crystalline lens. They limit the radial growth of developing lens, leading to the formation of a relatively spherical lens and resultant high lenticular myopia. There is an increase in anteroposterior diameter of the lens along with reduced equatorial diameter. With pharmacologic pupillary dilatation, the lens equator and zonules may be seen to varying degrees.⁽⁷⁾

Some other features of Microspherophakia that have been reported include iridodonesis, phacodonesis, Lens protrusion, pupillary block, lens dislocation or subluxation.⁽⁸⁾ Not all features are seen in every patient with Microspherophakia. As in our case there was no lens subluxation or dislocation, though iridodonesis was present in both eyes.

Angle closure in microspherophakia usually results from pupillary block induced by the anteriorly displaced lens and its increased curvature. In cases where the zonules are not intact, the Lens dislocation and forward movement cause pupillary block and phacomorphic glaucoma.⁽⁹⁾

The cause of microspherophakia is still unknown. It has been suggested that it is due to arrest in development or abnormal insertion of the secondary lens fibres⁽¹⁰⁾ both of which may be secondary to a nutritional deficiency from defects in the tunica vasculosa lentis⁽¹¹⁾ and both may occur at the fifth to sixth month of embryonic life as the lens is normally spherical at this stage.⁽¹²⁾

Zonular fibres may also be undeveloped due to lack of tension and arrest in lens development so that it may remain spherical instead of gradually converting to a normal biconvex shape.⁽¹³⁾ This is consistent with the frequent association of microspherophakia and lens dislocation.

Microspherophakia may occur as isolated defect,^(1,14) be well known⁽¹⁴⁾ or may be associated with systemic anomalies. Its associations with Weill- Marchesani syndrome and Marfan's syndrome are well documented.^(15,16,20) Less commonly, it has been reported in other inherited and developmental disorders such as Alport's syndrome,⁽¹⁷⁾ Peter's anomaly,⁽¹⁷⁾ and Klinefelter syndrome.⁽¹¹⁾ Moreover the age and refractive error of this patient should immediately alert the clinician for the possibility of Microspherophakia with increased Lens Vault. Although this patient was mildly short in height and middle aged women, she had normal appearing fingers and no known systemic abnormality.

There is no established standard management for microspherophakia.⁽¹⁷⁾ It has been suggested that Peripheral Iridotomy to relieve pupillary block should be performed in patients with microspherophakia.⁽³⁾ Pupillary block is exacerbated with miotics and relieved by mydriatics. Miotics usually slack the ciliary zonules which will ultimately cause lens to move anteriorly, leading to shallower anterior chamber. Accordingly miotics are not recommended in

the management of microspherophakia.⁽³⁾ On the other hand, cycloplegic agents such as atropine relax the ciliary muscle, tighten the zonules causing posterior lens movement that can open the angle and decrease the IOP.^(18,19)

CONCLUSION

This patient was diagnosed with microspherophakia with moderate myopia causing angle closure and increased Lens Vault. In this case the patient was successfully treated with Peripheral Iridotomy in order to completely open her angles. Her intraocular pressures remains normal and she continues to be asymptomatic with refractive correction.

REFERENCES

1. Brown NP, Bron AJ. Lens Disorders. A Clinical Manual of Cataract Diagnosis. London: Butterworth Heinemann, 1966: 8690
2. Willoughby CE, Wishart PK. Lensectomy in the management of glaucoma in spherophakia. *J Cataract Refract Surg.* 2002; 28:1061
3. Macken PL, Pavlin CJ, Tuli R, Trope GE. Ultrasound bio microscopic features of spherophakia. *Aust N Z J Ophthalmol.* 1995; 23:217-20
4. Dayal Y, Mehra KS. Spherophakia. *Am J Ophthalmol.* 1960; 50:333-4.
5. Yaniv Barkana, Wisam Shihadeh, Cristiano Oliveira, Celso Tello et al. Angle closure in highly myopic eyes, *Ophthalmology.* 2006 Feb; 113(2):247-54.
6. Duke-Elder S. System of Ophthalmology Vol. 111. Normal and Abnormal Development. Part 2. Congenital Deformities. St Louis: The CV Mosby Co 1963: 694-696.
7. Sirisha Senthil, Harsh L Rao, Jonnadula G Babu, Anil K Mandal. Outcomes of Trabeculectomy in Microspherophakia. *Indian Journal of Ophthalmology.* 2014 May; 62(5): 601-605.
8. Ben Yahia S, Ouechtati F, Jelliti B, Nouira S, Chakroun S, Abdelhak S et al. Clinical and genetic investigation of isolated microspherophakia in a consanguineous Tunisian family. *J Hum Genet.* 2009; 54:550-3.
9. Kaushik S, Sachdev N, Pandav SS, Gupta A, Ram J. Bilateral acute angle closure glaucoma as a presentation of isolated microspherophakia in an adult: case report. *BMC Ophthalmol.* 2006; 6:29.
10. Taylor D. Paediatric Ophthalmology, 2nd ed. London: Blackwell Science, 1997: 446
11. Johnson VP, Grayson M, Christian JC. Dominant microspherophakia. *Arch Ophthalmol* 1971; 85: 534-542.
12. Nagata M, Takagi S, Yamasaki A, Tsunematsu S, Kumagami T, Itamochi C, Tamai A. Histopathological study of microspherophakia in the Weill-Marchesani syndrome. *Jpn J Ophthalmol* 1995; 39: 89-95.
13. Rufina Tin-Yan Chan, H Barry Collin. Microspherophakia. *Clin Exp Optom.* 2002 Sep; 85(5):294-299
14. Apple DJ, Rabb MF. Ocular Pathology. St. Louis: Mosby Year Book, 1991: 124.
15. Easty DL, Sparrow JM. Oxford Textbook of Ophthalmology. Vol I. Oxford: Oxford University Press, 1999 708.
16. Pavan-Langston D. Manual of Ocular Diagnosis and Therapy, 3rd ed. Boston: Little, Brown and Company, 1985.
17. Lee DA, Higginbotham EJ. Clinical Guide to Clinical Ophthalmology. New York: Theime, 1999: 15.
18. Yang J, Fan Q, Chen J, Wang A, Cai L, Sheng H, et al. The efficacy of lens removal plus IOL implantation for the treatment of spherophakia with secondary glaucoma. *Br J Ophthalmol.* 2016; 100:1087-92.
19. Abramson DH, Coleman DJ, Forbes M, Franzen LA. Pilocarpine. Effect on the anterior chamber and lens thickness. *Arch Ophthalmol.* 1972; 87:615-20.
20. Taylor JN. Weill-Marchesani syndrome complicated by secondary glaucoma. Case management with surgical lens extraction. *Aust N Z J Ophthalmol.* 1996; 24:275-8.