



OUTCOME OF NON OPERATIVE MANAGEMENT OF ADHESIVE SMALL BOWEL OBSTRUCTION

Dr Priyanka Koul, Dr Aamir Hussain hela*, Dr Mohd Riaz, Dr Haseeb Mohammad Khandwaw

*Corresponding Author (Aamir345679@gmail.com)

Abstract

Introduction: Intra-abdominal adhesions represent the first cause of small bowel obstruction. It accounts for 15% of all emergency room admissions for abdominal pain and occurs in up to 9% of patients following abdominal operations. There is a diagnostic dilemma on how to distinguish between adhesive SBO from other causes of intestinal obstruction, and how to distinguish between ASBO that needs emergency surgery and ASBO that can be successfully treated conservatively.

Methods: We conducted a prospective study upon patients admitted to Government medical college and hospital, Jammu with a diagnosis of adhesive small bowel obstruction to determine the outcome of non-operative management. The study was conducted in time period of 1 year from april 2019 to April 2020.

Results: In our study most of the patients were in the age group of 60 to 70 years with mean age of 66.7 years. The male to female ratio was 2 : 3. In 40 patients who were admitted for first time after index surgery, 29 responded to non operative management while as 11 patients required operative treatment after mean time period of 15.4 hours of conservative trial. Out of 17 patients admitted for second time as adhesion obstruction, 16 patients responded to non operative management and only one patient needed operative management after 16 hours of conservative trial.

Conclusion: Intra abdominal adhesions are the most common cause of small bowel obstruction. Complete medical history and thorough physical examination is mandatory. Flat and upright radiographic films of the abdomen characteristically show multiple air fluid levels and dilated loops of bowel. Administration of oral water-soluble contrast agent (Urografin) has both diagnostic and therapeutic value. The determinants of successful nonoperative management are patient selection, type of bowel obstruction (complete vs partial), etiology and the surgeon's threshold for conversion to operative management.

INTRODUCTION :

Intra-abdominal adhesions represent the first cause of small bowel obstruction¹. It accounts for 15% of all emergency room admissions for abdominal pain and occurs in up to 9% of patients following abdominal operations^{2,3}. The post-operative adhesions are responsible for 40 – 80% of bowel obstructions in

hospitalised patients. The management of patients with small bowel obstruction who underwent surgery is challenging.

Adhesions are fibrous attachments of connective tissue that cause one organ surface to stick with other. Adhesions develop universally after celiotomy and start within hours of intra-abdominal operations, since inflammation is the primary cause of adhesion formation⁴. It has been estimated that 93% of patients who undergo any abdominal surgery develop some degree of adhesions in their life time⁵. Risk of ASBO is 1 - 10% after appendectomy, 6.4% after cholecystectomy, 10 – 25% after intestinal surgery and 17 – 25% after restorative proctocolectomy⁶. There is a diagnostic dilemma on how to distinguish between adhesive SBO from other causes of intestinal obstruction, and how to distinguish between ASBO that needs emergency surgery and ASBO that can be successfully treated conservatively. Contrast enhanced computed tomography (CECT) has improved diagnosis of ASBO in general but fails to accurately identify adhesions as the cause.

Treatment for ASBO may be operative or non-operative. Operative treatment like adhesiolysis through laparoscopic or open approaches, can be effective and essential in some cases i.e, those involving strangulation^{6,7,8}. In adults, conservative treatment of ASBO is effective in a relatively large, but somewhat variable (approximately 40% to 70%), proportion of cases.

METHODS :

We conducted a prospective study upon patients admitted to Government medical college and hospital, Jammu with a diagnosis of adhesive small bowel obstruction to determine the outcome of non-operative management. The study was conducted in time period of 1 year from april 2019 to April 2020. Patients presenting with small bowel obstruction, with no prior abdominal surgery and patients with active TB or history of ATT intake in past (with diagnosis of abdominal TB) and obstruction due to other identifiable causes such as incarcerated hernia, were excluded. Patients presenting with complicated intestinal obstruction suggested by presence of peritonitis, progressive leukocytosis, or impaired bowel wall perfusion on imaging were excluded.

A total of 60 patients were enrolled in our study. Patients put on non-operative management were aggressively resuscitated with an appropriate crystalloid solution. Attention was paid to volume resuscitation, electrolyte balance, haemostasis and nasogastric decompression. Electrolytes were monitored on daily basis and corrected. Oral intake was nil in presence of nasogastric tube. A water soluble contrast agent (Urograffin) was administered via Ryles tube and an abdominal radiograph was taken after 8 hours of contrast administration. Mortality and recurrence were considered as primary outcome measures. The secondary outcome measures included need for surgical re-intervention (adhesiolysis or bowel resection), complications, length of stay, time-interval to recurrence and number of recurrences during follow up

RESULTS :

Our study was conducted on 60 patients who were admitted with diagnosis of adhesion small bowel obstruction. Patients were put on non operative management. Resuscitation with crystalloids was started and

nasogastric tube insertion was done. Electrolyte analysis was done and correction was started. Patient was catheterised and urine output was used as guide to resuscitation.

In our study most of the patients were in the age group of 60 to 70 years with mean age of 66.7 years. The male to female ratio was 2 : 3. The index surgery in 41.66% of patients was for perforation peritonitis. 15 patients were operated for duodenal perforation and 10 patients for ileal perforation. Out of 10 patients who were operated for ileal perforation, ileostomy was made in 5 patients and later subjected to ileostomy closure after 6 weeks. In 26.66% of patients index surgery was for acute appendicitis. In remaining 19 patients index surgery was done for abdominal trauma (13.33%) and malignancy (18.33%). The patients operated for malignancy, three patients had right colonic growth, five had gastric carcinoma, two had left colonic growth and one had transverse colon growth.

Indication of Index surgery	Frequency	Percentage
Duodenal perforation	15	25
Ileal perforation	10	16.66
Acute appendicitis	16	26.66
Abdominal trauma	8	13.33
Carcinoma stomach	5	8.33
Right colon growth	3	5
Left colon growth	2	3.33
Transverse colon growth	1	1.66
Total	60	100

In our study, 17 patients were admitted for second time as adhesion obstruction and out of these 17 patients, 16 patients responded to non operative management and only one patient needed operative management after 16 hours of conservative trial. This patient had undergone distal gastrectomy with Roux-en-Y gastro-jejunosomy as index surgery for pyloric growth. In 40 patients who were admitted for first time after index

surgery, 29 responded to non operative management while as 11 patients required operative treatment after mean time period of 15.4 hours of conservative trial.

In our study, 3 patients were admitted for third time and managed by non operative treatment.

In our study, the mean time duration from index surgery to first readmission was 7.4 months, from 1st to 2nd readmission was 4.3 months and from 2nd to 3rd readmission was 4 months.

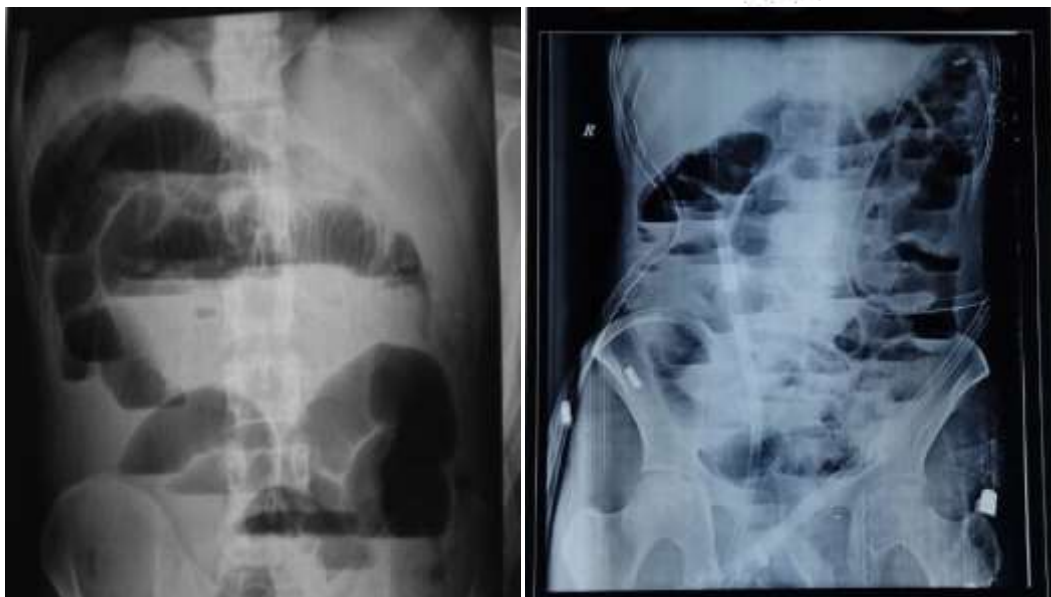
In our study, length of hospital stay was compared at the time of index surgery, first readmission and 2nd readmission. The mean hospital stay at the time of index surgery was 8.4 days. In patients managed by operative intervention at 1st readmission, mean hospital stay was 9.2 days while as in those managed by non operative treatment, mean of hospital stay was 5.8 days. The mean hospital stay for patients at 2nd readmission was 7.9 days and 3.4 days for those managed by operative treatment and non operative treatment respectively.

In our study, patients who were managed by operative treatment, wound infection rate was found to be 9%.

CONCLUSION :

Intra abdominal adhesions are the most common cause of small bowel obstruction. The most common presentation of patients with small bowel obstruction include crampy abdominal pain, nausea, vomiting, distention and acute obstipation. The proximal obstructions present with early and prominent nausea and vomiting while distention is usually late and less prominent.

Complete medical history is of paramount importance to make the diagnosis and determine the etiology. A meticulous physical examination and assessment of vital signs and hydration status are important as part of the initial resuscitation. Flat and upright radiographic films of the abdomen characteristically show multiple air fluid levels and dilated loops of bowel (Figure 1,2). On a plain abdominal film, the small bowel lies centrally and intestinal markings from the valvulae conniventes or plicae circularis encompass the entire diameter of the bowel.



Many centers have replaced plain radiographs by computed tomography (CT) as the primary diagnostic imaging modality for the diagnosis of suspected intestinal obstruction. Early detection of bowel ischemia is key to successful surgical management of obstruction. CT has a reported diagnostic accuracy of greater than 90%^{12,13}.

The initial management should begin with aggressive fluid resuscitation and nasogastric decompression to prevent further accumulation of fluid and air. Nasogastric decompression decreases the chances of aspiration and relieves vomiting. Administration of oral water-soluble contrast agent (Urografin) can be tried. The persistence of contrast material in colonic lumen after 8 hours of oral administration had an accuracy of 93% for predicting which patients would benefit from nonoperative therapy. Lab analysis should include serum electrolyte estimation, complete blood count, lactate concentration, and arterial blood gases analysis. The conditions like suspected ischemia, large bowel obstruction, closed-loop obstruction, acutely incarcerated or strangulated hernia, and perforation are absolute contraindications to non operative management.

Any patient developing signs and symptoms suggestive of strangulation should be immediately subjected to operative intervention. These danger signs include fever, tachycardia, leukocytosis, localized tenderness, continuous abdominal pain, and peritonitis. The presence of any three of these signs has an 82% predictive value for strangulation obstruction¹⁴. The signs of strangulation demonstrated by CT include pneumatosis intestinalis, bowel wall thickening, portal venous gas, generalized ascites, and nonenhancement of the bowel wall. Operative intervention should be strongly considered under these settings¹⁵. Any patient who is not improving with nonoperative management should be offered operative management. However timing of such conversion is more controversial. Some surgeons have advocated 48 hours of nonoperative intervention in all patients before operative intervention^{16,17}. Others advocate a more liberal use of nonoperative therapy, citing a mean time to successful resolution of up to 4.6 days¹⁸. One must note that nonoperative management always carries a risk of overlooking an underlying strangulated obstruction¹⁹.

Over the last 100 years, multiple attempts were made to prevent the formation of unwanted postoperative adhesions. These attempts include, among others, the use of cow cecum, shark peritoneum, sea snake venom, and fish bladder, as well as multiple fluids, mechanical barriers, and gels⁹³. Some authors place a Silastic sheet between two injured peritoneal surfaces for 36 hours to prevent adhesion formation.²¹ Others separate the surfaces at risk for the first 5 to 7 days until full mesothelialization occurs. This appears to be most effective provided the barrier should not incite its own inflammatory response. The most effective method to date has been the application of a sheet of bioresorbable hyaluronate membrane^{20,22}.

REFERENCES :

1. Fausto Catena, Salomone Di Saverio, Federico Coccolini, Luca Ansaloni, Belinda De Simone, Massimo Sartelli, Harry Van Goor *World J Gastrointest Surg.* 2016 Mar 27; 8(3): 222–231.
2. Irvin TT. Abdominal pain: a surgical audit of 1190 emergency admissions.
3. *Br J Surg.* 1989;76(11):1121–1125. ten Broek RP, Issa Y, van Santbrink EJ, Bouvy ND, Kruitwagen RF, Jeekel J, Bakkum EA, Rovers MM, van Goor H. Burden of adhesions in abdominal and pelvic surgery: systematic review and meta-analysis. *BMJ.* 2013;3347: f5588.
4. Hellebrekers BW, Trimbos-Kemper GC, Bakkum EA, et al. Short-term effect of surgical trauma on rat peritoneal fibrinolytic activity and its role in adhesion formation. *Thromb Haemost.* Nov 2000;84(5):876-881.5.
5. Menzies D, Ellis H. Intestinal obstruction from adhesions—how big is the problem? *Ann R Coll Surg Engl.* 1990;72(1):60–63.
6. KTR
7. Li MZ, Lian L, Xiao LB, et al. Laparoscopic versus open adhesiolysis in patients with adhesive small bowel obstruction: a systematic review and meta-analysis. *Am J Surg* 2012;204:779–86.
8. Vettoretto N, Carrara A, Corradi A, et al. Laparoscopic adhesiolysis: consensus conference guidelines. *Colorectal Dis* 2012;14:e208–15.
9. Van Der Krabben AA, Dijkstra FR, Nieuwenhuijzen M, et al. Morbidity and mortality of inadvertent enterotomy during adhesiotomy. *Br J Surg* 2000;87:467–71.
10. Miller G, Boman J, Shrier I, et al. Natural history of patients with adhesive small bowel obstruction. *Br J Surg* 2000;87:1240–7.
11. Seror D, Feigin E, Szold A, et al. How conservatively can postoperative small bowel obstruction be treated? *Am J Surg* 1993;165:121–5; discussion 125–6.
12. Frager D, Medwid SW, Baer JW, Mollinelli B, Friedman M. CT of small-bowel obstruction: value in establishing the diagnosis and determining the degree and cause. *AJR Am J Roentgenol.* Jan 1994;162(1):37-41
13. Fukuya T, Hawes DR, Lu CC, Chang PJ, Barloon TJ. CT diagnosis of small-bowel obstruction: efficacy in 60 patients. *AJR Am J Roentgenol.* Apr 1992;158(4):765-769; discussion 771-762.
14. Sarr MG, Bulkley GB, Zuidema GD. Preoperative recognition of intestinal strangulation obstruction. Prospective evaluation of diagnostic capability. *Am J Surg.* Jan 1983;145(1):176-182.
15. Baerga-Varela Y. Small bowel obstruction. In: Kelly KA, Sarr MG, Hinder RA (eds). *Mayo Clinic Gastrointestinal Surgery.* Philadelphia, PA: Saunders; 2004:421-437.
16. Brolin RE. The role of gastrointestinal tube decompression in the treatment of mechanical intestinal obstruction. *Am Surg.* Mar 1983;49(3):131-137.
17. Pickleman J. Small bowel obstruction. In: Zinner MJ, Schwartz SJ, Ellis H (eds). *Maingot's Abdominal Operations.* 10th ed. New York, NY: McGraw-Hill; 1997:1159-1172.

18. Fleshner PR, Siegman MG, Slater GI, Brolin RE, Chandler JC, Aufses AH. A prospective, randomized trial of short versus long tubes in adhesive small-bowel obstruction. *Am J Surg*. Oct 1995;170(4):366-370.
19. Fleisher LA, Eagle KA. Clinical practice. Lowering cardiac risk in noncardiac surgery. *N Engl J Med*. Dec 2001;345(23):1677-1682.
20. Becker JM, Dayton MT, Fazio VW, et al. Prevention of postoperative abdominal adhesions by a sodium hyaluronate-based bioresorbable membrane: a prospective, randomized, double-blind multicenter study. *J Am Coll Surg*. Oct 1996;183(4):297-306.
21. DiZerega GS, Campeau JD. Peritoneal repair and post-surgical adhesion formation. *Hum Reprod Update*. 2001 Nov-Dec 2001;7(6):547-555.
22. Beck DE, Cohen Z, Fleshman JW, et al. A prospective, randomized, multicenter, controlled study of the safety of Seprafilm adhesion barrier in abdominopelvic surgery of the intestine. *Dis Colon Rectum*. Oct 2003;46(10):1310-1319.

