



INTERNATIONAL JOURNAL OF CREATIVE RESEARCH THOUGHTS (IJCRT)

An International Open Access, Peer-reviewed, Refereed Journal

EVIDENCE BASED HOMOEOPATHY: CASE REPORT OF PCOD WITH KELOID

Dr. Kanchan R. Tayade, Dr. Rima M. Kumar, Dr. Priya P. Singh

Assistant Professor, Assistant Professor, Professor

Department of Pathology

Dr. D.Y.Patil Homoeopathic Medical College & R.C., Dr. D.Y. Pail Vidyapeeth, Pune, India.

Abstract – Keloid is complication of wound healing there is formation of excess collagen leading to marked swelling at site called as keloid. Affect any age commonly seen in age group 11-30.

Case summary – This is the case of 26 years old female with history of keloid & PCOD the case presented here is documented from Shree homeopathic clinic Chinchwad Pune Maharashtra India, patient was treated with individualised Homeopathic Medicine over a period of 8 months, there was significant improvement with Homeopathic treatment with slowly but steadily improvement in case & no recurrence.

Key words – Homoeopathy, collagen, PCOD, Constitutional.

INTRODUCTION—

Keloid is complication of wound healing, there is excessive synthesis of amount of collagen in wound healing results in formation of abnormal nodular masses of collagen at site of injury, keloid generally seen in blacks and has familial tendency, it consist of fibrous growth in subcutaneous tissue, deep fascia or muscle tissue, with glistening smooth surface, characterised by firm irregular claw like masses, projecting above the surrounding skin, lesions are single or multiple, commonly seen on face, neck, ear in front of chest, back and abdomen, generally occur after burn, injury, infection or predisposing factors. Microscopically – it consist of well-defined fibroblast arrange parallel to cutaneous surface, epidermis thinned out and skin appendages are absent (hair, gland, muscle, elastic tissue) it is differentiated by hypertrophic scar where skin appendages are present. Keloid affect physical and psychological quality of life, available therapies have low efficacy and significant mortality. The international clinical recommendation on scar management the list of variety therapeutic approaches including triamcinolone, surgery radiation and combination therapy. Second comorbidity is seen -Ovarian cyst which is common in the reproductive age group, common complaints are irregular or prolong periods, increase in weight, pimples, lumbago, pelvic pain, abdominal pressure, dysmenorrhoea and dyspareunia, high blood pressure, nausea and breast tenderness. Two Common cyst are – 1) follicle cyst and 2) Corpus luteum cyst – in normal menstrual cycle.

Local treatment –

An important element of management of keloid is offering psychological support. Diagnosis is clinical by looking at it and skin biopsy may perform. Homoeopathic medicines are safe and effective and it treats person as whole as it is based on individualisation, it treats person as whole it includes past and present medical history of patient, mental make up of individual, also their physical and generals are taken into consideration, more importance is given to etiological factors (ailments from). Also consider predisposing factors and susceptibility of patient.

General homeopathic medicines given are graphities, silicea, nitric acid, florid acid, sabina, thiosynium
 Phatak repertory – Florid acid, Graphites, Nitric acid Sabina , Silicea
 Special repertory - Biochemic repertory - Calcaria flur, Kali mur, Silicea
 Boric repertory – Florid acid , Graphites , Nitric acid, Sabina , Silicea
 Boeninghusen repertory – chapter skin – Graphites and Kali bich
 Boeninghusen repertory skin exterior – keloid – Bell pern, Calcaria flur, Causticum , Iodum.

Case report –

28-year-old female come with history of keloids and PCOD at Shree Homoeopathic clinic Pune Maharashtra, India.

She presented with keloid on , back , shoulder, abdomen and chest , and thigh , with intense itching and pain(Burning) with Hardness troubled her over 12 yrs. eruptions were characterized as hardness elevated from skin with dryness & intense itching and pain.

Rash? started first on shoulder right side then on left side followed by back then thigh and chest. This is aggravated in winter and summer.

It is associate with H/O irregular menses and PCOD with significant weight gain in last 5 yrs. Her weight is 74 kg. Height is 5.2.

Past History– Took allopathic treatment from general physician without any significant improvement , The skin eruption was diagnosed as Keloids . And for PCOD also she has taken medicine

Treatment history

Took allopathic treatment from general physician , treated with local ointments and oral hormonal medicines.

Past Medical history:

H/O – PCOD since 5 yrs

Family history:

Second child having one elder sister she is also having H/O Keloid

Mother had H/O Brain tumor.

Father – H/O diabetes Mellitus

Socioeconomic history:

Father is Having business and lot of property in her childhood but after that , he is having extramarital affairs and sudden financial loss before 12-13 yrs.

Personal history:

Appetite - decreased

Sleep: on abdomen

Thirst: Thirsty

Thermals: >sun heat (HOT).

Desires: salty

Aversions: fish

Perspiration – over abdomen chest and back

Mental state and life span:

She is educated up to graduate instead of all financial problems, Father use to be head the of the family,. Family environment was not happy thinking about financial losses .Feels insecure about family, at the same time she felt angry towards her father as he was beating her mother on and off, weeps when she got angry . And hence she seeks solitude to commence with her thoughts. With this dissatisfied feeling around her surrounding she leaves the situation and goes to other place for some time. Headache on and off because of overthinking.

She likes to be in friendly and caring environment or friends. Has a smaller number of friends, does not likes to be teased or talked bad about her, so likes company with only selected people who care about her, and helping her younger brother in completing his education so now she presently doing labor work on daily wages.

Physical examination:

Built and nourishment: moderately built, poorly nourished.

Blood pressure: 120/80mmHg.

Pulse rate: 76 beats/min

Local examination of the Skin Lesion:

Inspection: Site: big keloids seen on shoulder, back, thigh, chest.

Shape: round, hard, Border: raised Color: brownish

Characteristic of eruption: Cicatrise . Characterized by Brownish hard eruptions that grows outwards.

Skin lesions associated with severe itching++ and burning, Aggravated by exposure to sun and heat.

Palpation: Tenderness: Not present Surface texture: Rough

Associated signs: pain in extending right arm.

Miasmatic diagnosis – Psora Sycosis**Final diagnosis: Keloids with PCOD**

Repertorial totality – Repertorisation was done by using zomeo homeopathic soft wear (complete repertory - Mind technologies private limited Mumbai Maharashtra state India) and the repertorisation result is shown in **Table 1**



The following characteristic symptoms are considered for repertorisation-

Repertorisation Sheet - Zomeo LAN							
Physician Name : Dr. kanchan rashtrapal tayade , Patient Name : , Reg. No. : , Date : 06/03/2021							
Remedy	Nat-m	Lach	Sulph	Nit-ac	Phos	Calc	Puls
Totality	19	15	15	15	13	12	12
Symptoms Covered	9	9	8	7	7	7	7
[Murphy] [Skin]Scars, cicatrices, (see Keloids):	1	1	1	3	2	1	1
[Murphy] [Clinical]Scars, general, cicatrices, (see Keloids):Painful:	2	2	1	2	1	0	1
[Complete] [Mind]Weeping, tearful mood:Anger, vexation:After:	1	1	1	1	0	1	1
[Murphy] [Headache]Periodic, headaches, (see Migraines):	3	2	2	3	2	2	2
[Murphy] [Mind]Financial, loss of wealth or property, ailments from:	1	1	0	0	0	1	1
[Complete] [Generalities]Food and drinks:Salt or salty food:Desires:	4	1	3	4	4	3	0
[Murphy] [Generals]Hot, weather:Agg.:	2	3	3	1	1	0	3
[Complete] [Mind]Brooding:	4	1	3	1	1	2	3
[Complete] [Mind]Irritability:Alone:Desires to be:	0	0	0	0	0	0	0
[Murphy] [Female]Tumors, genitalia, (see Cancer, Cysts, Fibroids):Ovaries, (see Cancer, Cysts, Fibroids):	0	3	0	0	0	2	0
[Murphy] [Food]Fish, general:Aversion, to:	1	0	1	0	2	0	0

Intervention –

First prescription on – 14 Mach 2020

Prescription is based on individualisation totality of symptoms and Materia Medica, more importance is given to etiological factors.

Thermally patient is Hot.

Medicine Natrum muriaticum 200 C one dose given for 15 days . On subsequent follow up potency changed based on assessment of improvement in keloid.

Follow up and outcome – follow up o was assessed 15 days or whenever required , summarisation of dates wise follow up given in **table 2**

Table 2

Sr. No.	Date	Symptoms	Medicine and repetition	Justification
1.	14-3-2020	Hard painfull keloids , menses irregular, decrease sleep	Natrum mur 200 . 1 dose 4 pills stat placebo for 15 days	Covering totality
2.	01-04-2020	Itching decrease , sleep improve, menses on time	Placebo for 15 days	Overall improvement in status
3.	12-6-2020	Again itching increase , but hardness of kelod decrease , menses delayed	Natrum mur 200 . 1 dose 4 pills stat	As complaints are reappear
4.	3-7-2020	Pain decrease , itching decrease, menses on time	Rubrum for 15 days	Patient is improving
5.	16-9-2020	Pain decrease , itching decrease, menses on time	Rubrum for 30 days	Patient is improving
6.	16-10-2020	Pain decrease , itching decrease, hardness and size is decreasing menses on time	Rubrum for 30 days	Patient is improving
7.	23-11-20120	Pain decrease , itching decrease, menses on time	Rubrum for 15 days	Patient is improving
8.	8-12-2020	Pain & itching increase, ,menses on time, sleep decrease , irritable, weeping , delayed	Natrum mur 1 M 1 dose given	Complaint reappear
9.	24-12-2020	Pain decrease , itching decrease, menses on time	Rubrum for 15 days	Patients condition improving

Table 3- Modified Naranjo Criteria

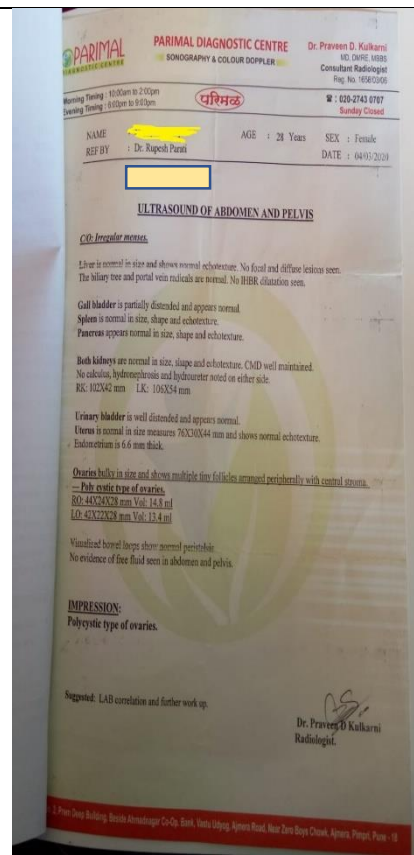
As proposed by the HPUS the clinical data working group (status December 2014, van Haselen 2016)

	Yes	No	Not sure or N/A
1. Was there an improvement in the main symptom or condition for which the homeopathic medicine was prescribed?	+1	0	0
2. Did the clinical improvement occur within a plausible timeframe relative to the drug intake?	+1	0	0
3. Was there an initial aggravation of symptoms? (Need to define in glossary)	0	0	0
4. Did the effect encompass more than the main symptom or condition, i.e. were other symptoms ultimately improved or changed?	0	0	0
5. Did overall wellbeing improve? (suggest using validated scale)	+2	0	0
6 (A) Direction of cure: did some symptoms improve in the opposite order of the development of symptoms of the disease?	+1	0	0
6 (B) Direction of cure: did at least two of the following aspects apply to the order of improvement of symptoms: - from organs of more importance to those of less importance - from deeper to more superficial aspects of the individual - from the top downwards	1	0	0
7. Did "old symptoms" (defined as non-seasonal and non-cyclical symptoms that were previously thought to have resolved) reappear temporarily during the course of improvement?	0	0	0
8. Are there alternate causes (other than the medicine) that – with a high probability- could have caused the improvement? (Consider known course of disease, other forms of treatment, and other clinically relevant interventions)	0	0	0
9. Was the health improvement confirmed by any objective evidence? (e.g. lab test, clinical observation, etc.)	+1	0	0
10. Did repeat dosing, if conducted, create similar clinical improvement?	+1	0	0

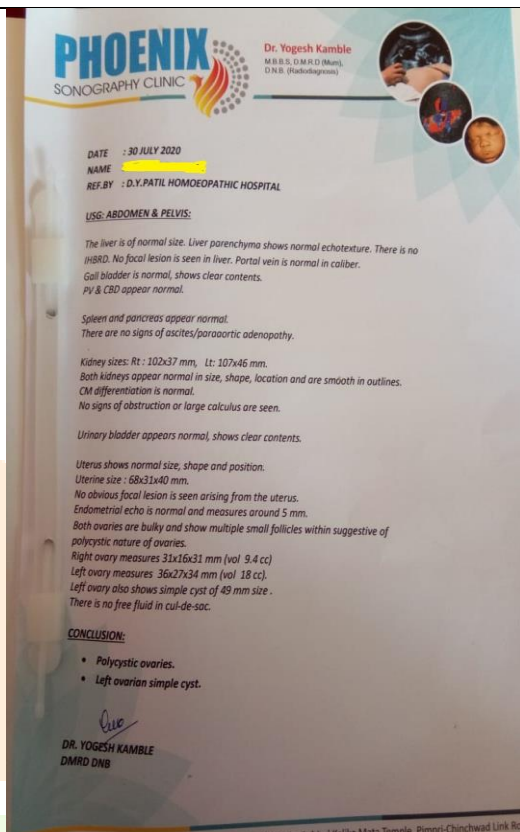
Maximum Score = 12 Minimum Score = - 3 Total= +8

USG Reports - Table 4

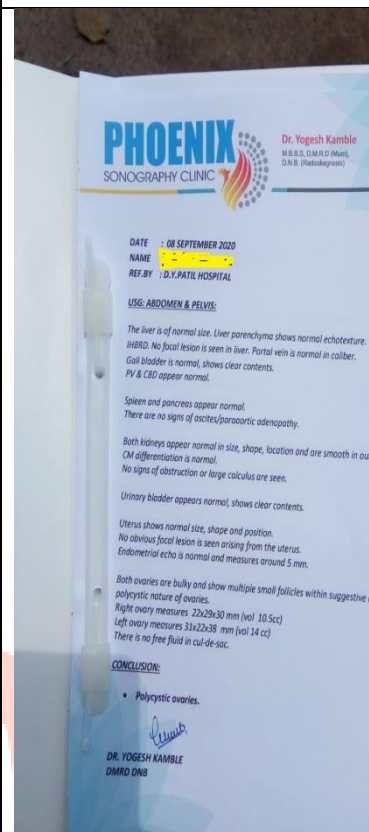
USG Report date -3-3-2020



USG Report date – 30-7-2020



USG Report date –08 09-2020



Before Treatment

After Treatment

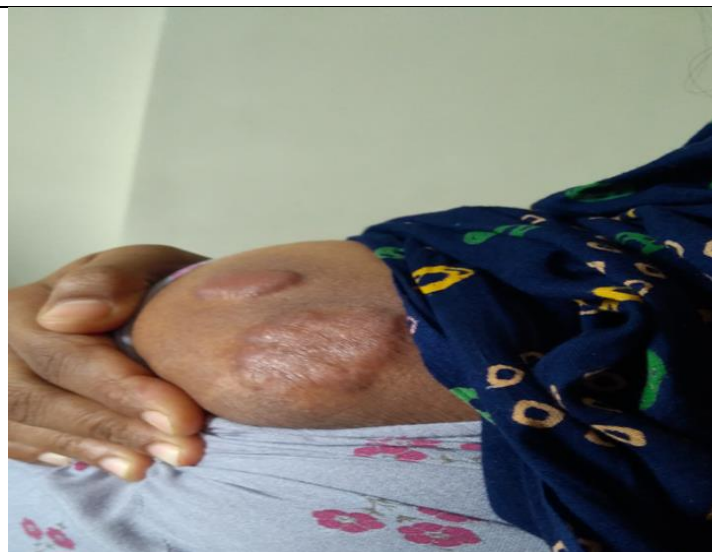
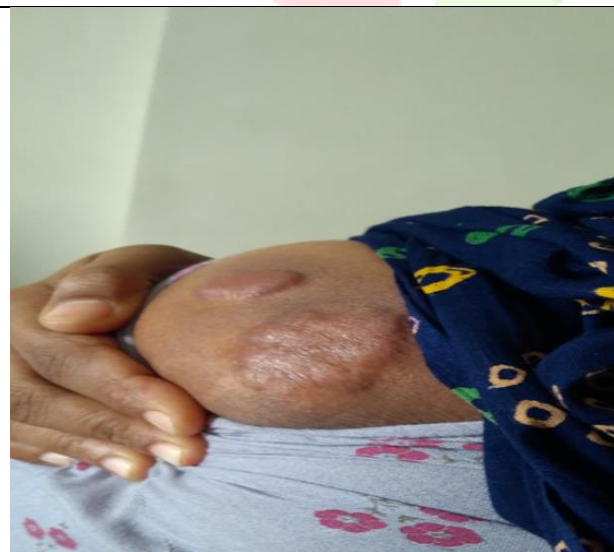
Figure 1

Figure 2

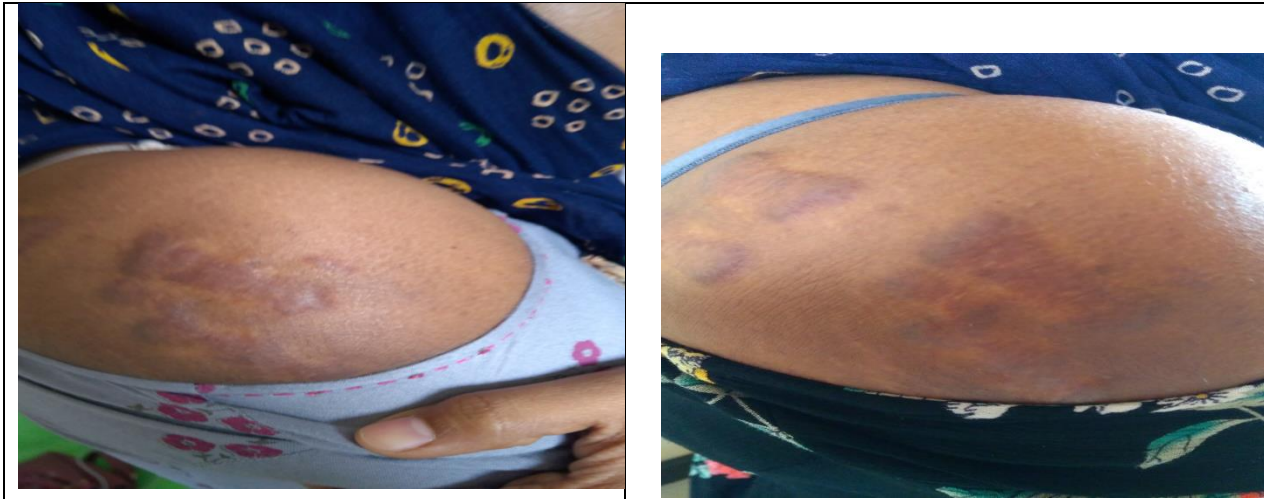

Figure 3

Figure 4

Result – The skin lesions on back, shoulder trunk, thigh showed improvement with Natrum mur 200c. skin eruptions markedly improved and size of keloids is also decreasing within 8 months of constitutional Homoeopathic treatment along with this there is decrease in size of cyst of ovary as shown in reports it shows homoeopathy has positive role in Management of cases of Keloid and PCOD, as it is single case study, detail case control study and research required.

Discussion –

This case report describes the importance of single individualized constitutional homoeopathic medicine in case of keloid and PCOD. The task of treating Keloids by conventional oral medicine, external application was unsatisfactory, and an entire failure that the patient restored to homoeopathic treatment to get permanent cure.

The remedy Natrum Mur 200 was selected on basis of mental and physical generals and characteristic particulars, hardness of keloids is decreasing, with relief of complaints also PCOD size of cyst is decrease with improvement in patients complains weight is also decrease by 5 kg in 8 months. patient shows marked improvement after homoeopathic treatment.

Conclusion – Homeopathy treat patient as whole, this case shows how we can approach to cure by selecting medicine on the basis of totality of symptoms and person as whole, slow and steady improvement in patient is seen without any recurrence with documentary evidence. This case shows positive role of homoeopathy in treating the pathology of Keloids and PCOD.

Declaration of patient consent – patient consent form is obtained in forms the patient has given her consent for images and report and other clinical information to be reported in journal, patient understand, her name not to be published, and due effect to be made to conceal her identity.

Financial support – Nil

Conflict of interest- Not Declared

BIBLIOGRAPHY-

1. Macfarlane P.S. , Robin Reid , Robin calendar Pathology Illustrated 5th edition
2. Concise pathology- parikrama, line R. Tailorchandrasoma – 3rd edition
3. Diagnosis and Management of Dermatologic Disorders Made Easy (including STDs, Leprosy, HIV and AIDS) by SK Punshi
4. ABC of Dermatology (6th Edition) edited by Rachael Morris
5. Clinical Dermatology by Thomus Habib
6. Textbook of Cosmetic Dermatology Edited By Robert Baran,Howard I. Maibach.
7. Shaws Textbook of Gynaecology(16th edition)
8. D C Datta Textbook Of Gynaecology
9. Indian Journal Of Dermatology.
10. Talbot IC. (1996) Walter & Israel General pathology [7th edition]. Elsevier Health Science
11. Cotran, Kumar, Robbins. (2001) *Robbins Pathologic Basis of Disease*. [5th edition] Prism books (Pvt) Ltd. Bangalore,
12. Govan, Macfarlane, Callander. (2011) *Pathology Illustrated*, [7th edition]. Longman Singapore Publishers (pvt) Ltd
13. Harsh Mohan. (2015) *Text book of pathology* [7th edition]. Jaypee Brothers, New Delhi
14. Karyakarte R, Damle A. (2012) *Medical parasitology* [3rd edition] .BOOKS & ALLIED (P) Ltd, Kolkata
15. Boericke W. Pocket Manual of Homoeopathic Materia Medica and Repertory. Reprint Edition. New Delhi: B Jain Publishers (P) Ltd.; 1998. p. 325-8. ↗
16. Dr. KP.S. Dhama& Suman Dhama, Homeopathy The Complete Book ,UBS Publisher page no 300-301.
17. Dr. Subrata Kumar Banerjea , Miasmatic prescribing, Bjainpublicatiojn ltd. Page no 180

