



## Study of facial nerve palsy in Otorhinolaryngological disorders in Jharkhand population

Abhinav Paul Minj<sup>1</sup>, Rohit Kumar Jha<sup>2</sup>, Dr. Rajiv Romal Mark (Corresponding Author)<sup>3</sup>

1. Assistant Professor and Head of department of ENT (MMCH) mediniarai Medical College and Hospital Palamu, Jharkhand.

2. Assistant Professor, Department of ENT MGM Medical College Jamshedpur-831020.

3. Senior Resident, Dept of ENT, MMCH, Palamu. Jharkhand.

### Abstract

**Background:** Facial nerve palsy is an uncommon but significant complication of ORL disorders; surgical eradication of disease is the most viable way to overcome Facial Palsy.

**Method:** Out of 26, 16 had left side facial palsy 10 had right side palsy associated with ORL disorders. CT scan, Routine Blood examination was carried out to know any other pathologies. It was LMN (Lower motor Neuron) grade-2 type palsy. Otosopic examination was done to rule out, tympanic membrane perforation, suppuration, Herpes Zoster.

**Results:** 12 (46.1%) Otolgia, 5 (19.2%) impaired hearing, 4 (15.3%) were ear discharge were major clinical manifestation, 8 (30.7%) CSOM, 8 (30.7%) Otitis, Media 3 (11.5%) AoM, 3 (11.5%) Otitis externa were major clinical findings.

**Conclusion:** These findings which cause facial nerve palsy require surgical corrections and onset of antibiotic treatment. Hence this pragmatic approach will help the ENT surgeons for efficient approach.

**Key words:** LMN palsy CSOM, AoM, Otoscopy, Electro neuro Myography (ENMG), Jharkhand.

## Introduction

Facial nerve palsy is an uncommon but significant complication in Otolaryngeal disorders (ORL), Although the prevalence of facial nerve paralysis has decreased due to use of antibiotics, but the prevention there of remains challenging problem. It was been reported that, frequency of facial nerve palsy in ORL disorders ranges from 0.16 to 5.1% in India and abroad <sup>(1)(2)</sup>. Although the mechanism of facial Nerve paralysis as result of ORL, disorders is not fully understood. Treatment recommendations have focussed on both antibiotic treatment as well as surgery including myringotomy, mastoidectomy and nerve decompression in order to re-establish the physiological state of facial nerve <sup>(3)</sup>. Surgical eradication of disease is the most viable way to overcome facial nerve palsy ,however there is a lack of data from which significant conclusion on the surgical in application of surgical treatment for these patients stems from lack of predictors for facial nerve palsy, remission <sup>(4)(5)</sup>. Hence attempt is made to evaluate the clinical manifestation and clinical findings.

## Material and Method

24 (Twenty four) patients aged between 20 to 45 years visiting ENT department of Mediniarai Medical College and hospital palamu were studied.

**Inclusive criteria:** Patients with ORL (Otolaryngology) disorder having facial nerve palsy were selected for study.

**Exclusion Criteria:** Patients with type-II DM, previously undergone ORL surgery, immune compromised surgery were excluded from study.

**Method:** Every patient was under gone CT scan study Routine Blood examination, out of sixteen (16) had left and ten (10) had right side palsy patients, complained drooling of saliva from either right or left side of the mouth while drinking water

and eating food, along with asymmetry of the face and inability close eyes some patients right and some left eye on facial examination it was found that Facial palsy was Lower Motor Neuron type, grade-2 as per Brackmann scale.

Local examination was done to rule out Herpes zoster Otososcopic examination to study perforation in quadrant of tympanic membrane, suppuration. Hearing test was revealed by Tuning forks test. The prognosis of paralysis was based on electric test with the Hilger stimulator or electro-neurographic study.

The duration of study was January-2020 to December-2020.

**Statistical analysis:** Various clinical manifestations of patients and diagnosis were classified with percentage. The statistical analysis was carried out in SPSS software. The ratio of the male and female was 2:1.

### Observation and Results

**Table-1:** Clinical manifestation of patients of facial palsy with Otolaryngeal disorders – 12 (46.1%) Otolgia, 5 (19.2%) impaired hearing, 4 (15.3%) had ear discharge, 2 (3.84%) had dysphasia 1 (3.84%) had Jaw pain, 1 (3.84 %) had nasal bleeding, 1 (3.84 %) had throat pain.

**Table-2:** Clinical findings of facial palsy patients with Otoralangeal disorders – 8 (30.7%) had COSM, 8 (30.7%) had AOMS, 3 (11.5%) Otitis externa, 3 (11.5%) Ramsay Hunt syndrome, 1 (3.84%) Herpes zoster 1 (3.84%) chronic rhino sinusitis / anterior uveitis 1 (3.84%) acute tonsillitis 1 (3.84%) sino-neural hearing loss.

### Discussion

The present study of facial Nerve palsy in Otolaryngeal disorders manifestations were 12 (46.1%) Otolgia, 5 (19.2%) impaired hearing, 4 (15.3%) ear discharge, 2 (7.69%) dysphasia, 1 (3.84%) jaw pain, 1 (5.84%) Nose bleeding, 1 (3.84%) throat pain (Table-1). The clinical finding (diagnosis) was 8 (30.7%) COSM, 8 (30.7%) Otitis Media, 3 (11.5%) AoM, 3 (11.5%) Otitis externa, 1 (3.84%) Ramsdy-Hunt syndrome, 1 (3.84%) Herpes zoster, 1 (3.84%) Chronic rhino sinusitis / anterior uveitis, 1 (3.84%) acute tonsillitis, 1 (3.84%) sensori neural hearing loss

(Table-2). These findings are more or less in agreement with previous studies (5)(6)(7).

Acute inflammation of the middle ear is one of the most common diseases observed in childhood and in early adulthood tympanic cavity and mastoid, if untreated inflammation spreads to neighbouring structures. Auditory tube, palatine tonsil, jaw joints will also involve causing peripheral facial palsy (9). It is also reported that, peripheral facial nerve palsy is secondary to otitis media (10).

The possible factors causing facial nerve palsy in Acute suppurative otitis media are likely to alter the middle ear micro environments, such as elevated pressure, osteitis or acute inflammation may affect physiology of facial nerve (11). It is also reported that retrograde infection within the bony canal of facial nerve or retrograde infection within tympanic cavity can spread via chorda-tympani nerve to facial nerve. It was also noted that, reduced immunity due to latent viral infection in middle may be the cause of facial palsy. It is also observed that, Demyelination of facial nerve secondary to the presence of bacterial toxins.

It was a theory by Tschiasny's infections causing facial nerve palsy spread through dehiscence and neuro-vascular communication between middle ear and facial nerve (12). Moreover anatomical variations of facial nerve may prone to severe infection may lead to facial nerve palsy. Another theory suggests that, compression of blood vessels that nourish the facial nerve may lead to palsy of facial nerve due to ischemia/infarction.

Most common organism recovered from cultures of patients with suppurative complications of acute otitis media (AOM) have been Gram positive cocci, (S. pneumonia and staphylococcal series).

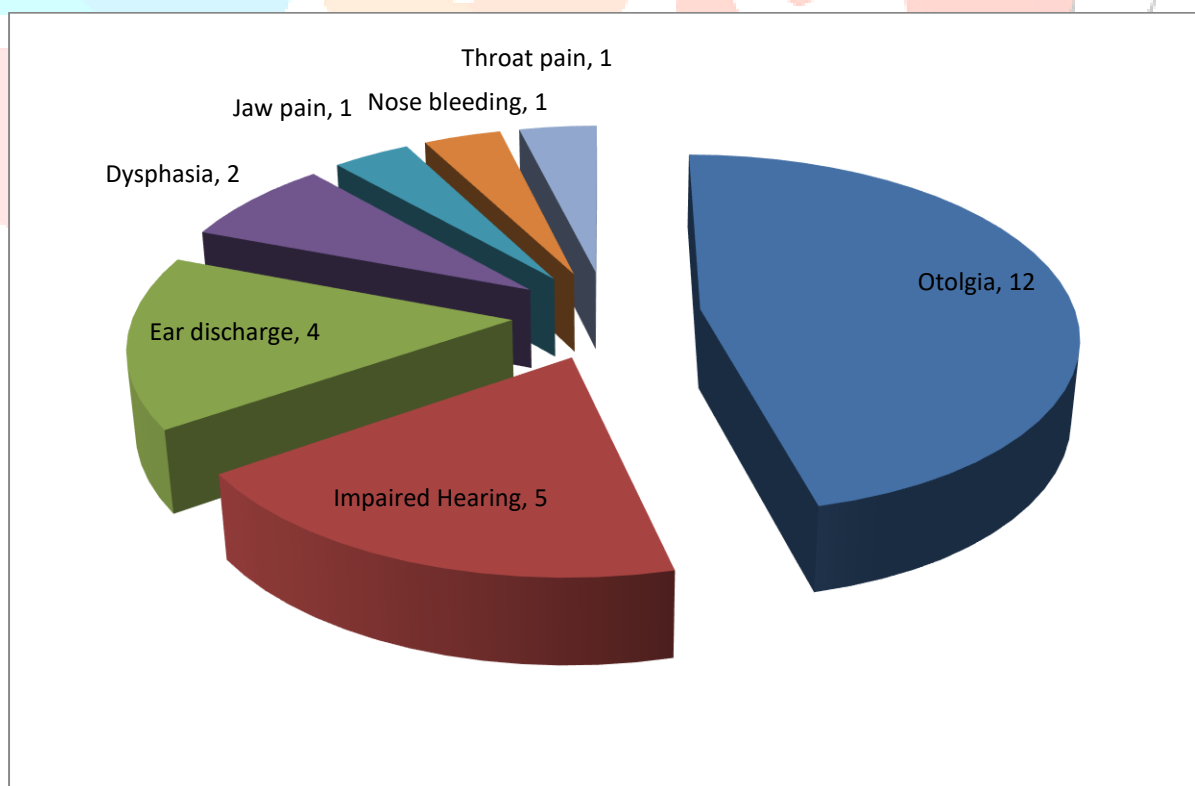
Broad spectrum 3<sup>rd</sup> generation cephalosporin's have strong meningeal penetration can be useful in first line of treatment but non-responded cases require surgical innervations.

### **Summary and conclusion**

The present study of facial nerve palsy associated ORL disorders can be managed with 3<sup>rd</sup> generation antibiotic with cortico-steroids as first line of treatment careful management with early surgical intervention has proven to have a decisive effect on the recovery of facial function. But this demands further genetic, immunological nutritional, patho-physiological pharmacological, neuro-vascular studies because exact pathogenic of facial nerve palsy is still un-clear.

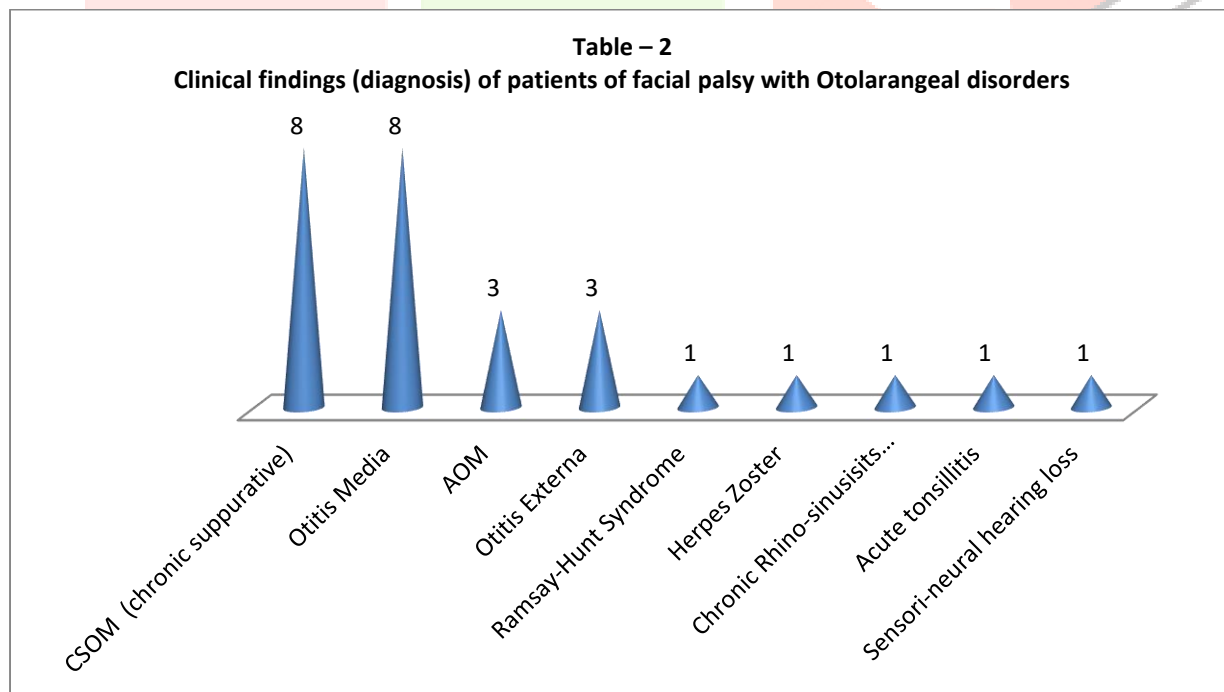
**Table – 1****Total No of Patients: 26****Clinical manifestation in patients of facial Nerve palsy with Otolarangeal disorders**

Sl No	Manifestations	No. of patients (26)	Percentage (%)
1	Otolgia	12	46.1 %
2	Impaired Hearing	05	19.2 %
3	Ear discharge	04	15.3
4	Dysphasia	02	7.69 %
5	Jaw pain	01	3.84 %
6	Nose bleeding	01	3.84 %
7	Throat pain	01	3.84 %



**Table – 2****Clinical findings (diagnosis) of patients of facial palsy with Otolarangeal disorders**

SI No	Clinical findings (Diagnosis)	No of Patients (26)	Percentage (%)
1	CSOM (chronic suppurative)	8	30.7 %
2	Otitis Media	8	30.7 %
3	AOM	3	11.5 %
4	Otitis Externa	3	11.5%
5	Ramsay-Hunt Syndrome	1	3.84 %
6	Herpes Zoster	1	3.84 %
7	Chronic Rhino-sinusitis /anterior uveitis	1	3.84 %
8	Acute tonsillitis	1	3.84 %
9	Sensori-neural hearing loss	1	3.84 %



## References

1. Pollock RA, Brown LA – Facial paralysis in otitis Media. In Graham MD. House WF, editors – Disorders of facial nerve 1982, New York, Raven press-221-4
2. Suvic DL, Djeric DR – Facial paralysis clin. otolaryngeal Allied science 1989, 14, 515-7.
3. Fiss DM, Keiberman A – Medical sequel and complications of acute otitis Media. Paed infect Dis. J. 1994, 13(1), 34-40.
4. Yetiser S, Tosun F – Facial nerve paralysis due to chronic Otitis Media. Otol. Neurotol 2002, 23, 580-8.
5. Hendersan PE, Baldone SC – Facial nerve palsy secondary to acute otitis media J Am. Osteopath. Assoc. 1989, 89, 207-10.
6. Ellefsen B, Bonding P – Facial palsy in acute otitis media. Clin. otolaryngol 1996, 21, 393-95.
7. House JW, Brackmann DE – Facial palsy grading system Otolaryngology Head Neck Surg. 1985, 93, 146-147.
8. Kamit Suka M, Feldman K- Facial paralysis associated with otitis Media Paed. inf. Dis. J. 1985, 4, 682-684.
9. Sriranga Prasad, K V Vishwas – Facial Nerve paralysis in acute suppurative otolaragol. Head Neck Surg. 2017, 69(1), 58-61.
10. Chan CY, Cass SP – Management of facial nerve injury due to temporal bone trauma Am. J. Otol. 1999, 20, 96-114.
11. Joseph EM, Sperling NM – Facial nerve paralysis in acute otitis media cause and management revisited Otolarangol. Head Neck Surg. 1998, 118, 694-696.
12. Nagar GT, Proctor B – Anatomic variations and anomalies involving the facial canal otolaryngology Clin. N. Am. 1991, 24, 531-553.