



A HOMOEOPATHIC APPROACH FOR ASTHMA WITH THERAPEUTICS

Dr. INDRA GAURAV SAXENA¹, Dr. SUNIL R. THUMAR², Dr. LEKHIKA SINGH³, Dr. CHESTA SINGH⁴,

Dr. DEBJANI DEBNATH⁵

¹M.D. (PGR), Department of Repertory, Swasthya Kalyan Homoeopathic Medical College & Research Centre, Sitapura, Jaipur, Rajasthan, India.

²M.D. (PGR), Department of Practice of Medicine, Swasthya Kalyan Homoeopathic Medical College & Research Centre, Sitapura, Jaipur, Rajasthan, India.

³M.D. (PGR), Department of Paediatrics, Swasthya Kalyan Homoeopathic Medical College & Research Centre, Sitapura, Jaipur, Rajasthan, India.

⁴M.D. (PGR), Department of Homoeopathic Pharmacy, Swasthya Kalyan Homoeopathic Medical College & Research Centre, Sitapura, Jaipur, Rajasthan, India.

⁵M.D. (PGR), Department of Paediatrics, Swasthya Kalyan Homoeopathic Medical College & Research Centre, Sitapura, Jaipur, Rajasthan, India.

1. ABSTRACT: Asthma is a chronic inflammatory disorder of the airways that causes recurrent episodes of wheezing, breathlessness, chest tightness, and cough, particularly at night and/or early in the morning. The main aim of this article is how to use pathophysiological action of homoeopathic medicine to treat acute exacerbation of asthmatic attacks.

KEYWORDS: Homoeopathy, Asthma, Pathophysiology, Homoeopathic Therapeutics.

2. INTRODUCTION: ^[1] ^[2] ^[13]

➤ DEFINITION:

Asthma is a chronic inflammatory disorder of the airways that causes recurrent episodes of wheezing, breathlessness, chest tightness, and cough, particularly at night and/or early in the morning.

Nearly 5-10% of the world's population at some stage during life suffers from asthma. The disease can occur at any age, but in a majority it starts before the age of 10 years. It is more common among boys up to the time of adolescence.

It has classified in two types.

1. Atopic (External trigger factor)
2. Non Atopic (Internal trigger factor)

⇒ PATHOPHYSIOLOGY:

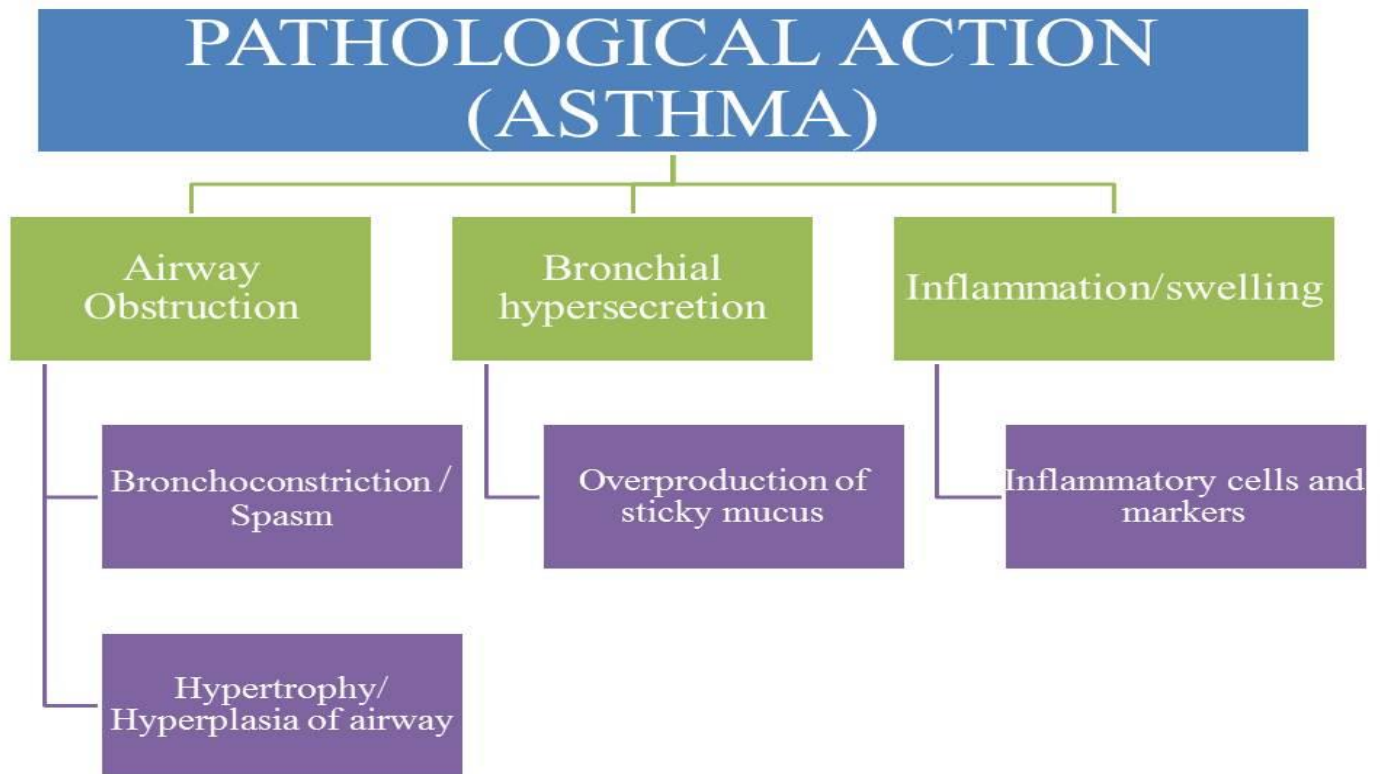


Figure 1 – PATHOLOGICAL ACTION

Pathophysiology

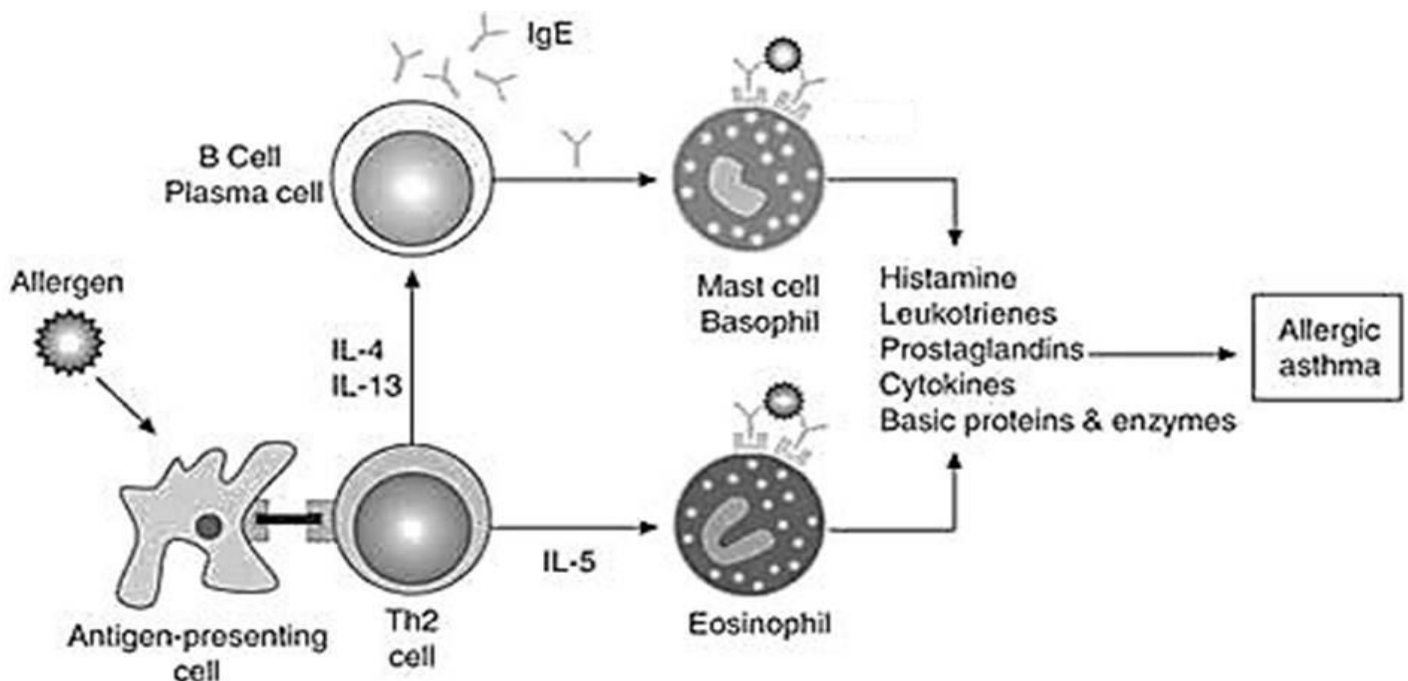


Figure 2 – PATHOPHYSIOLOGY

❖ **Airway Obstruction**▪ **Bronchoconstriction/ Spasm**

- Due to activation of parasympathetic nervous system postganglionic parasympathetic fibers will release acetylcholine (ACh).
- It will work on smooth muscles layer surrounding bronchi via M3 receptor.
- It helps muscle contraction and will lead to decrease diameter of bronchus as well as increase its resistance.

▪ **Hypertrophy/ Hyperplasia of airway**

- Continuous triggering of airway by allergens or inflammatory mediators may increase smooth muscle size with increase numbers of mucous glands.

❖ **Bronchial hyper-secretion**▪ **Overproduction of sticky mucus**

- Due to recurrent stimulation of parasympathetic activation and ACh release may produce mucus secretion in bronchi.
- Recurrent stimuli by inflammatory markers may also produce over production of sticky mucus.
- In case of allergens, infection and respiratory problem produce excessive mucus production.
- It will lead to bronchoconstriction.

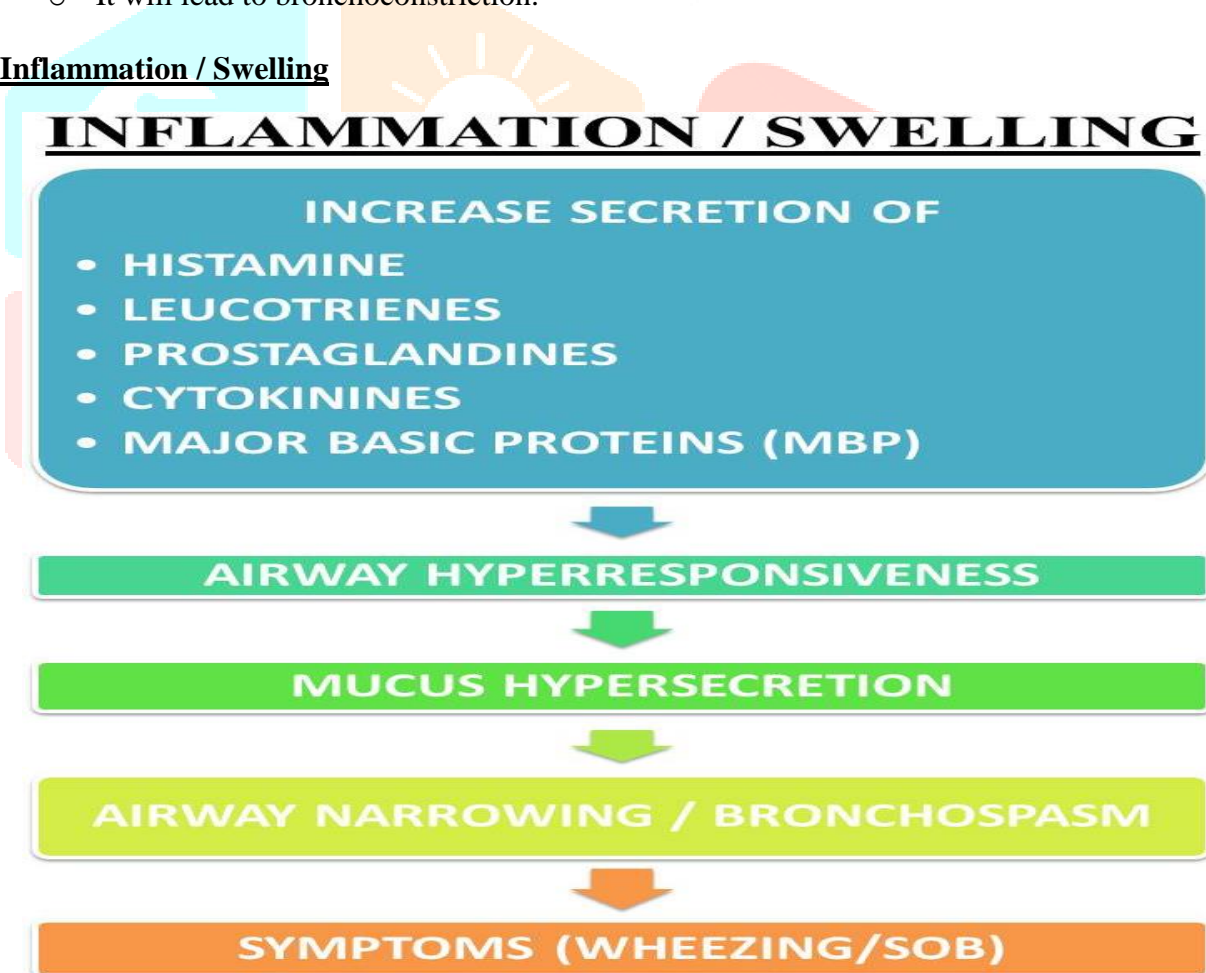
❖ **Inflammation / Swelling**

Figure 3 – Inflammation

➤ CLINICAL MANIFESTATION

- Wheezing
- Dyspnea
- Cough
- Chest tightness
- Excessive mucus secretion which is white, thick, gelatinous
- Rapid and deep respiration
- Prolong expiration time

➤ DIAGNOSIS

- History
- Physical examination (bronchial wheezing)
- Clinical examination (wheezing sound)
- Allergic blood test / skin allergic test
- Absolute Eosinophilic Count
- Serum IgE level
- PFT (reduce FEV)
- Radiography

➤ DIFFERENTIAL DIAGNOSIS

Asthma is easy to recognize in a young patient without comorbid medical conditions who has exacerbating and remitting airway obstruction accompanied by blood eosinophilia. A rapid response to bronchodilator treatment is usually all that is needed to establish the diagnosis. However, in the patient with cryptic episodic shortness of breath, an elevated FENO can help establish a diagnosis of asthma. However, in the absence of an elevated FENO, other causes of wheezing (Table 1) should be investigated.

Table 1- DIAGNOSIS OF SELECTED WHEEZING ILLNESSES OTHER THAN ASTHMA

DISTINGUISHING FEATURES	
UPPER AIRWAY DISEASES	
Postnasal drip syndrome	History of postnasal drip, throat clearing, nasal discharge; physical examination shows oropharyngeal secretions or cobblestone appearance to mucosa
Epiglottitis	History of sore throat out of proportion to pharyngitis; evidence of supraglottitis on endoscopy or lateral neck radiographs
Vocal cord dysfunction syndrome	Lack of symptomatic response to bronchodilators, presence of stridor plus wheeze in absence of increased $P(A - a)O_2$; extrathoracic variable obstruction on flow-volume loops; paradoxical inspiratory or early expiratory adduction of vocal cords on laryngoscopy during wheezing; this syndrome can masquerade as asthma, be provoked by exercise, and often coexists with asthma
Retropharyngeal abscess	History of stiff neck, sore throat, fever, trauma to posterior pharynx; swelling noted by lateral neck or CT radiographs
Laryngotracheal injury due to tracheal cannulation	History of cannulation of trachea by endotracheal or tracheostomy tube; evidence of intrathoracic or extrathoracic variable obstruction on flow-volume loops, neck and chest radiographs, laryngoscopy, or bronchoscopy

Neoplasms	Bronchogenic carcinoma, adenoma, or carcinoid tumor is suspected when there is hemoptysis, unilateral wheeze, or evidence of lobar collapse on chest radiograph or combinations of these; diagnosis is confirmed by bronchoscopy
Anaphylaxis	Abrupt onset of wheezing with urticaria, angioedema, nausea, diarrhea, and hypotension, especially after insect bite, in association with other signs of anaphylaxis such as hypotension or hives, with the administration of drug or intravenous contrast agent, or with family history
SMALL AIRWAY DISEASES	
COPD	History of dyspnea on exertion and productive cough in cigarette smoker; because productive cough is nonspecific, it should be ascribed to COPD only when other cough-phlegm syndromes have been excluded, forced expiratory time to empty more than 80% of vital capacity is >4 sec, and there is decreased breath sound intensity, unforced wheezing during auscultation, and irreversible, expiratory airflow obstruction on spirometry
Pulmonary edema	History and physical examination consistent with passive congestion of the lungs, ARDS, impaired lung lymphatics; abnormal chest radiograph, echocardiogram, radionuclide ventriculography, cardiac catheterization, or combinations of these
Aspiration	History of risk for pharyngeal dysfunction or gastroesophageal reflux disease; abnormal modified barium swallow study or 24-hour esophageal pH monitoring
Pulmonary embolism	History of risk for thromboembolic disease, positive confirmatory test results
Bronchiolitis	History of respiratory infection, connective tissue disease, transplantation, ulcerative colitis, development of chronic airway obstruction during months to few years rather than during many years in a nonsmoker; mixed obstructive and restrictive pattern on PFTs and hyperinflation; may be accompanied by fine nodular infiltrates on chest radiograph
Cystic fibrosis	Combination of productive cough, digital clubbing, bronchiectasis, progressive COPD with <i>Pseudomonas</i> colonization or infection, obstructive azoospermia, family history, pancreatic insufficiency, and two sweat chloride determinations >60 mEq/L; some patients are not diagnosed until adulthood, in one instance as late as the age of 69 years; when sweat test is occasionally normal, definitive diagnosis may require nasal transepithelial voltage measurements and genotyping
Carcinoid syndrome	History of episodes of flushing and watery diarrhea; elevated 5-hydroxyindoleacetic acid level in 24-hour urine specimen
Bronchiectasis	History of episodes of productive cough, fever, or recurrent pneumonias; suggestive chest radiographs or typical chest CT findings; ABPA should be considered when bronchiectasis is central
Lymphangitic carcinomatosis	History of dyspnea or prior malignant neoplasm; reticulonodular infiltrates with or without pleural effusions; suggestive high-resolution chest CT scan; confirmed by bronchoscopy with biopsies
Parasitic infections	Consider in a nonasthmatic who has traveled to an endemic area and complains of fatigue, weight loss, fever; peripheral blood eosinophilia; infiltrates on chest

	radiograph; stools for ova and parasites for nonfilarial causes; blood serologic studies for filarial causes
--	--

3. HOMOEOPATHIC MANAGEMENT

❏ Asthmatic attack is acute, rapid progressive for short duration occurs but it develops chronically. So homoeopathy; permanent cure possible in chronic case. In acute exacerbation of symptoms in Asthmatic condition, homoeopathy offer best results.

❏ Here indication some homoeopathic medicine on the base of pathophysiological action.

♣ **ACONITUM NAPELLUS**^{[3][5][6][11]}

- First remedy for inflammation, only functional disturbance not pathological change.
- Vagi. Act upon respi. Center, direct depressant and paralysis. Respiratory organs. Asthma from active hyperaemia of lung.
- It is a remedy for acute inflammation and congestion.
- Anticholinergic effect due to voltage gated na⁺ channels in axon close-nm transmission decrease and associate with reduce ach release.

✚ **INFERENCE:** Bronchoconstriction/spasm.
Inflammation of airway.

♣ **ASPIDOSPERMIA**^[3]

- Digitalis of Lung. Remove Temporary Obstruction To The Oxidation Of The Blood By Stimulating Respiratory Center And Increase Oxygen In Blood.

✚ **INFERENCE:** Bronchoconstriction/spasm.

♣ **ADRENALIN**^{[3][7][12]}

- Depression of respiratory center, acute congestion of lung, asthma.
- Increase of respiratory movements, soon followed by suffocation and death from paralysis of medulla and pneumogastric.
- Chief therapeutic use vasoconstriction action, acute congestion of lung, asthma.

✚ **INFERENCE:** Bronchoconstriction/spasm.

♣ **ARSENIC ALBUM**^{[3][5]}

- Air passage constricted. Wheezing respiration.
- Action upon pneumogastric nerve, producing congestion of all the air passages, according this congestion we have spasms of the muscles of the lungs with violent dyspnea. It acts on M.M. of air passages, producing tracheobronchial catarrh. Neurobronchial asthma.

✚ **INFERENCE:** Bronchoconstriction/spasm.

♣ **BLATTA ORIENTALIS**^{[3][4][10]}

- A remedy for asthma. Especially when associated with bronchitis.
- Useful in case of bronchitis and phthisis where there is much dyspnea.
- Anti-asthmatic and anti-anaphylactic effect of blatta orientalis MT. Mast cell stabilization, suppression of igE and eosinophil count.

✚ **INFERENCE:** Inflammation of airway.

♣ **IPECACUANHA**^{[3][4][5][6][8][9]}

- Ramification of pneumogastric nerve, producing spasmodic irritation in chest and stomach, dyspnea, constant constriction in chest. Asthma – difficult shortness of breathing.
- Spasmodic asthma, with great constriction in the throat and chest, with which a particular kind of wheezing noise is heard. To arrest the paroxysms of asthma, especially in children.
- Gasps for breath. Asthma. Suffocative attacks from foreign substance in wind pipe.
- Spasmodic asthma, with contraction of the larynx.
- Spasmodic form of asthma, wheezing, shortness of breath, filling of suffocation.
- Mild, continuous, asthmatic condition with wheezing, for days, which suddenly severe with spasmodic constriction of the trachea, causing status asthmaticus.

✚ **INFERENCE:** Bronchoconstriction/spasm.

♣ **SPONGIA TOSTA**^{[3][4][5]}

- Marked symptoms of the respiratory organs, cough, croup, etc. Bronchial catarrh, with wheezing, asthmatic cough, worse cold air, with profuse expectoration and suffocation.
- Suffocative attacks of breathing (as in asthma) without any mucus rattle.
- Respiratory organs. Difficult respiration, as if a plug were sticking in the larynx, and the breath could not get through, on account of constriction of the larynx. [Chronic cases, with glandular affections.] Mucous Membrane. Inflammation of mucous membrane of larynx and trachea, with great hoarseness, aphonia, and dry, barking cough, and obstruction of respiration, as if a plug were there.

✚ **INFERENCE:** Inflammation of airway.

Bronchoconstriction.

Hypertrophy & hyperplasia of airway.

Bronchial hypersecretion.

♣ **STANNUM**^{[3][5]}

- Chronic bronchial and pulmonary condition, characterized by profuse muco-purulent discharges.
- Act on bronchioles, producing catarrhal inflammation, and profuse muco-purulent expectoration, with dilatation of bronchi, and complete exhaustion of the nerves of the lungs.

✚ **INFERENCE:** Bronchial hyperplasia/ hypertrophy.

Inflammation of air way.

♣ **SAMBUCUS NIGRA**^{[5][6][8]}

- Respiratory mucous membrane, producing catarrhal congestion and inflammation, asthmatic phenomena, and laryngismus stridulus. Suffocative attacks; asthma of millar, after midnight much mucus in bronchi.
- Sudden suffocation, whistling breathing spasms of glottis.
- Rapid and laborious respiration with loud wheezing.

✚ **INFERENCE:** Bronchoconstriction/spasm.

Inflammation of airway.

Bronchial hypersecretion.

CONCLUSION

Homoeopathy offer excellent treatment for Asthma. This article shows how to use pathophysiological action of homoeopathic medicine to treat acute exacerbation of asthmatic attacks. Many stalwart have given direction Homoeopathic treatment of Asthma. The above therapeutics medicines are used frequently in Asthma with good results.

REFERENCE

1. Aster. Robbins and Cotran Pathologic Basis of Disease. Ninth edition. Philadelphia, PA: Elsevier/Saunders, 2015.
2. Walker RB, Colledge RN, Ralston HS, Penman DI. Davidson's Principles and Practice of Medicine. 22nd Edition. China:Churchill Livingstone Elsevier;2014.
3. Boericke W. Boericke's New Manual Of Homoeopathic Materia Medica With Repertory, Third Revised & Augmented Edition, B. Jain Publisher Pvt. Ltd, New Delhi, 2008.)
4. Clarke JH. A Dictionary of Practical Materia Medica, Similia (Version 2.31)
5. Burt, W. H.. Physiological Materia Medica. India, Jain, 2003.
6. Phatak SR. Materia Medica of Homoeopathic Medicines, 2nd Edition Reprint Edition, B. Jain Publisher Pvt. Ltd, New Delhi, 2005.
7. Murphy R.Lotus Materia Medica, Similia (Version 2.31).
8. Das RBB. Select Your Remedy, 28th Revised Edition, Indian Books & Periodicals Publishers, Delhi, October 2018.
9. Soni D. The Golden Thread Of Homoeopathic Medicine - An Ingenious Revelation Of Homoeopathic Materia Medica Vol 1, B. Jain Publisher Pvt. Ltd, New Delhi, 2019.
10. <https://pubmed.ncbi.nlm.nih.gov/21784330>
11. <https://www.sciencedirect.com/topics/pharmacology-toxicology-and-pharmaceutical-science/aconitum>
12. Concordant Materia Medica Edition 2, Similia (Version 2.31).
13. Goldman L, Ausiello D. Cecil medicine. 23rd edition. Saunders, an Imprint of Elsevier. 2007.