



Effects of Topical Vitamin C on Collagen Deposition in Mid Dermal Burns in Wistar Rats

Fajar Dwijayanto¹, Frank Bietra Buchari², Utama Abdi Tarigan²

¹Department of Surgery, Faculty of Medicine, Universitas Sumatera Utara – H. Adam Malik Hospital, Medan, Indonesia

²Consultant of Plastic, Aesthetic & Reconstructive Surgery, Department of Surgery, Faculty of Medicine, Universitas Sumatera Utara – H. Adam Malik Hospital, Medan, Indonesia

Abstract

Background: Burns are a global public health problem caused by the high rate of burn mortality and morbidity. Based on the medical records of RSUP Haji Adam Malik Medan, there were 353 cases of burns in 2011-2014, the most common cause was flame burn injury.). The optimal concentration of topical vitamin C which has a biologically significant effect with a concentration greater than 8% and a concentration greater than 20% does not have a significant biological effect.

Objective: This study examined the effect of topical vitamin C administration on mid-dermal burns on increased collagen deposition.

Methods: This study is an experimental study. The research design used in this study is a simple experimental design (Post Test Only Control Group Design). A total of 40 samples were analyzed on the 14th day after burns induction consisting of 2 groups, namely 20 samples from the control group and 20 samples from the experimental group (vitamin C).

Results: In the analysis of collagen scores, most cases in the experimental group had moderate and intense collagen scores with 8 samples (40%) of each case. Whereas in the control group, most cases had a focal collagen score (55%). Using the Mann Whitney test, there was a significant difference in collagen scores between the control group and the experimental group ($p = 0.001$).

Conclusion: Vitamin C is effective in the healing process of burns. Topical use of vitamin C can be an option for patients who have large burn areas.

Keywords: Vitamin C, Collagen, Burns

Introduction

Burns are a global public health problem due to the high mortality and morbidity rates of burns. Based on medical record data of RSUP Haji Adam Malik Medan, there were 353 cases of burns in 2011-2014, the most common cause was flame burn injuries (174 cases, 50.4%) (Maulana, 2014). In mid-dermal degree burns, the number of epithelial cells that survive for the re-epithelialization process is very small due to the deep burns so that spontaneous healing of burns does not always occur.

Topical vitamin C is available in the active form of the L-ascorbic acid preparation, which is the most biologically active and widely used and well used in several cosmetic studies and burns (Farris 2009). The optimal concentration of topical vitamin C which has a significant biological effect with a concentration greater than 8% and a concentration of more than 20% does not have a significant biological effect (Farris 2009). Topical preparations currently available in product form range from 10% to 20% vitamin C (Firas 2017). Administration of vitamin C (L-ascorbic acid) is reported to have helped the wound healing process in some surgical areas which can be given by injection, orally or topically.

Topical administration of vitamin C is expected to prevent the absorption of vitamin C in the intestine from being limited by the active transport mechanism. The amount of vitamin C absorbed is small despite high oral and injection preparations. Large doses can cause diarrhea and calcium oxalate renal calculi can form if the urine is acidic (Kristina 2010). Collagen deposition is an increase in the number of collagen fibers as assessed by immunohistochemical examination of the tissue. Vitamin C is needed to cross-link collagen molecules to increase tissue strength, to stimulate collagen genes to synthesize collagen to heal wounds. (Telang 2012). Based on previous research where topical vitamin C can accelerate the healing of burns based on macroscopic observations in Wistar rats, this study examines the effect of topical vitamin C on mid-dermal burns to increase collagen deposition.

Methods

This study is an experimental study to assess the effect of topical vitamin C administration on wound healing in mid-dermal-degree burns in Wistar rats. The research design used in this study was a simple experimental design (Post Test Only Control Group Design). This research was conducted at the Pharmacy Laboratory and Anatomical Pathology Laboratory, University of North Sumatra. The study was conducted from January to November 2020 in healthy Wistar rats weighing 250-300 grams, as many as 40 samples were analyzed on the 14th day after burns induction consisting of 2 groups, namely 20 samples from the control group and 20 samples from the experimental group (vitamin C).

Results

Research data from the entire observation period were in the form of fibroblast values, PMN, the number of blood vessel lumens and collagen deposition. Prior to the statistical test, the normality test was carried out.

Table 1. Analysis of fibroblast scores between experimental and control groups

Group	Fibroblast score					P-value
	None	Focal	Mild	Moderate	Intense	
Control	3	3	7	2	5	0.030*
Vitamin C	1	3	5	9	2	

*Mann Whitney test

In table 1, in the experimental group it appears that most cases fall into the moderate classification with 9 cases (45%). Meanwhile, in the control group, most cases were classified as mild with 7 cases (35%). Using the Mann Whitney test, there was a significant difference in fibroblast scores between the control and experimental groups ($p = 0.03$).

Table 2. Analysis of PMN scores between Vitamin C and control groups

Group	PMN score					P-value
	None	Focal	Mild	Moderate	Intense	
Control	7	6	3	0	4	0.063*
Vitamin C	2	4	5	4	5	

*Mann Whitney test

In table 2, the analysis of PMN scores in the experimental group found that most PMN scores were mild and intense with 5 samples (25%) of each case. Whereas in the control group, most cases did not have a PMN score with 7 cases (35%). From the Mann Whitney test analysis, it was found that there was no significant difference in PMN scores between the control group and the experimental group ($p = 0,063$).

Table 3. Analysis of blood vessel proliferation scores between Vitamin C and control groups

Group	Vascular Proliferation Score					P-value
	None	Focal	Mild	Moderate	Intense	
Control	7	5	3	3	2	0.017*
Vitamin C	0	2	4	6	8	

*Mann Whitney test

In table 2, it can be seen that in the experimental group most cases had an intense score of blood vessel proliferation with a total of 8 samples (40%), whereas in the control group, most cases had no blood vessel proliferation score with 7 cases (35%). From the Mann Whitney analysis, it was found that there was a significant difference in blood vessel proliferation scores between the two groups ($p = 0.017$).

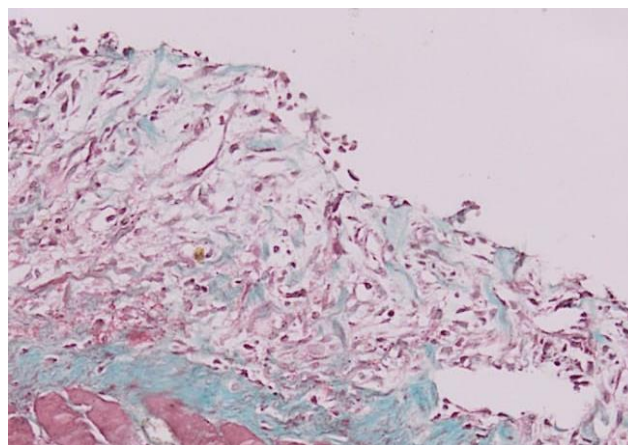


Figure 1. Histology finding of control group using Masson's trichrome stain and 100x magnification. Mild collagen deposition appears in the wound healing process.

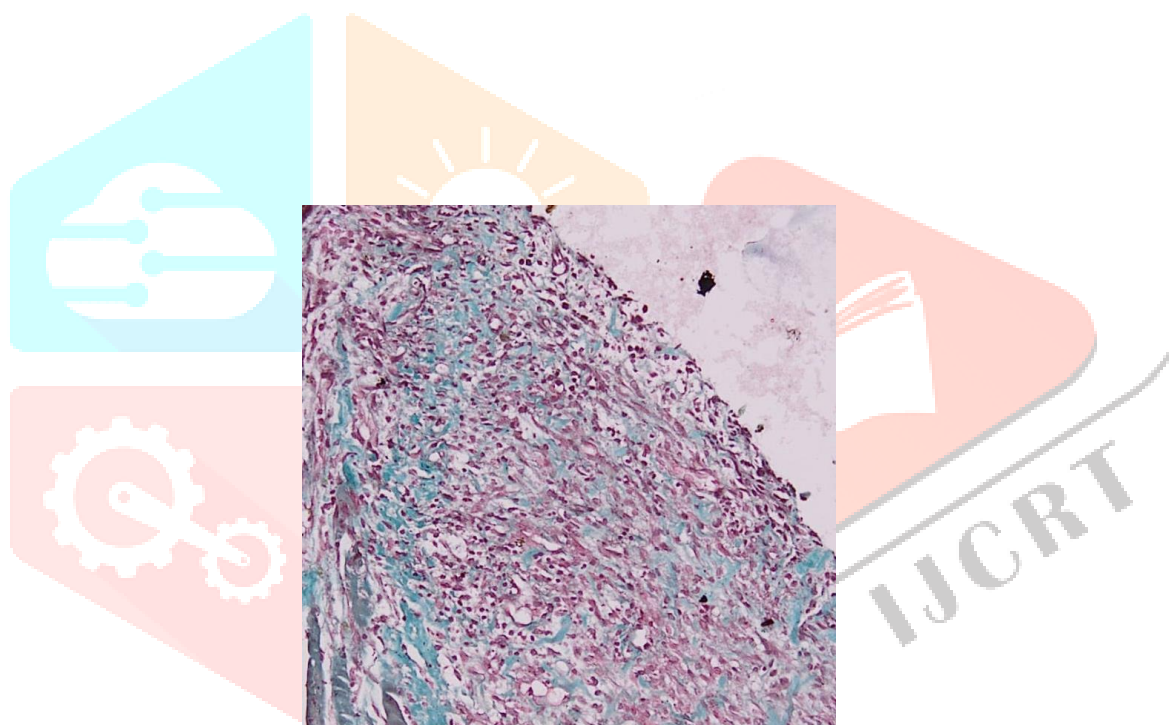


Figure 2. Histology finding of burns of the group given vitamin C using Masson's trichrome stain and 100x magnification. It appears densely composed fibroblasts, numerous blood vessels and moderate collagen deposition in the wound healing process.

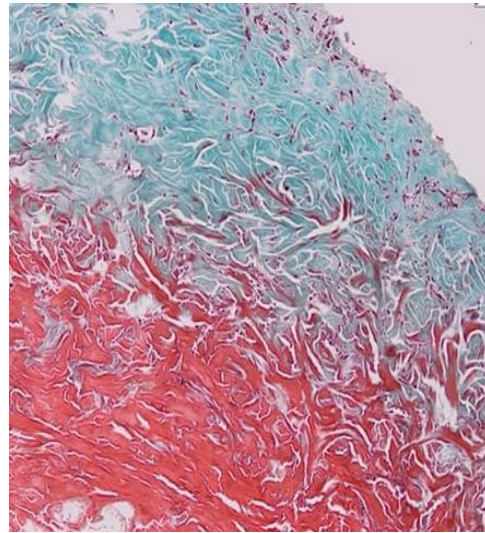


Figure 3. Micro-image burns of the group given vitamin C using Masson's trichrome stain and 100x magnification. Fibroblast fibers, blood vessels and deposition of collagen deposits are visible in the wound healing process.

Table 4. Analysis of collagen scores between experimental and control groups

Group	Collagen score					P-value
	None	Focal	Mild	Moderate	Intense	
Control	1	11	5	1	2	0.001*
Vitamin C	1	1	2	8	8	

*Mann Whitney test

In the collagen score analysis, most cases in the experimental group had a moderate and intense collagen score with 8 samples (40%) of each case. Whereas in the control group, most cases had a focal collagen score (55%). Using the Mann Whitney test, there was a significant difference in collagen scores between the control group and the experimental group ($p=0.001$).

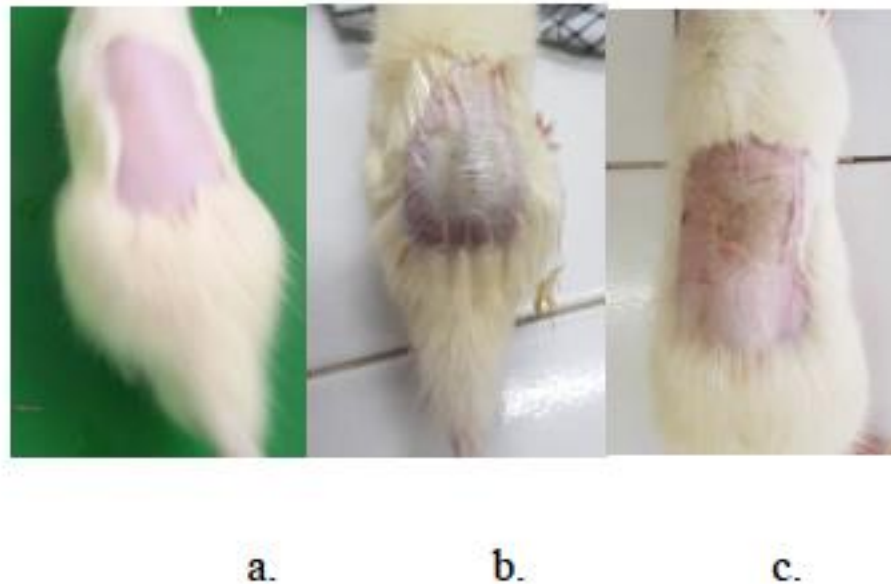


Figure 3. Photo of wistar rats: a. back that has been shaved before the burn is induced, b. after the burn is induced and coated with a transparent dressing, c. 14th day before the skin is harvested.

Discussion

This study proved the effect of topical vitamin C on the healing of mid-dermal burns in wistar rats in the form of increased vascularity, increased fibroblasts and increased collagen on day 14 with histological staining of Hematoxylin Eosin (HE) and Masson's Trichrome (MT). Henderson stated that the use of topical vitamin C accelerates wound healing by stimulating an inflammatory response that causes an increase in the extracellular matrix and granulation tissue, vascularity, fibroblast proliferation and collagen production (Henderson, 2003).

In this study it was found that the number of fibroblasts was significantly higher in the treatment group than in the control group. Whereas in the research conducted by Ozcelik in 2016 where there was no significant difference, even though the fibroblast value was higher in the treatment group (Ozcelik, 2016). Ascorbic acid can stimulate fibroblasts depending on the concentration, at a concentration of 5% it will promote the proliferation of dermal fibroblasts significantly but not at a concentration of 20% (Borzini, 2007).

In the early phase of wound healing, there is an increase in neutrophils and macrophages, cells that stimulate debris and bacterial phagocytosis while producing and releasing growth factors (Adler, 2002). There are several studies that support that application of vitamin C to graft sites accelerates the wound healing process, promotes epithelialization and angiogenesis in skin grafts and donor sites (Venter NG, 2016; Pallua N, 2010). Compared to this study, it was found that the collagen proliferation and deposition scores were higher in the study group with a significant difference. Ozcelik stated that collagen deposition in the control group was lower than the treatment group in the Wistar rat burn study but not significantly (Ozcelik, 2016).

Vitamin C improves epithelial cell differentiation and collagen organization. Vitamin C also enhances the incorporation of biological mesh networks (Pallua N, 2010; Ganio C, 1993). In this study group, the

inflammatory cell infiltration (PMN) was statistically significant difference where the PMN in the control group was higher than the treatment group. This was due to the reduced inflammatory phase and the absence of prolonged inflammation in the wounds treated with vitamin C (Pallua N, 2010; Ozcelik, 2016).

The advantages sought from a dressing that has all the capabilities of preventing loss of fluid and barrier of microorganisms, supporting cell proliferation in wound healing, and enabling proliferation of blood vessels, keratinocyte adhesion, and differentiation are not currently available. Vitamin C has been shown to accelerate the wound healing process in acute traumatic wounds, chronic wounds that do not heal, and incision wounds, and is effective in soft and hard tissue reconstruction (Kazakos K, 2009; Pallua N, 2010; Iesari S, 2015; Carter CA, 2003). Wounds treated with vitamin C showed a shortened inflammatory phase and no prolonged inflammation (Carter CA, 2003).

Conclusion

There were significant differences in fibroblast development, collagen production, and vascular proliferation between the group given vitamin C and the control group. It was concluded that vitamin C was effective in the healing process of burns. Topical use of vitamin C can be an option for patients who have large burn areas.

References

- Anitra, C. and Maggini, S. 2017. Vitamin C and Immune Function. *Nutrients*, 9 : 1211
- Baumann, L. 2007. Skin ageing and its treatment. *J. Pathol.*, 211 : 241–251.
- Clark, R. 2013. The molecular and cellular biology of wound repair. Springer Science & Business Media; 72 : 122.
- Cassie, D. 2011. Platelets. Department of Biostatistic & Epidemiology Collage. of Public Health OUHSC, 42 : 65-67.
- Duarte, T.L., Cooke, M.S., and Jones, G.D. 2009. Gene expression profiling reveals new protective roles for vitamin C in human skin cells. *Free Radic. Biol. Med.*, 46 : 78–87.
- Dubick, MA., Williams, C.2012. High-dose vitamin C infusion reduces fluid requirements in the resuscitation of burn-injured sheep. *Shock.*;242 : 139–44.
- Farris, PK. 2009. Cosmetical vitamins: vitamin C in procedures in Cosmetic Dermatology. 2nd ed. New York Saunders Elsevier,112 : 51–56.
- Henderson, JL. 2003. The effects of autologous platelet gel on wound healing. *Ear Nose Throat J*;82(8):598–602.
- Herndorn, D.N. 2002. Total Burn Care. 2nd ed. Saunders London. 101-169.
- Hoffbrand AV, Moss PAH. 2013. Kapita Selektta Hematologi, edisi 6. EGC. 294-304.
- Juliet M. 2017 The Roles of Vitamin C in Skin Health. *Nutrients*. 9, 866; doi:10.3390/nu9080866 Kremer, T. 2010. High-dose vitamin C treatment reduces capillary leakage after burn plasma transfer in rats. *J Burn Care Res*. 31(3):470-9.

Morris PJ and Malt RA. 2015. Wound healing. New York-Oxford-Tokyo Oxford University Press. 3, 222–284.

Mueller TD. 2002 Biochim biophys acts.: p. 237-50. Rizzo, RR. 2016. Vitamin C in Burn Resuscitation. Crit Care Clin. 32(4) : 539-46.

Sayed, MM. 2005. Inflammatory cardiovascular-metabolic responses in a rat model of burn injury with superimposed infection. Shock.; 24(Suppl 1):40–44.

