



SEVERITY OF OESOPHAGEAL VARICES PREDICTION BY SHEARWAVE ELASTOGRAPHY IN PATIENTS WITH CHRONIC LIVER DISEASE

Usha Nandhini Ganesan¹, Sumeena Shanmugam², Devimeenal J³, Janani Rajasekaran⁴

^{1,2}Assistant Professor, Department of Radiodiagnosis

³Professor, Department of Radiodiagnosis

⁴Junior Resident, Department of Radiodiagnosis

Government Kilpauk Medical College, Chennai, Tamil Nadu, India

Abstract:

Introduction: Portal hypertension and oesophageal varices in patients with chronic liver disease has serious clinical outcomes.

Objectives: The aim of the study was to determine the accuracy of non-invasive parameter such as spleen stiffness (SS) measured by shear wave elastography to detect high risk oesophageal varices (EV) in patients with chronic liver disease.

Methods: A total of 38 patients with chronic liver disease were enrolled in the study. All underwent upper gastrointestinal endoscopy to evaluate the presence and severity of oesophageal varices. The stiffness values of spleen measured by shear wave elastography on Ultrasound were collected.

The diagnostic performance of shear wave elastography for differentiating high risk varices from low-risk varices was evaluated by a receiver operating characteristic (ROC) curve analysis.

Results: The area under the receiver operating characteristic curve of spleen stiffness was 0.83 respectively. When a cut-off value of 23.2 kPa was used for spleen stiffness to detect varices, the sensitivity was 95 % the specificity 62% and accuracy 84%.

Conclusion: Spleen stiffness measured on shear wave elastography have performed excellently to predict high risk oesophageal varices in patients with chronic liver disease and liver stiffness as a single marker had the best diagnostic value.

Index Terms: chronic liver disease, oesophageal varices, shear wave elastography, esophagogastroduodenoscopy, clinically significant portal hypertension

INTRODUCTION

Portal hypertension is a serious consequence of chronic liver disease.

Portal hypertension is defined by a hepatic venous pressure gradient (HVPG) > 5mm Hg. Above a critical threshold of 10 mmHg, patients with portal hypertension are at an increased risk of developing gastroesophageal varices, acute clinical decompensation (ascites, variceal haemorrhage, and hepatic encephalopathy) and hepatocellular carcinoma¹. Therefore, it is important to recognize portal hypertension early to delay progression and to treat complications of portal hypertension as and when they arise.

Once oesophageal varices are diagnosed, prophylactic measures can be initiated to prevent variceal haemorrhage, such as non-selective beta blockers or endoscopic band ligation². However, both HVPG measurement and EGD are invasive, procedures and is not well tolerated by critically ill patients.

In the last decade, several non-invasive methods and models have been studied to identify high risk varices in chronic liver disease patients. With the emerging technique of shear wave elastography (SWE) for non-invasive diagnosis of spleen stiffness in cirrhosis, the paradigm has shifted to this technique. The technology measures the propagation velocity of acoustically generated tissue shear waves to estimate liver stiffness, expressed in kilopascals, and termed the Young modulus. In our study, we studied the use of spleen stiffness measured by shear wave elastography to identify the high-risk varices in patients with chronic liver disease.

Materials and Methods:

Our study was a cross sectional study conducted in the Department of Radiology, Government Kilpauk Medical College, Chennai between August 2020 and October 2020. Patients with known chronic liver disease participated in the study with informed consent. Patients younger than 18 years and those who had transplantation, hepatocellular carcinoma, hepatic encephalopathy, previously treated oesophageal varices were excluded from the study. All patients enrolled in the study were assessed for the following variables age; sex, body mass index; laboratory parameters viz platelet count, alanine aminotransferase/reference value ratio; liver echoes, liver span, spleen diameter in ultrasound and liver stiffness and spleen stiffness by SWE.

They underwent trans abdominal ultrasound in Aixplorer Supersonic Ultrasound machine. Patients were kept nil by mouth 12 hrs before the ultrasound examination. US examination was first performed by using the conventional B mode. B-mode images of the liver (the left lobe was imaged with the SC15–4 high-frequency linear-array probe; the right lobe was used if left lobe atrophy was present), hepatic veins, liver parenchyma and the spleen were stored. Portal vein diameter and collaterals were noted. Shear wave elastography was performed with an Aixplorer US system equipped with a curved array broadband transducer convex broadband transducer C6 -1Hz. The Aixplorer provided B-mode Ultrasound images and elastographic color maps simultaneously. A sample box was positioned on B-mode image of the liver and elastography measurements were obtained by pressing a button. The patient was in dorsal decubitus position with the left arm elevated above the head for an optimal intercostal acoustic window. The Shear wave elastographic measurements were obtained at the end of normal expiration (breath-hold without deep inspiration. The region of interest was placed at a depth of less than 6 cm from the skin surface and at least 1 cm deep to the capsule to avoid reverberation artifacts. Shear wave elastographic measurements were recorded only when the region of interest (with fixed dimension of 10×10 mm) was filled with color. (Figure 1) Only regions that avoided large blood vessels were used. All examinations comprised 3 sequential measurements³. The median value of the measurements was used for the analysis⁴. (Figure 2)

Patients were nil by mouth (NPO) for at least 6 hours before endoscopy. The endoscopists were blinded to the results of Liver and spleen stiffness. The form and location of oesophageal varices was defined as low risk if straight/small calibre varices, and high risk varices if enlarged, beady, nodular or tumour shaped varices.

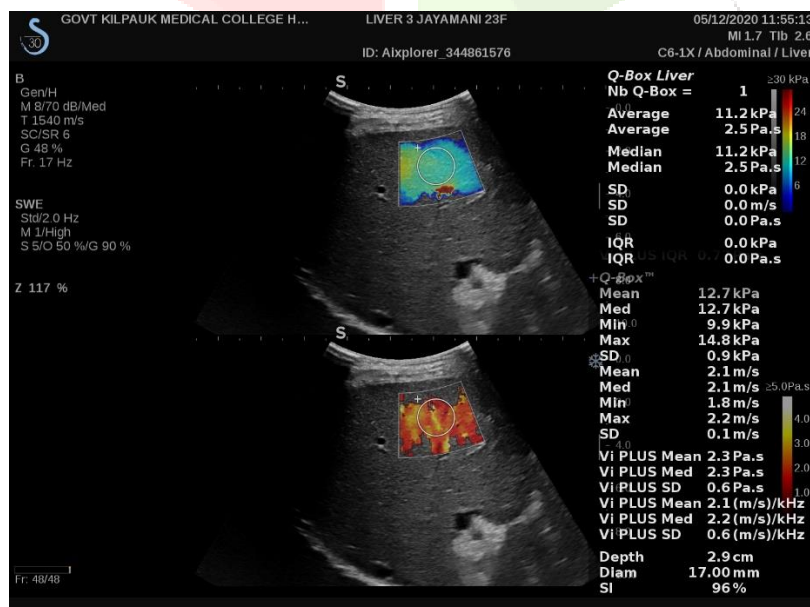


Figure 1: The use of color-coded maps to identify increased stiffness in shear wave elastography. In this image the areas of increased stiffness show green and yellow color.

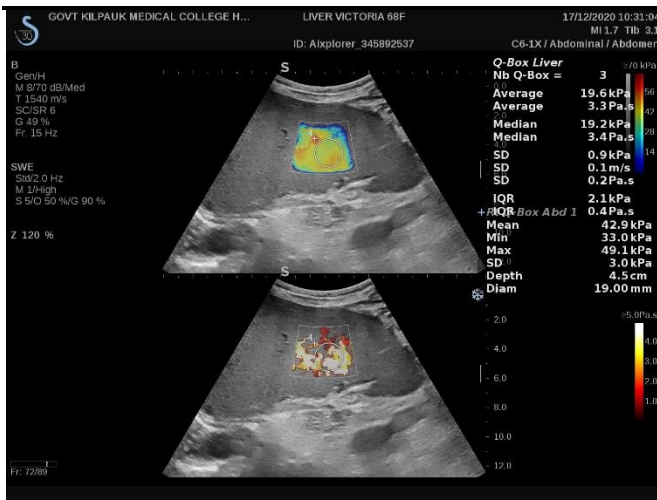


Figure 2: Measurement of stiffness of spleen liver using shear wave elastography showing stiff spleen entirely shaded in red.

STATISTICAL ANALYSIS:

Quantitative values are presented as the mean \pm standard deviation. A receiver operating characteristic (ROC) curve was used to assess diagnostic performance of spleen stiffness. The thresholds maximising the Youden index were calculated, and corresponding sensitivity and specificity are reported. A p value <0.001 was considered statistically significant and all interval estimations given in this paper are 95 % confidence intervals (CI). Statistical analyses were performed by using statistics analysis software MedCalc (Version 20.006).

Results:

A total of 38 patients were enrolled into the study of which 12 were females and 16 were males. Mean age of the study population was 59.2 years. The varices detected by endoscopy were categorized as low risk and high risk for variceal rupture and the number of cases in low and high risk were 16 and 12 respectively. The summary of clinical, laboratory, demographic data and ultrasound parameters are as given in Table 1 and Table 2.

Table1: Summary of clinical, demographic and laboratory data of patients with Chronic liver disease

S.no	Demographic data	Mean	SD	Minimum	maximum
1	Age(years)	59.2	10.1	35	83
2.	ALT units/L	33	22	13	101
3	AST units/L	57	46	13	170
4	Platelet count/ uL	119	41	40	200

Table 2: Summary of ultrasound parameters of patients with Chronic liver disease

S no	Ultrasound parameter	Mean	SD	Minimum	Maximum
1	Liver size	12.7	1.5	9.5	15.9
2	Spleen size	12.2	1.4	10	16.1
3	Portal vein diameter	12.8	1.6	9	16

Table 3: Summary of ROC curves of parameters predicting severity of oesophageal varices group

S.no	Stiffness	AUC	Sensitivity	Specificity	PPV	NPV	Accuracy	P value
1.	spleen	0.83	95	62	76	90	84	<0.0001

The median Spleen stiffness were significantly higher in the high-risk group than the low-risk group. The AUROC for spleen stiffness was 0.83. When a cut-off value of 23.2 kPa was used for spleen stiffness to detect varices, the sensitivity was 95 %, the specificity was 62% and accuracy was 84 %. (Table 3)

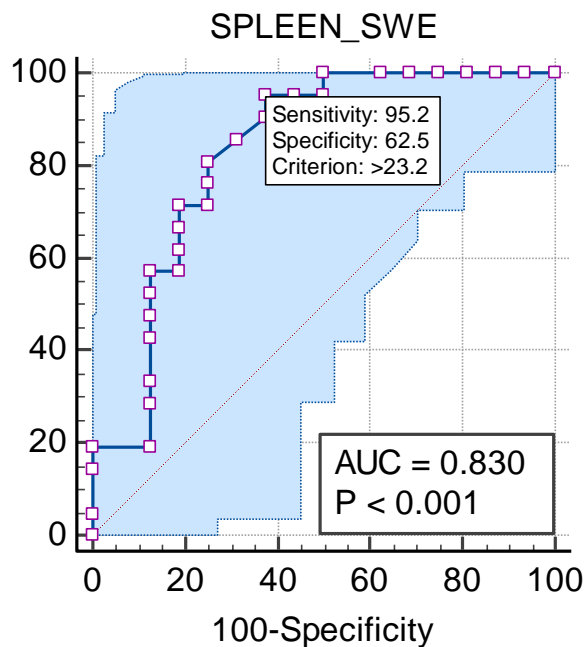


Figure 6: ROC curves of spleen stiffness predicting severity of oesophageal varices group

Discussion:

Chronic liver disease treatment and the prognosis depend on the disease stage. Portal hypertension and oesophageal varices are present in about 50 to 60% of patients with chronic liver disease and those with varices have a worse prognosis than those without varices⁵. Previous recommendations indicate that all patients with cirrhosis should be screened by esophagogastroduodenoscopy (EGD) for varices at diagnosis⁶. Multiple studies have looked for non-invasive ways of identifying the presence of high-risk varices (varices which require treatment, medium sized /large varices, varices with red wale marks) to avoid

unnecessary screening endoscopy⁷. Platelet count, platelet count-to spleen length, have shown limited diagnostic accuracy in predicting the presence of oesophageal varices and are not recommended for diagnosis⁸.

Given the risks and limitations of percutaneous liver biopsy, non-invasive techniques, including imaging and serum markers, are being developed and examined for assessment of chronic liver disease and portal hypertension stages. SWE performs better at excluding high risk varices than diagnosing them⁹. Shear wave elastography is a promising US technique that has the potential to provide non-invasive and quantitative assessments of tissue stiffness. Various studies have shown correlation between liver stiffness measurement and the presence of varices. Previous studies have evaluated the diagnostic performance of SWE for liver fibrosis estimation in patients with chronic hepatitis C and chronic hepatitis B¹⁰. Some non-invasive parameters, however, are accurate enough to rule out high-risk varices in patients with cirrhosis. Recent recommendations

propose that patients with Liver stiffness < 20 kPa in conjunction with a platelet count > 150,000 have a very low risk of having high-risk varices (<5%) and can therefore avoid screening endoscopy; these patients can be followed up with yearly repetition of platelet count and LS by TE¹¹.

Those studies suggest that SWE has the potential to measure hepatic fibrosis noninvasively and accurately. We aimed to assess SWE for oesophageal varices prediction in patients with CLD.

According to the results of our study, in patients with chronic liver disease spleen stiffness was significantly higher among those high risk oesophageal varices group compared with low risk group.

The best cut-off for spleen stiffness in our study was 23.3 kPa with the area under the ROC curve being 0.83. In a meta-analysis conducted in 2018, the sensitivity of. In In our study, Spleen Stiffness was highly specific with greater accuracy.

The limitations of our study include small sample size and lack of patient follow up. To establish relevant cut offs and to validate the concept of using spleen stiffness will require larger groups of patients and several independent studies.

References

1. Garcia-TsaoG, Abraldes JG, BerzigottiA, Bosch J. Portalhypertensive bleeding in cirrhosis: Risk stratification, diagnosis, and management: 2016 practice guidance by the American Association for the study of liver diseases. *Hepatology* 2017;65(01):310–335
2. Garcia-Tsao, G., Sanyal, A.J., Grace, N.D., Carey, W., 2007. Practice Guidelines Committee of the American Association for the Study of Liver Diseases tPPCotACoG. Prevention and management of gastroesophageal varices and variceal hemorrhage in cirrhosis. *Hepatology* 46 (3), 922–938.
3. Fierbinteanu-Braticevici C, Tribus L, Peagu R, Petrisor A, Baicus C, Cretoiu D, Pasternak A, Oprea G, Purcareanu A, Moldoveanu AC. Spleen stiffness as predictor of esophageal varices in cirrhosis of different etiologies. *Scientific Reports*. 2019 Nov 7;9(1):1-7.

4. Kim BK, Han KH, Park JY, Ahn SH, Kim JK, Paik IH, et al. A liver stiffness measurement-based, noninvasive prediction model for high-risk esophageal varices in B-viral liver cirrhosis. *Am J Gastroenterol* 2010;105:1382–90
5. Colecchia A, Montrone L, Scaiola E, Bacchi-Reggiani ML, Colli A, Casazza G, et al. Measurement of spleen stiffness to evaluate portal hypertension and the presence of esophageal varices in patients with HCV-related cirrhosis. *Gastroenterology* 2012;143:646–54,
6. Berzigotti A, Seijo S, Arena U, Abraldes J, Vizzutti F, García-Pagán JC, et al. Elastography, spleen size, and platelet count identify portal hypertension in patients with compensated cirrhosis. *Gastroenterology* 2013;144:102–11
7. Augustin S, Millán L, González A, Martell M, Gelabert A, Segarra A, et al. Detection of early portal hypertension with routine data and liver stiffness in patients with asymptomatic liver disease: a prospective study. *J Hepatol* 2014;60:561–9
8. Buechter, M. et al. Spleen and Liver Stiffness Is Positively Correlated with the Risk of Esophageal Variceal Bleeding. *Digestion* 94, 138–144 (2016).
9. de Franchis R, Baveno V.I. Faculty. Expanding consensus in portal hypertension: report of the Baveno V.I. Consensus Workshop: stratifying risk and individualizing care for portal hypertension. *J Hepatol* 2015;63:743–52,
10. Abraldes J, Bureau C, Stefanescu H, Augustin S, Ney M, Blasco H, et al. Anticipate Investigators. Noninvasive tools and risk of clinically significant portal hypertension and varices in compensated cirrhosis: the “Anticipate” study. *Hepatology* 2016;64:2173–84
11. Maurice JB, Brodtkin E, Arnold F, Navaratnam A, Paine H, Khawar S, et al. Validation of the Baveno VI criteria to identify low risk cirrhotic patients not requiring endoscopic surveillance for varices. *J Hepatol* 2016;65:899–905
12. Manatsathit, W., Samant, H., Kapur, S., Ingviya, T., Esmadi, M., Wijarnpreecha, K., et al., 2018. Accuracy of liver stiffness, spleen stiffness, and LS-spleen diameter to platelet ratio score in detection of esophageal varices: systemic review and meta-analysis. *J. Gastroenterol. Hepatol.* 33 (10), 1696–1706.