



PULMONARY COMPLICATIONS IN DENGUE

Sayonee

Resident

KPC Medical College and Hospital, West Bengal University of Health Sciences

ABSTRACT

❖ BACKGROUND:

Dengue is one of the commonest arboviral diseases worldwide. More than half a million cases of DHF occur each year with at least 12,000 deaths. Patients have a triad of symptoms:

- i) Haemorrhagic manifestations
- ii) Evidence of plasma leakage
- iii) Platelet count < 1 lakh/ μ l

Respiratory complications occur in severe stages of DHF and DSS when dengue virus antigen is found in alveolar lining cells of lungs that causes an increased permeability of alveolar capillary membrane and results in ARDS. Such severe cases might result hemoconcentration and hypoalbuminemia, leading to the detection of pleural effusions and ascites.

Thoracic manifestations such as pleural effusion, pneumonia, pulmonary haemorrhage and haemoptysis, and ARDS can be seen.

❖ METHODS

Patients have been assessed of incidence of pulmonary manifestations among dengue hospitalized cases.

We have evaluated 100 patients, of which 82 were males and 18 were females, seropositive of dengue which was confirmed by NS1 antigen and IgM and IgG antigen. Respiratory manifestations were recorded and all clinical examinations and findings were duly noted. On further investigations like CBC, LFT, ECG (wherever necessary) along with dengue virus antigen profile, chest X-ray (PA and lateral view), USG (whole abdomen), CT chest (wherever necessary) were noted.

❖ FINDINGS

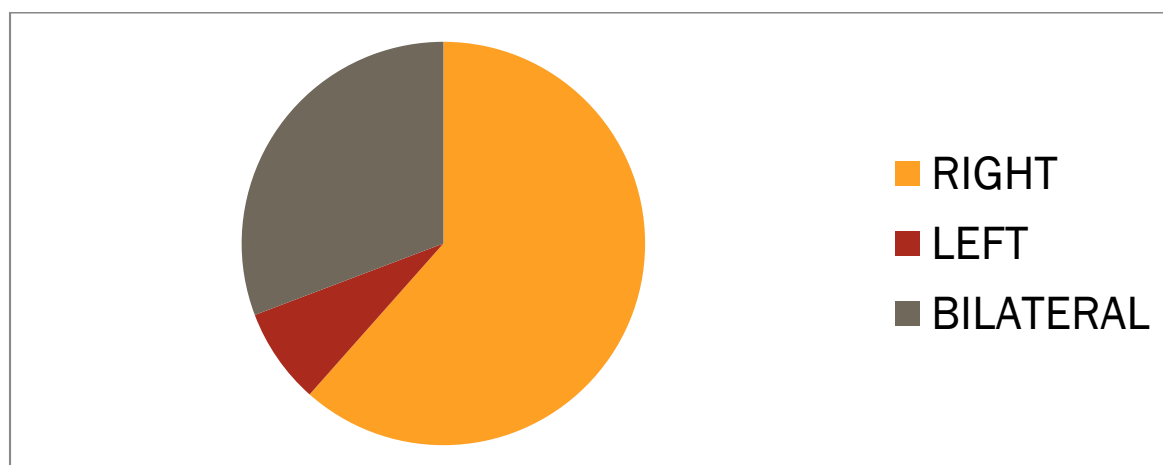
Out of 100 evaluated patients, seropositive of dengue, 65 patients (53 males and 12 females) had pleural effusions which accounts for 65%.

Among the 65 patients who had pleural effusion, 40 patients had **right sided effusions**, 5 had left sided ones and 20 had bilateral pleural effusions.

This accounts for 61.53% patients having **right sided effusions**, 7.69% having left sided ones and 30.76% bilateral pleural effusions

Number of dengue patients having pleural effusion	65
No. of patients having RIGHT sided effusion	40 (61.53%)
No. of patients having LEFT sided effusion	5 (7.69%)
No. of patients having BILATERAL effusion	20 (30.76%)

Thus, **RIGHT sided pleural effusions** were seen to be predominant in our study.



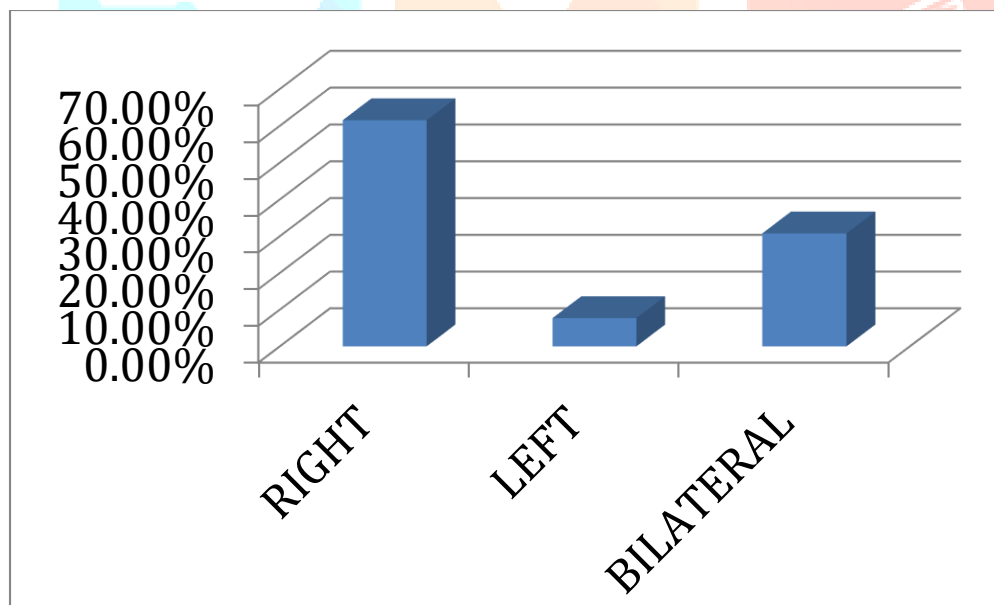
Among the 100 patients having pleural effusions in DF cases, certain investigations were done, whose results were:

- i) Thrombocytopenia was seen among all of them
- ii) LFT was seen to be deranged (with elevated SGOT, SGPT levels, decreased total protein levels and decreased albumin levels) among 96 out of 100 patients, i.e., 96%
- iii) USG (whole abdomen) showing ascitis were 20 among the 100 pleural effusion cases, i.e., 20%
- iv) Chest X-ray (PA & Lateral view) confirmed the pleural effusions and also showed evidence of pneumonia, ARDS in some patients.
- v) CT chest showed 3 patients having right upper lobe consolidation, which accounts for 3%.

❖ CONCLUSION

Among patients of dengue fever, pulmonary complications were common and among the pulmonary complications, pleural effusions were more common.

In those patients of pleural effusions, **right sided effusions** were detected more.



❖ IMPRESSION

The pathogenesis of the pleural effusions is:

1. Systemic increase in permeability of capillaries
2. Anatomically, right lung is bigger and weighs more than the left lung as the left lung has 2 lobes whereas the right lung has 3, thus, providing more mass of organ, leading to a greater amount of blood vessels in the right side than that of the left one. Therefore, pleural effusions tend to occur first, or more, on the right side.
3. Pleural effusion can occur following ascitis, the mechanism of which is the increased intraabdominal pressure than the relatively lower intrathoracic pressure. A pressure gradient is thus created which tends to draw the ascitic fluid towards the intrathoracic compartment. Among the diaphragmatic opening, the

venacaval opening predominantly on the **right side** with a relatively larger diameter acts as a major portal for the entry of ascitic fluid into the thoracic cavity.

4. In pleural effusions which develop as a result of pulmonary oedema related to left sided cardiac failure, it is the anatomy of pulmonary veins and the direction that they enter the left side of the heart, that make retrograde flow more directly into the right side than the left.

