



Management of Conjunctival Squamous Cell Carcinoma A Case Report

Authors: Amhoud Karim ¹, El marzouqi Batal ², Karmoun Souhaila ³, Abdallah El hassan ⁴,
Berraho Amina ⁵.

Department of Ophtalmology B, Ibn Sina Hospital, University Mohamed V, Rabat, Morocco.

ABSTRACT

A 42-year-old male consulted to our eye hospital for a tumorous lesion on the temporal bulbar conjunctiva of the left eye. A topical therapy with antibiotic and corticosteroid eye drops did not change the lesion. The conjunctival tumor was widely resected. The histopathological diagnosis suggested a squamous cell carcinoma. After resection, a treatment with topical Mitomycin C 0.02% eye drops were started 4 times daily for 14 days. Three cycles of treatment were done with a 2-week interval. At the 12-month follow-up, there was no sign of recurrence.

Keywords : Squamous Cell Carcinoma, Mitomycin C, Excision

INTRODUCTION

Squamous cell carcinoma (SCC) of the conjunctiva is an uncommon lesion, The incidence is about 9 to 10 times higher in the African population than the Caucasian [1-3], It occurs frequently on sun exposed areas of the eye, generally at the perilibic conjunctiva [4]. Several clinical forms are classically described. Its management remains an up-to-date topic.

This report illustrates the case of Squamous cell carcinoma of the conjunctiva managed with excision and postoperative treatment with Mitomycin eye drops.

CAS REPPORT

A 42-year-old male consulted for a conjunctival nodule evolving since 3 months, gradually increasing in volume on the temporal bulbar conjunctiva of the left eye. No medical or surgical history was mentioned. Visual acuity has been preserved

The clinical examination showed a gelatinous sessile tumor measuring (6 x 7mm), with orange pink colour, slightly raised, fairly limited in relation to the surrounding normal tissue, oval-shaped, encroaching on the Temporal limbus with a vascular rich surrounding inflammatory. (**Figure 1**).

Wetting eye drops and a topical therapy with Maxitrol eye drops (Novartis Pharma, Morocco), a combination of corticosteroid and antibiotic eye drops (1 mL suspension contains 1 mg dexamethasone, 6000 IU polymyxin B sulphate, 3500 IU neomycin sulphate) 4 times a day were used for 14 days and an inflammatory test was performed.

Topical therapy eye drops did not change the lesion, so it has been decided to practice an excisional biopsy.

Surgical time

After application of topical anesthesia (oxybuprocaine hydrochloride 0.4%) and subconjunctival anesthesia (lidocaine hydrochloride 2%)

The tumor was excised with Vannas scissors using a wide excisional biopsy with a tumor safety distance of at least 2.0 mm. Cautery was carefully applied to bleeding vessels. Primary closure involved closure of the conjunctival defect following mobilization of the surrounding conjunctiva to cover the bare sclera. **(Figure 2)**

Histopathological examination

Tumor proliferation that replying to the description of a well differentiated squamous cell carcinoma infiltrating the basal lamina and the superficial chorion

Surgical margins were diagnosed as tumor free

Surgical outcomes

After resection, a treatment with topical Mitomycin C 0.02% eye drops were started 4 times daily for 14 days. Three cycles of treatment were done with a 2-week interval. Serology of human immunodeficiency virus was negative, the surgical follow-up was satisfying with tissue regeneration, transparent pink conjunctiva and decreased peri lesional neovascularization.

(Figure 4,5)

At the 12-month follow-up a slit-lamp examination revealed no sign of recurrence

DISCUSSION

Conjunctival SCC is more common in males and in older ages [1,5]. In our case the patient was a man with a younger age So Atypical cases are possible, misdiagnosis can lead to the progression of the disease.

When they occur at an earlier age, they are generally not located in the bulbous part of the conjunctiva and are clinically more aggressive [6]. It is more frequent in fair skinned populations than in more pigmented ones [7].

The risk factors for Ocular surface squamous neoplasia include cigarette smoking, Human Immunodeficiency Virus, human papilloma virus, systemic or local immunosuppression and ultraviolet-B radiation which mainly concerns the perilimbal part of the conjunctiva in the interpalpebral region [5].

Functional signs are infrequently in the foreground and none is pathognomonic, which often delays the diagnosis and increases morbidity [8]. The patient reported only eye redness.

The clinical evaluation, by slit-lamp biomicroscopy, should determine the size and location of the lesion, conjunctival mobility, vascularity, and association with the cornea, carunculum, and nasolacrimal drainage system [9].

The most frequent is the gelatinous form, characterized by dilated superficial vessels. The nodular form has increased lymphatic metastatic potential.

The diffuse form is often difficult to diagnose, mimicking chronic conjunctivitis. The SCC can also be manifested by a leukoplakic lesion surrounded by nourishing vessels [10]. Our case presented a gelatinous the gelatinous one.

The gold standard for the diagnosis of SCC is histopathologic evaluation following an excisional biopsy.

Invasive conjunctival Carcinoma is commonly treated by excision with or without adjunctive cryotherapy [11].

SCC is locally invasive (can invade both the orbit and the eye globe), and can metastasis to regional lymph nodes [12]. In our case, there was no corneal or deep tumor extension.

In case of infiltrative form, contact or external radiotherapy can also be proposed [4].

This Tumor has been found to be the most common conjunctival malignancy, and it is life threatening if not treated adequately [13]. After resection topical mitomycin C seem to be a safe and effective therapy for conjunctival and corneal SCC, even when there is extensive recurrent tumor [14]. Different publications have addressed that after resection topical mitomycin C represents a cost-effective and safe approach to minimize tumor recurrence [3].

CONCLUSION

Conjunctival SCC occurs frequently on sun exposed areas of the eye usually in sun damaged conjunctiva at the limbus.

The diagnosis is made by histological study after excision of the tumor.

It is a curable tumor, the prognosis is good if it was completely removed associated with well coded adjuvant treatment preventing recurrences.

REFERENCES

- [1]. Gichuhi S, Mandeep S, Weiss H, Burton M: Epidemiology of ocular surface squamous neoplasia in Africa. *Trop Med Int Health*, 2013; 18: 1424–43
- [2]. Cicinelli MV, Marchese A, Bandello F, Modorati G: Clinical management of ocular surface squamous neoplasia: A review of the current evidence. *Ophthalmol Ther*, 2018; 7: 247–62
- [3]. Röck T and al. Clinical Management of Squamous Cell Carcinoma of the Conjunctiva *Am J Case Rep*, 2020; 21: e919751
- [4]. H. Janin-Manificat and al. Conjunctival epidermoid carcinoma revealed by a chronic limbic corneal ulceration *Journal français d'ophtalmologie* (2011) 34, 108—112
- [5]. Rajeh A, Barakat F, Khurma S et al: Characteristics, management, and outcome of squamous carcinoma of the conjunctiva in a single tertiary cancer center in Jordan. *Int J Ophthalmol*, 2018; 11: 1132–38
- [6]. Hug HD. McGowan, M.D., FRC SC. Squamous cell carcinoma: new TNM Classification of the 'American Joint Committee on Cancer (AJCC). *Ophthalmologie, Conférences scientifiques february 2009 Volum 7, number 1*
- [7]. Shields CL, et al. Clinical survey of 1643 melanocytic and nonmelanocytic conjunctival tumors. *Ophthalmology* 2004;111:1747—54
- [8]. D.Buc, F. Pilon, D. Donnarieix, J.L. Kemeny, F. Bacin, D. Rigal. Traitement des tumeurs épithéliales de la conjonctive : intérêt de la curiethérapie au Ruthénium-106. *J. Fr. Ophtalmol.*, 2003 ; 26, 9 :929-933
- [9]. A. Karim, LA Hamoud. Mitomycine C en collyre dans le traitement des carcinomes de la conjonctive Thèse 87/2011 faculté de médecine et de pharmacie de rabat. Page 33
- [10]. S. Dib, R. Benhadouch, T. Abdou Management of squamous cell carcinoma of the conjunctiva in a young patient: Case report *Journal français d'ophtalmologie* (2019) 42, 387—390
- [11]. Kenawy N, Garrick A, Heimann H et al: Conjunctival squamous cell neoplasia: The Liverpool Ocular Oncology Centre experience. *Graefes Arch Clin Exp Ophthalmol*, 2015; 253: 143–50
- [12]. Mittal R, Rath S, Vemuganti GK. Ocular surface squamous neoplasia-Review of etio-pathogenesis and an update on clinico-pathological diagnosis. *Saudi J Ophthalmol* 2013;27(3):177-186
- [13]. Bunya V, Chang V. Ocular surface squamous neoplasia. *American Academy of Ophthalmology Review: Assigned status Up to Date* by Vatinee Bunya, MD on December 17, 2015
- [14]. Shields CL, Naseripour M, Shields JA: Topical mitomycin C for extensive, recurrent conjunctival-corneal squamous cell carcinoma. *Am J Ophthalmol*, 2002; 133: 601–6

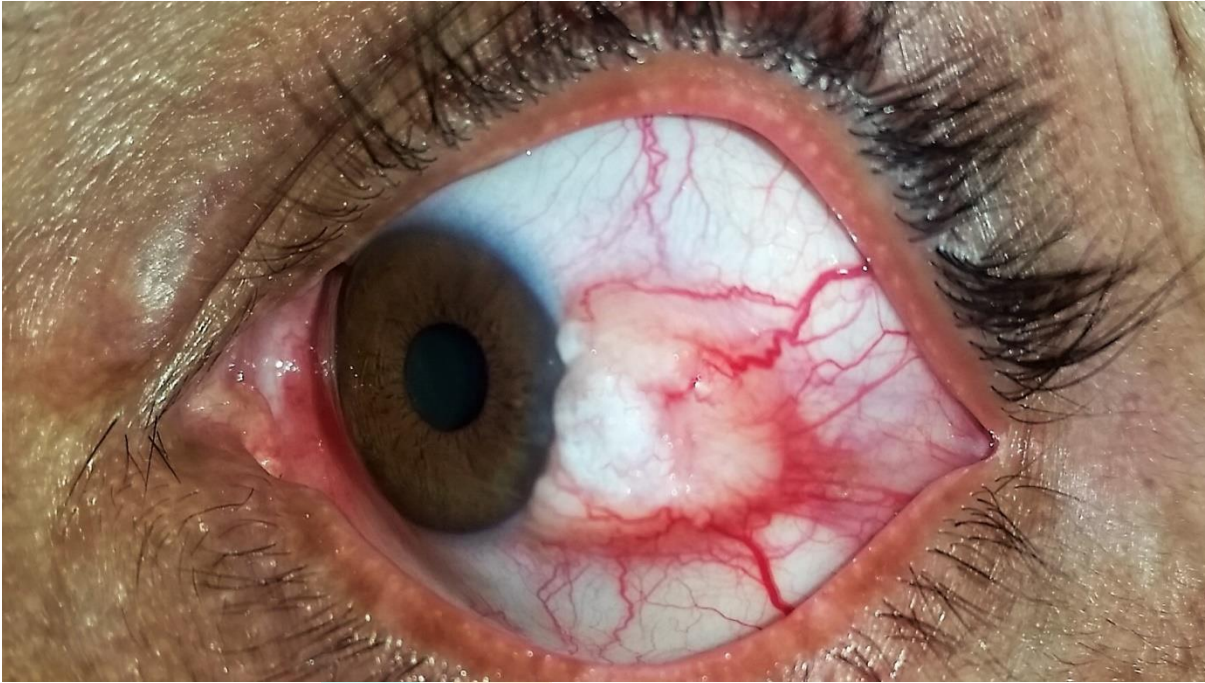ICONOGRAPHY:

Figure 1. Initial slit-lamp image showing a gelatinous, tumorous lesion and inflammation on the temporal bulbar conjunctiva of the left eye.

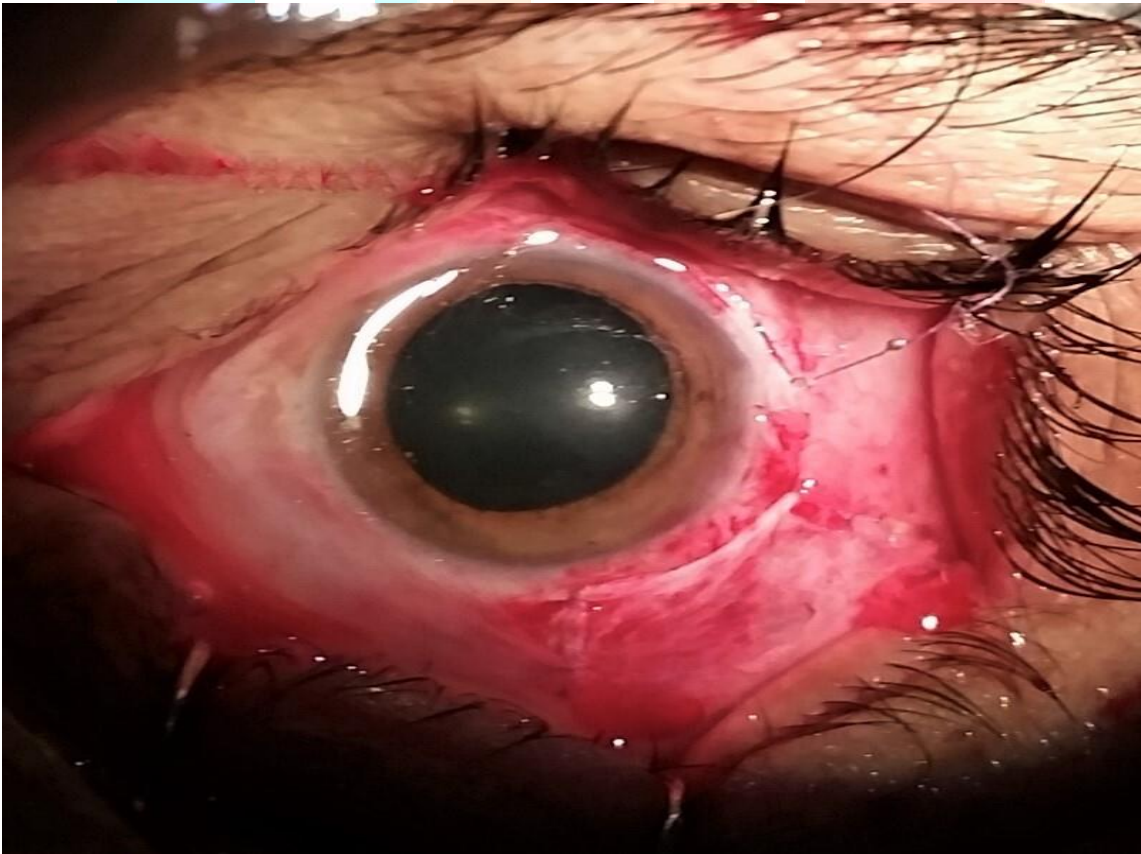

Figure 2 Immediate post-operative image after tumor resection and closure of the conjunctival defect

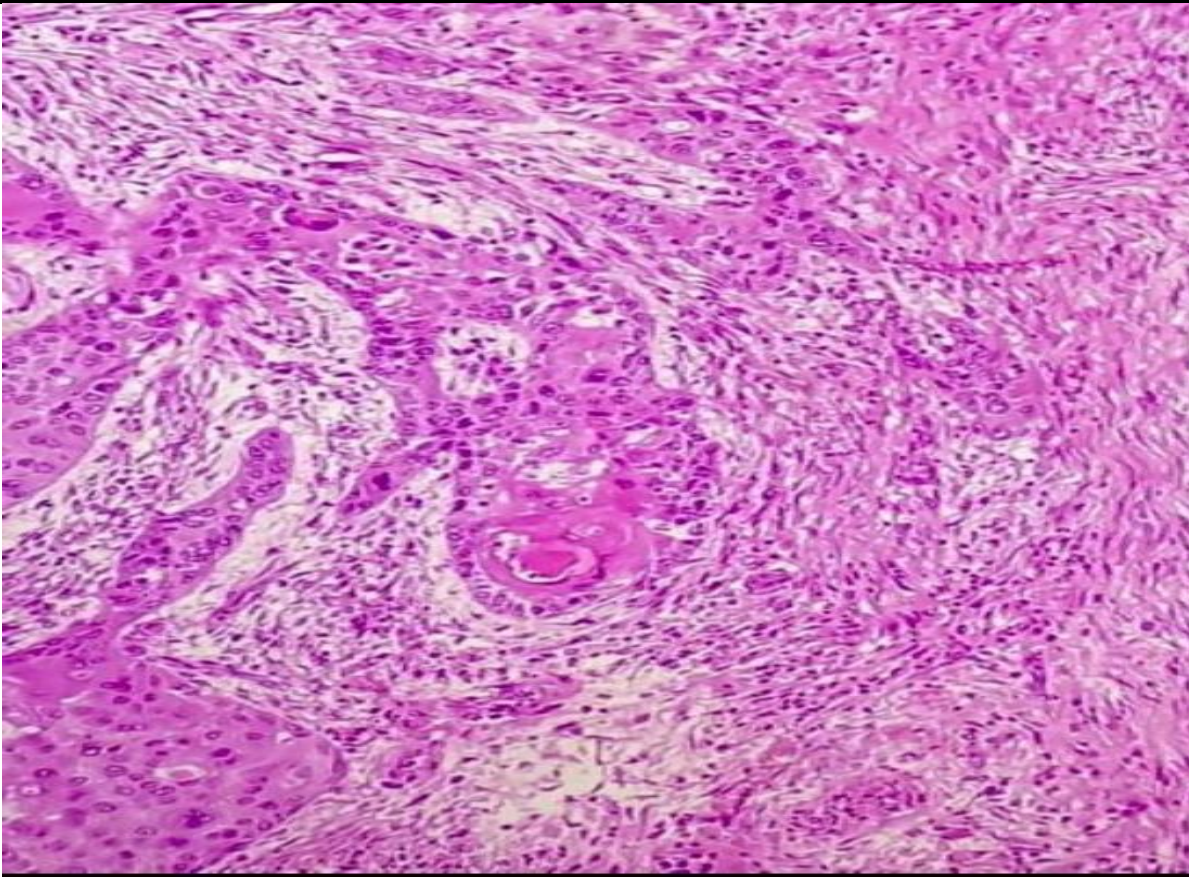


Figure 3 Histopathological slides of the squamous cell carcinoma of the conjunctiva infiltrating the basal lamina and the superficial chorion stained with HPS stain [100× magnification]

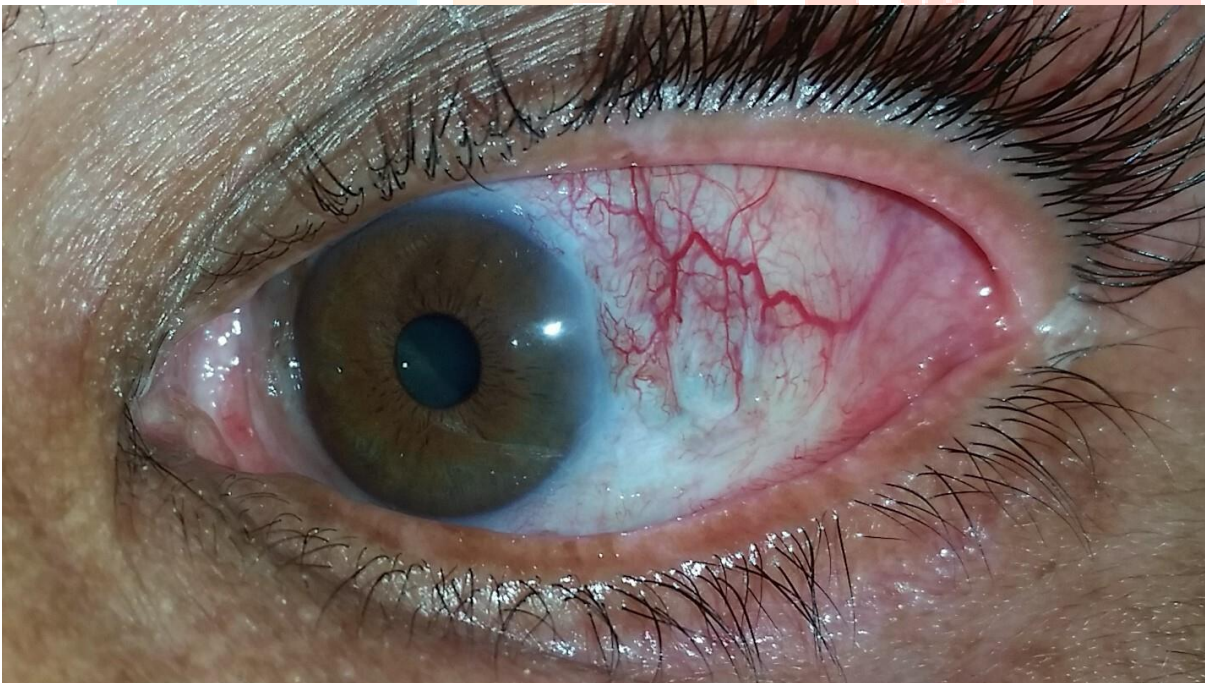

Figure 4. At the 1st-month follow-up a slit-lamp examination revealed a satisfying with tissue regeneration and decreased peri-lesional neovascularization.

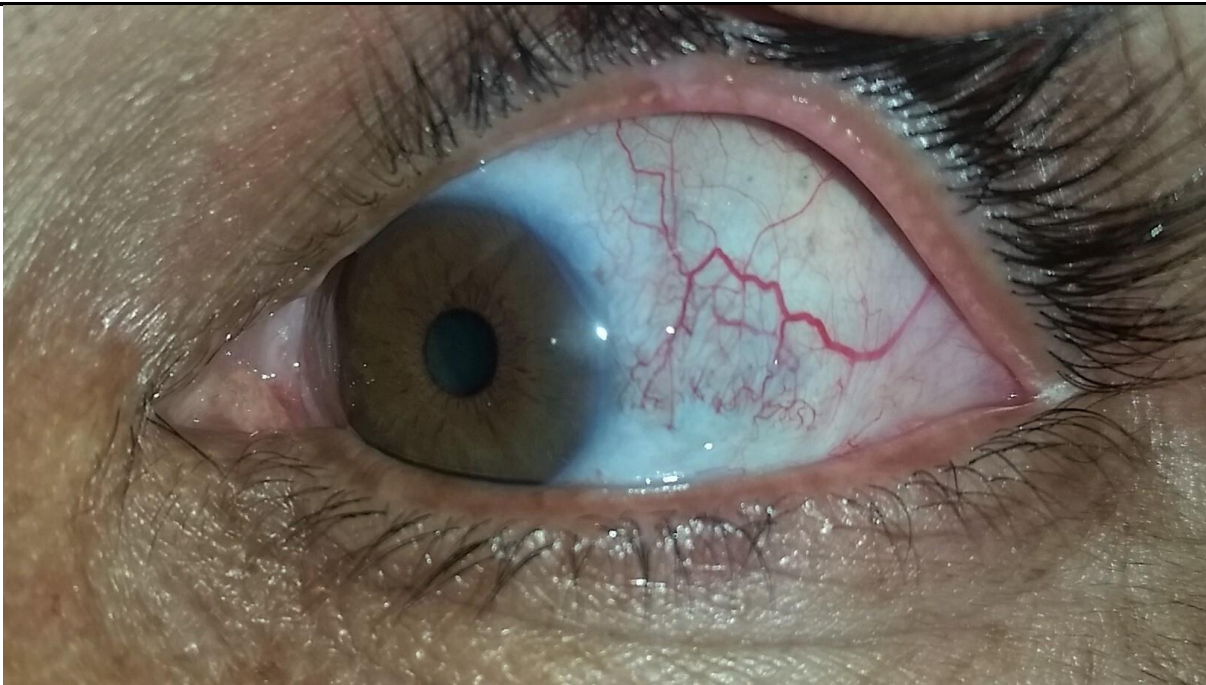

Figure 5. At the 6th-month follow-up a slit-lamp examination revealed no sign of recurrence or any postoperative Complication

