



# INTERNATIONAL JOURNAL OF CREATIVE RESEARCH THOUGHTS (IJCRT)

An International Open Access, Peer-reviewed, Refereed Journal

## LOBULAR CAPILLARY HEMANGIOMA OF THE NASAL CAVITY: A STUDY OF 2 CASES

<sup>1</sup>Dr. Ashiya Goel, <sup>2</sup>Dr. Aman, <sup>3</sup>Dr. Swati, <sup>4</sup>Dr. Vinny Raheja, <sup>5</sup>Dr. Manisha

<sup>1</sup>Senior Resident, Department of Otorhinolaryngology, <sup>2</sup>Senior Resident, Department of Otorhinolaryngology, <sup>3</sup>Senior Resident, Department of Otorhinolaryngology, <sup>4</sup>Junior Resident, Department of Otorhinolaryngology, <sup>5</sup>Senior Resident, Department of Anaesthesiology

<sup>1</sup>Pt. B.D. Sharma PGIMS, Rohtak, Haryana, India,

<sup>2</sup>Maharaja Agrasen Medical College, Agroha, Haryana, India.,

<sup>3</sup>Pt. B.D. Sharma PGIMS, Rohtak, Haryana, India,

<sup>4</sup>Pt. B.D. Sharma PGIMS, Rohtak, Haryana, India,

<sup>5</sup>Pt. B.D. Sharma PGIMS, Rohtak, Haryana, India

### INTRODUCTION

Lobular capillary hemangioma is a benign vascular tumor. It is also known as pyogenic granuloma, eruptive hemangioma, granuloma gravidarum or tumor of pregnancy.<sup>1,2</sup> A vascular lesion arising from both mucosa and skin, and it appears as an overgrowth of tissue usually found in the oral cavity.<sup>3</sup> Rare sites for the tumor include the nasal cavity among which nasal septum is the most common.<sup>4</sup> Two cases of nasal septal pyogenic granuloma which were treated by surgical excision are being presented.

### CASE REPORTS

A 25 year old female patient presented in Otolaryngology Dept. with complaints of recurrent episodes of epistaxis from right nasal cavity since the past two months which were spontaneous in onset with mild to moderate bleed occurring two to three times per week. There was no history of trauma, nasal packing, amenorrhoea, recurrent nasal picking, irritation or use of any oral contraceptives. On examination, a small pinkish pedunculated mass, about 1cm in diameter was visualized in the right nasal cavity which was insensitive to touch and not bleeding on manipulation. It originated from the anterior portion of the septal mucosa about 4 mm posterior to the right vestibule.(Figure 1) On Computed Tomographic scan, the mass was visualized attaching to the septum with the rest of the nose and the paranasal sinuses appearing normal. The mass was excised under local anaesthesia along with the adjacent mucoperichondrium under endoscopic vision. The margins of the perichondrium and the base were cauterized to achieve haemostasis and prevent recurrence. Nasal packing was not required. The excised mass was sent for histopathological examination. Microscopic examination revealed varying sized capillaries in lobular arrangements lined with flattened endothelial cells, surrounding these lobules a loose spindle cell proliferation of pericytic cells was also present.

Our other case was a 42 year old male patient who came with the complaints of right nasal obstruction and history of intermittent episodes spontaneous nasal bleed from right side since last four months. Nasal obstruction was gradually increasing in severity with no diurnal variation. Patient had no complaints of rhinorrhea, facial pain, headache and

post nasal drip. There was no history of trauma or any other medical condition like hypertension, diabetes mellitus etc. On diagnostic nasal endoscopy, a 2cm x 1 cm reddish pink mass was visualized attached to posterior part of the cartilaginous septum.(Figure 2) The mass was non tender and not bleeding on touch. On radiological examination, mass was limited to right nasal cavity and no bony erosion was seen. The mass was excised and sent for histopathology which revealed features suggestive of pyogenic granuloma.

Both the patients were observed for a few months and no recurrence was seen in either case.

## DISCUSSION

This vascular lesion was first described as “human botryomycosis” by Poncet and Dor in 1897. The term pyogenic granuloma commonly used for this condition is a misnomer as there are no pyogenic or infectious entities, nor are there features of granulomatous disease. Hence, the term “lobular capillary hemangioma” as described by Mills et al. is more appropriate.<sup>5</sup> Some authors, classify these as hamartomas or congenital vascular anomalies and not as benign vascular tumors.

The exact etiology is not yet known. This hemangioma is considered a reactive vascular response to a variety of stimuli such as trauma and increased levels of female sex hormones due to oral pills consumption and pregnancy. Viral oncogenes, arteriovenous malformations, and angiogenic growth factors are also suspected to play a role. Hemangiomas frequently affect cervical-facial districts localizing mainly to the gingiva, oral mucosa, tongue and lips.<sup>3</sup> Sinonasal hemangiomas are rare. Among the nasal cavity they are seen mostly arising from the septum and less commonly by vestibule, inferior and middle turbinate.<sup>6</sup> In our series both the cases arose from the nasal septum. According to the literature, lobular capillary hemangioma of the nasal cavity is more common in pregnant females and frequently affects middle age people.<sup>7</sup> However, in our series we had both a male and a female patient and our patient was not pregnant.

Histologically, the lesion appears as a lobular proliferation of capillaries with each lobule containing a central feeder vessel surrounded by aggregates of capillaries.<sup>8</sup> The lobules are separated by a fibro-myxoid stroma. On CT, hemangiomas appear as masses characterized by intensity of the soft tissues, and they can capture the contrast in brightly lobular region. The surface portion, on the other hand, does not seem to take contrast. Since a biopsy is difficult for potential bleeding risk, a lot of data can be collected from a radiological study. Pyogenic granuloma has to be differentiated from infantile hemangioma, cherry angioma, Kaposi’s sarcoma, and angiosarcoma among others.

Various treatment modalities have been explored in the past including medical management with corticosteroids and propranolol.<sup>9</sup> Surgical excision remains the primary form of treatment. For massive lesions, preoperative embolization can also be utilized. Recently laser therapy, cryotherapy and sclerosing agents are also being evaluated.

## CONCLUSION

Lobular Capillary Hemangiomas of the nasal cavity, being highly uncommon can easily be missed and confused with malignant tumors of the nasal cavity. Excision Biopsy of these masses with cauterization of the base reduce the chance of recurrence. Pyogenic Granuloma should be considered as differential diagnosis for nasal masses presenting with epistaxis.

## REFERENCES

1. Jones JE, Nguyen A, Tabae A. Pyogenic granuloma (pregnancy tumor) of the nasal cavity. A case report. J Reprod Med. 2000;45:749-53.
2. Hartzell MB. Granuloma pyogenicum. J Cutan Dis Syph. 1904; 22: 520-5.
3. Genc S, Kurkcuoglu SS, Karabulut H, Acar B, Tuncel U, Degerli S. Giant lobular capillary hemangioma of the nasal septum. Turk J med Sci. 2009;39:325-8.
4. Kim ST, Kim SH, Gu GY, Cha HE. Three cases of hemangioma in nasal septum. J Rhinol. 2000;7:80-3.
5. Mills SE, Cooper PH, Fechner RE. Lobular Capillary Hemangioma: The Underlying Lesion of Pyogenic Granuloma. A Study of 73 Cases from the Oral and Nasal Mucous Membranes. Am J Surg Path. 1980;4:470-9.
6. Puxeddu R, Berlucchi M, Ledda GP, Parodo G, Farina D, Nicolai P. Lobular capillary hemangioma of the nasal cavity: A retrospective study on 40 patients. Am J Rhinol. 2006;20:480-4.
7. Ozcan C, Apa DD, Gorur K. Pediatric lobular capillary hemangioma of the nasal cavity. Eur Arch Otorhinolarygol. 2004;261:449-51.
8. Ting PT, Barankin B. Dermacase Pyogenic granuloma. Can Fam Physician. 2006;52:35-6.
9. Simic R, Vlahovic A, Subarevic V. Treatment of nasal hemangioma. Int J Pediatr Otorhinolaryngol. 2009;73:1402-6.

## Legends

- **Figure 1-** Polypoidal mass attached to the nasal septum abutting the lateral wall a little posterior to the vestibule.
- **Figure 2-** 2cm\*1cm mass attached to the nasal septum.

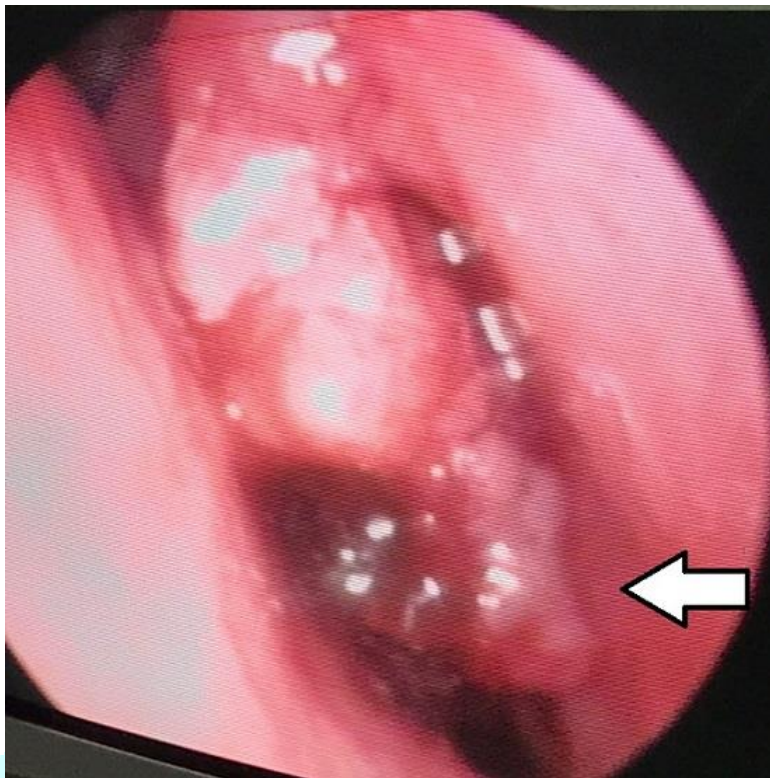


Fig. 1

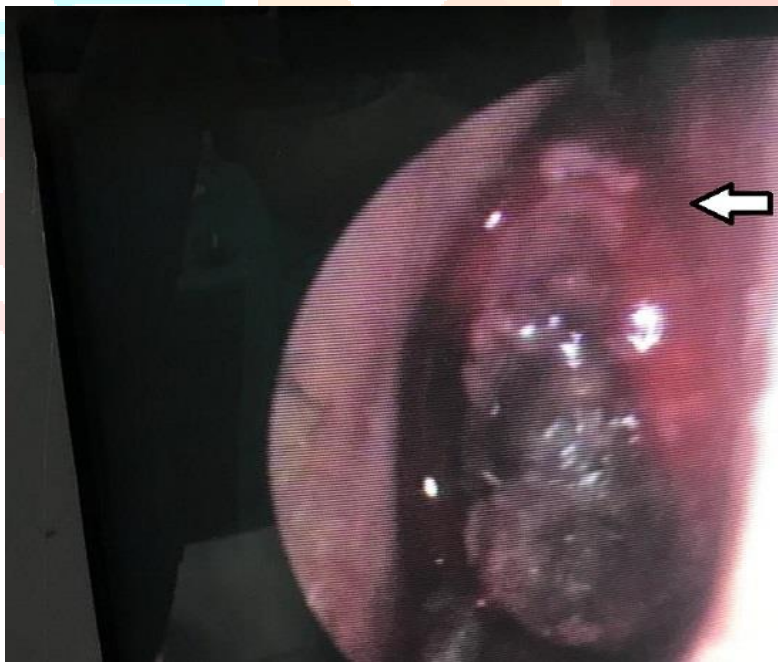


Fig. 2