



# Rejuvenating Esthetics Using Flangeless Denture: A Case Report

Dr Suresh Kamble<sup>1</sup>, Dr Ajit Jankar<sup>2</sup>, Dr Dishita Chokhani<sup>3\*</sup>, Dr Deepali Patane<sup>4</sup>, Dr Siddharth Narote<sup>5</sup>

<sup>1</sup>Principal & PG guide, Department of prosthodontics, MIDSR Dental college, Latur, Maharashtra.

<sup>2</sup>Head of Department, Department of prosthodontics, MIDSR Dental college, Latur, Maharashtra.

<sup>3,4,5</sup>Post Graduate Student, Department of prosthodontics, MIDSR Dental college, Latur, Maharashtra.

## ABSTRACT:

Prosthodontic rehabilitation of edentulous patients can be the most satisfying, if treatment can restore patient's function with maximum esthetics. Prosthesis may affect the appearance of a person by either enhancing or detracting from natural appearance. In routine dental practice, patients with varying ridge morphology are encountered. Conventional complete denture fabrication in patients with labially inclined premaxilla and maxillary labial undercuts is complicated due to the need for surgical correction. Failure to undergo surgical intervention results in complete dentures with compromised esthetics which could have long-term undesirable psychological bearing on edentulous patients. This article describes nonsurgical treatment modalities for proclined premaxilla in completely edentulous patients to achieve comprehensive rehabilitation with greatest regard to esthetics.

**Keywords:** Nonsurgical, proclined premaxilla, prosthodontic rehabilitation

## INTRODUCTION:

In modern era, the face determines one's social acceptance. Facial appearance is a significant part of the self-image. The loss of teeth affects the facial appearance and often creates tremendous psychological trauma to a patient. The prosthesis can either restore or distort a patient's personal image, depending upon the naturalness and attractiveness of its appearance. Rehabilitating a complete denture patient is always a challenging situation and any unusual morphology accentuates the task<sup>1</sup>. Some abnormal conditions that exist in the edentulous patient can be corrected surgically prior to construction of dentures, enabling the patient to function more successfully following prosthetic restoration<sup>2,3</sup>. However, use of surgical aid is not always possible. The major obstacle for pre-prosthetic surgery is getting patient's consent<sup>4</sup>. The increasing demands of patients have led to the outcome of the special, i.e. the unconventional approach for fabricating complete dentures.

New techniques based on same old fundamentals of prosthodontics is known as the unconventional complete dentures, a manifestation of new vision in prosthesis fabrication<sup>5</sup>. One such clinical condition, which may pose a problem in denture insertion and may even affect the denture aesthetics, is a bulbous labial cortical plates accompanying severe labial undercut which is commonly seen<sup>6</sup>. Aesthetically, on extraction of the buccally displaced maxillary anterior teeth the residual ridge is in a position to support the upper lip. If a denture base extension is placed in the pre-maxilla, two-thirds of the upper lip will be severely distorted from the base of the nose to the edge of the upper lip, specifically the wet-dry line<sup>7</sup>. Thus, in this situation modified flange or flangeless denture is fabricated.

A key indication for a modified extension of prosthesis is bulbous labial bone with severe undercut where labial flange of prosthesis is not needed required because of sufficient bone and lip support<sup>7</sup>. In these instances, adding a buccal flange can distort the facial support and muscles of facial expression limits the function and compromise the esthetics. The flangeless maxillary complete denture can meet aesthetic requirements and provide ideal support for the upper lip. By maintaining the undercuts in the pre-maxilla, additional retention is potentially available.

#### **CASE REPORT:**

A 65-year old male patient visited the Department of Prosthodontics with a chief complaint of missing teeth and wanting a replacement for the same. Extraoral examination of the patient revealed a well supported upper lip.

Intraoral examination of the patient revealed a severe anterior labial undercut in maxillary ridge (Figure 1). A diagnostic impression was made. Patient was explained about the problems with the conventional denture and was advised to undergo pre-prosthetic surgery which he refused. The patient was then given the option of fabrication of unconventional modified flange denture or a flangeless denture. Patient agreed to the fabrication of unconventional denture. Primary impressions of maxillary and mandibular edentulous ridge were made with impression compound and primary casts were poured in Plaster of Paris (Dental Plaster Class II) (Figure 2,3) and maxillary cast was marked in the region of anterior labial undercut.

Special trays were made and final impressions were made with zinc oxide eugenol impression paste (DPI Impression paste) after performing border molding with low fusing impression compound (DPI Pinnacle tracing sticks) (Figure 4,5). The master casts were poured in type III dental stone. The master cast obtained was surveyed to identify the undercut areas, and the path of insertion and removal of the maxillary denture base was decided. The design of record base with the required modifications of the labial flange were drawn on the master casts. To preserve the master cast, a working cast was made and temporary record base was fabricated according to the decided design using self cure acrylic resin (DPI RR coldcure). The labial flange was completely removed and the anterior edentulous ridge was covered by denture base only over the ridge crest area.

The jaw relation was recorded and teeth selection was done (Figure 6,7). A semi-adjustable articulator was used for the further steps. Anterior teeth setting was first done and anterior try-in was accomplished. Esthetics and phonetics of the patient were analyzed at this step. After the patient was satisfied with the esthetic outcome of the anterior teeth setting, the posterior try-in was done.

The shape of the labial prongs were waxed on the master cast. After completing the wax-up and sealing the record base, a novel flasking technique was used. In anterior land area of the master cast, V-shaped sharp grooves were made. Then polyvinyl siloxane rubber base impression material in putty consistency was mixed following manufacturer's instruction and was adapted over the anterior section of the master cast from the sulcus to the incisal edge of the anterior teeth (i.e canine to canine). This was made in order to preserve the waxed design of the labial flange. The putty was indexed with three grooves on its outer side to orient it properly with the plaster during counter-flasking (Figure 8). Rest of the laboratory procedure was carried out in a conventional way. After processing, finishing and polishing, the denture insertion was performed. The patient was satisfied with the esthetics and function provided by this new set of dentures (Figure 9,11). He had clear speech and her problem of fuller appearance of the upper lip was rectified because of modified labial flange or a flangeless maxillary denture, where lip was in direct contact with ridge instead of the intermediate acrylic flange.

## DISCUSSION:

A precise diagnosis is a key requisite of an ideal treatment plan. An appropriate treatment plan paves the way for a fabulous prosthesis. A standout amongst the most conclusive criteria for progress is living up to patient's desires by offering significance to their requests. Residual ridge anatomy varies from patient to patient. Patient with excessive bulky ridges often has a compromised facial esthetics. The thickness of the labial flange further compromises the labial fullness and result in an unesthetic maxillary denture. Preservation of facial aesthetics is as crucial as prosthodontic rehabilitation of missing teeth<sup>8</sup>.

Facial and dental esthetics significantly influences the prosthetic replacement. Functional integrity along with esthetics is also demanded with any prosthesis. One of the conservative means of utilizing undercuts without sacrificing them to surgical intervention is the use of resilient liners. Besides, even distribution of the functional load and prevention of local stress concentrations, the liners being flexible can be easily removed and inserted in severe undercut areas without traumatizing the tissues<sup>9,10,11,12,13,14</sup>. With advances in soft liners, surgical removal of undercuts will not be preferred in the near future as these liners can serve for a long period<sup>15,16</sup>.

But abnormal morphology of oral structures hinders the fulfillment of all these requirements<sup>17</sup>. In this situation, an eccentric thinking slightly different from routine conventional way may help in changing the whole scenario. Modifying the labial flange of such patients also serves the purpose. Surveying of the cast helps in deciding the correct path of insertion and removal of the prosthesis, thus enhancing its life and preventing the tissue from undue trauma during placement and removal of the prosthesis<sup>1</sup>.

Re-contouring the anterior teeth in the form of laminates also helps in diminishing the bulging appearance of upper lip. Modified flasking technique with polyvinyl siloxane putty preserves the design of labial flange and facilitates the easy removal of denture during deflasking, finishing and polishing. The goal of pre-prosthetic surgery is to create a situation for the prosthesis that would restore function, provide stability and retention, preserve associated structures and satisfy esthetics but many a times patients do not give their consent for the surgery<sup>18</sup>. In this technique, in the area devoid of denture base, the perioral tissues came in direct contact with the mucosa which reduced the lip fullness and improved the esthetics serving the needs of the patient.

### CONCLUSION:

A prosthodontist should endeavor to make the complete denture as unique and customized as possible for each individual. Fabrication of complete denture possesses a great challenge when the perfect necessities of both hard and delicate tissues are not satisfied. The presented technique provides a conservative treatment approach in the presence of severe labial undercuts in the premaxilla (without the need of radical surgical procedures) in the provision of complete dentures for edentulous patients with excessively proclined premaxilla and accompanying labial undercut.

### Conflict of Interest:

There is no conflict of interest.

### REFERENCES:

1. Chaturvedi S, Shah M, Ghodpage SL, Kulkarni M, Gill S. Unconventional prong dentures - a case report. Int. J. Dent. Clinics. 2013;5(1): 49-50.
2. Terry BC, Zarb GH: report on 4<sup>th</sup> international congress on preprosthetic surgery. Int journal of oral maxillofac surg 1991; 20:314-316.
3. Srivastava V, Singh L, Devendra A. Gum fit denture an alternative to alveoloplasty. Journal of Dental Sciences & Oral Rehabilitation.2011:51-2.
4. Hillerup S. Preprosthetic surgery in the elderly. J Prosthet Dent. 1994 ;72(5):551-8.
5. Shah RJ, Parmar P, Soni A, Vyas S, Zala M. Unconventional complete dentures: Innovative approach in prosthodontics. International J. of Healthcare and Biomedical Research. 2014;2(2):123-31.
6. Zarb GA, Bolender CL, Carlsson GE. Boucher's prosthodontic treatment for edentulous patients. 11th ed. St. Louis: Mosby; 1997. p. 141-61, 231-61.

7. Neves FD, Mendonca G, Fernandes Neto AJ. Analysis of influence of lip line and lip support in esthetics and selection of maxillary implantsupported prosthesis design. *J Prosthet Dent*. 2004;91:286-8.
8. Glossary of prosthodontic terms. *Journal of Prosthetic Dentistry* 94:1:10-92.
9. Baysan A, Parker S, Wright PS. Adhesion and tear energy of a long-term soft lining material activated by microwave energy. *J Prosthet Dent* 1998;79(2):182-7.
10. Wright PS. The success and failure of denture soft-lining materials in clinical use. *J Dent* 1984;12(4):319-27.
11. Bell DH Jr. Clinical evaluation of a resilient denture liner. *J Prosthet Dent* 1970;23(4):394-406.
12. Kawano F, Koran A, Asaoka K, Matsumoto N. Effect of soft denture liner on stress distribution in supporting structures under a denture. *Int J Prosthodont*1993;6(1):43-9.
13. Kawano F, Kon M, Koran A, Matsumoto N. Shock-absorbing behaviour of four processed soft denture liners. *J Prosthet Dent* 1994;72(6):599-605.
14. Jagger DC, Harrison A. Complete dentures — the soft option. An update for general dental practice. *Br Dent J* 1997;182(8):313-7.
15. Wilson HJ, Tomlin HR and Osborne J. Tissue conditioners and functional impression materials. *Br Dent J* 1966;121:9-11.
16. Starcke EN, Fischer TE and Sweeney WT. Physical properties of tissue-conditioning materials as used in functional impressions. *J Prosthet Dent*. 1972;27:111-3.
17. Keni NN, Aras MA, Vidya C. Modified flange complete denture for labially inclined premaxilla. *Indian Journal of Dental Advancements*. 2010;2(2):223-6.
18. Terry BC, Zarb GA. Report on the 4th International Congress on Preprosthetic Surgery, Palm Springs, USA, 18-20 April, 1991. *International journal of oral and maxillofacial surgery*. 1991;20(5):314.



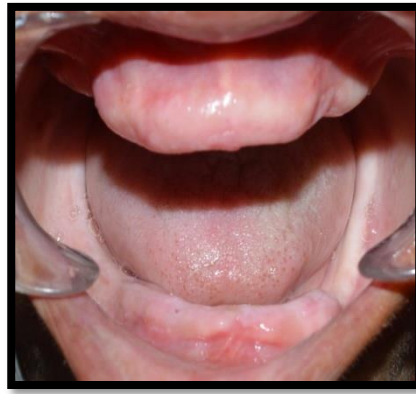

Figure 1: Pre Treatment Intraoral

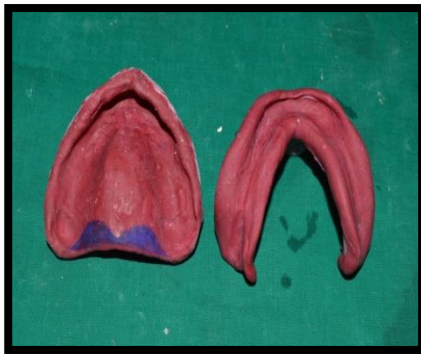

Figure 2: Preliminary Impression

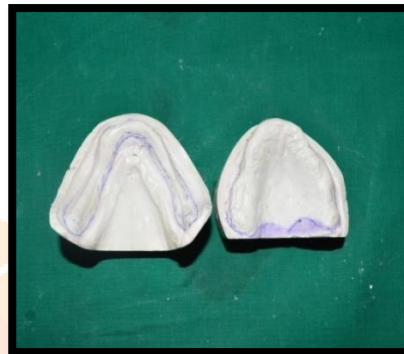

Figure 3: Preliminary Cast

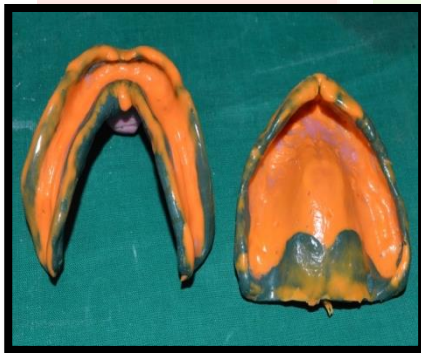

Figure 4: Final Impression

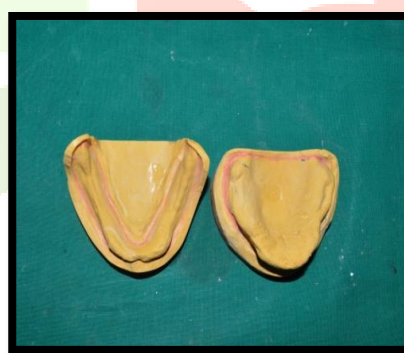


Figure 5: Master Cast

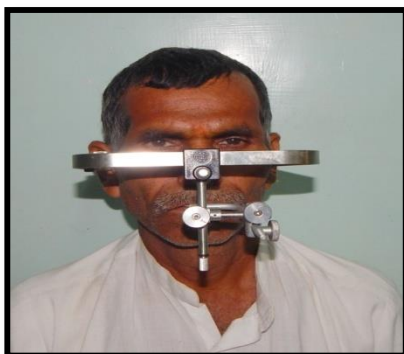

Figure 6: Facebow Record

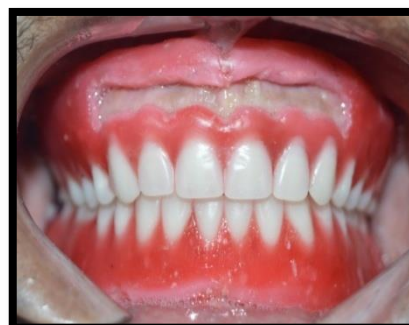

Figure 7: Try in



Figure 8: Putty was indexed during Processing

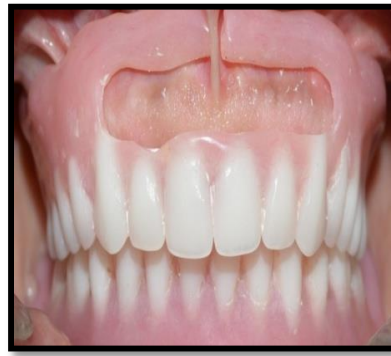

Figure 9: Denture Insertion



Figure 10: Pre Treatment Extraoral



Figure 11: Post Treatment Extraoral