



Approach For Diabetic Retinopathy Analysis using Generalized Feed Forward (GFF) Networks

Ku. ¹Sayali Khushalrao Jirapure

Student of Jagdambha college of engineering and technology Yavatmal (India)

Dr. H .M Baradkar²

Principal (Electronic and Telecommunication) of Jagdambha college of Engineering and technology Yavatmal (India)

Abstract: In this paper classification normal and diabetic retina scan images , which uses the FFT transform over the retina images as feature detector and a constructive one hidden layer multilayer perceptron neural network as classification normal and diabetic retina scan images classifier technique is applied to a database consisting of images of 145 having normal and diabetic retina scan images of 116 are used for network training, and the remaining images of 29 are used for cross validation. It is demonstrated that the best recognition rates are 99.45% for the training and 100% cross validation. Furthermore The Average Classification Accuracy of GFF Neural Network comprising of one hidden layers with 6 PE's organized in a typical topology is found to be superior (99.72 %) for Training . Finally, optimal algorithm has been developed on the basis of the best classifier performance. The algorithm will provide an effective alternative method of Classification of Diabetic Retinopathy using Neural Network Approach.

IndexTerms - Neural network, Microsoft excel, Mat Lab, normal and diabetic retina scan images

I. INTRODUCTION

Damage in the eye due to diabetes is called Diabetic retinopathy (DR) which may occur due to changes in blood glucose level that may lead to changes in retinal blood vessels. It is normally considered as the most common cause of vision loss for the past 50 years. Diabetic retinopathy is vision frightening that occurs in persons with long standing diabetes with progressive damage to the retina of the eye and a leading cause of blindness among working adults if it remains untreated. It can be perceived during dilated eye examination by an ophthalmologist or optometrist. Early detection and proper treatment of DR can help to avoid blindness [1].DR is broadly classified into proliferative diabetic retinopathy (PDR) and non-proliferative diabetic retinopathy (NPDR). In the event of PDR the blood vessels in the retina of the eye get blocked and avoid flow of blood in the eye. Whereby new, but weak vessels begin to form on the retina which supplies blood to the closed area. This status is called neo-vascularization. In the event of NPDR extra fluid will get leaked from the damaged blood vessels along with little amount of blood. This situation leads to the formation of exudates in the retina of the eye.

1. Digital Retinography

1.1 Structure of the eye

A typical retina is shown in Figure 1. It consists of light-sensing cells, an optical nerve head and a network of blood vessels. Light enters through the pupil of the eye and is then focused on the retina. The lens helps to capture images from different distances and the iris controls the amount of light entering the eye. If the light is bright the iris closes and when it is dim it opens [12]. The retina has a thickness of about 0.5mm and lines the inside of the eyeball and has the task of converting light that passes through the eyes into a neural signal that is further processed by the brain.

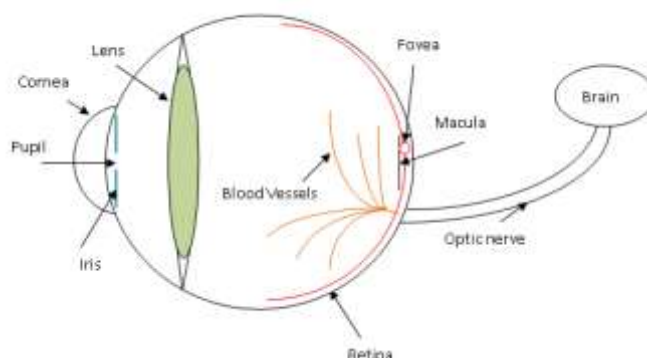


Figure 1. Location of the retina.

Blood vessels transport blood throughout the body and in the retina look like thin elongated structures with different widths and lengths. They vary in thickness in the range 50-200 μ m with a median of 60 μ m [13]. The optic nerve head is shown in Figure 1 and has a mean vertical and horizontal diameter of 1.88 and 1.77 mm, respectively [14]. The vessels emanate from the optic nerve head and branch out to cover most of the retina. Nerves that connect to the brain are all gathered in the optic nerve. The other side of the optic nerve head leads to the brain hence the retina is considered a part of the brain.

The macula is located at the centre of the retina and is considered the area with the highest visual acuteness (Figure 1) [15]. The fovea as shown in Figure 3 is located in the centre of the macula area and is the point where light rays are focused which produces fine details for sharp vision [16, 17].

1.2 Diseases in the eye

The most common diseases that manifest in the eye are diabetic retinopathy which causes the growth of new blood vessels, age-related macular degeneration, glaucoma and cardiovascular disease. All involve damage to the retina which can be observed in retinograms. Figure 1.2 shows examples of normal and abnormal retinograms. The left image shows a normal retinogram where no damage to the blood vessel network or any other structure is present, whilst the right one shows an abnormal one where the optic disc is in the form of an extended yellow patch.

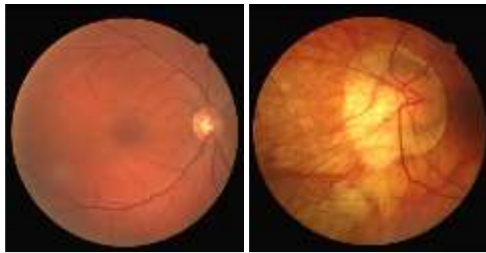


Figure 1.2. Example of retinograms.

Left: Normal retinogram with no signs of disease. Right: Abnormal retinogram. Damage has been caused on the optic disc which is shown as the expanded yellow patch and differs from the normal optic disc shown in the left retinogram. The difference in colour between these two images is a normal variation.

Diabetic Retinopathy affects 80% of people with diabetes worldwide. It is one of the leading causes of blindness in the United States [18, 19] and the second leading cause of blindness in the western world [19]. During pre-proliferative diabetic retinopathy the retinal arteries are weakened and start to leak and form haemorrhages [20]. Microaneurysms (Figure 1.2) which are small red dots are also formed along with dot-haemorrhages. These red dots initiate from the fovea area and expand to different areas of the macular region. They are produced from weakening of vessel walls of the smallest vessels called capillaries. Haemorrhages differ from microaneurysms as they become larger and become flame shaped and expand towards other anatomical structures in their surroundings [21]. Exudates are also formed which are yellow patches with sharp edges. They are plasma protein precipitation or lipoprotein deposits [19] that have been caused by retinal vessel bleeding and appear as white lesions (dots) that have the same size as microaneurysms but can become larger by merging with their neighbouring exudates. At this stage, swelling or Oedema is caused in the retina which impairs vision [12]. Proliferative diabetic retinopathy causes severe bleeding and leakage of blood and an increase of exudates around the macula [20]. This stage is very dangerous for the central vision since retinal exudation expands to the fovea region and causes arterial and capillary closing. White patches called cotton wool spots are also formed. Some areas of the retina become oxygen deprived or ischemic and whilst the circulatory system attempts to maintain adequate oxygen levels, new vessels start to grow which causes changes in vessel diameter leading to changes in the blood vessel network. These new vessels are called neovascularisations [22]. During the final stage, an increase of new blood vessels occurs that causes blindness by either a number of haemorrhages occurring or by retinal detachment from connective tissues of new vessels [19]. Age-related Macular Degeneration (AMD) has two forms: i) Dry AMD where visual acuity is slowly lost and ii) Wet AMD where a growth of vascular structure into the macula is caused. The increase in vascular permeability causes fluid to be gathered underneath the retina which leads to permanent visual loss. Glaucoma involves raised pressure within the eye, causing damage to the optic nerve. Cardiovascular disease which causes deep white spots in the retina, widening of retinal veins and thinning of retinal arteries is another form of disease which manifests in the retina [11].

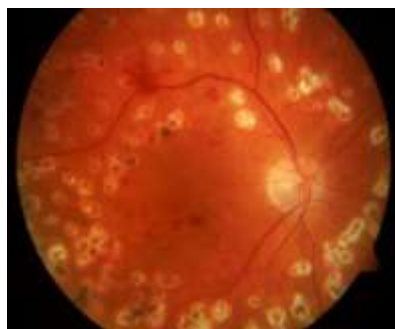

Figure 1.3. Severe diabetic retinopathy

Untreated diabetic retinopathy will cause blindness, therefore monitoring the disease progression via population screening will allow for timely and effective treatment. Screening programs are now taking place in various countries and early detection is only possible through automated analysis since there is too much workload for manual detection [15, 11]. The machine analyses the retinal images of patients and if abnormalities are found, a retinal specialist carries out a detailed diagnosis. Screening should be performed at regular intervals such as every six months to a year. When diabetic retinopathy is identified from screening, successful treatment can be performed by laser surgery and strict glucose control. Blindness cannot be reversed once it has occurred due to diabetic retinopathy but further damage to the retina can be avoided. The laser treatment is called photocoagulation where the laser is directly applied to the leaking microaneurysms so that further haemorrhaging is avoided. A larger part of the retina to reduce the need for oxygen and further damage. Photocoagulation reduces the risk of blindness before blindness has occurred [22].

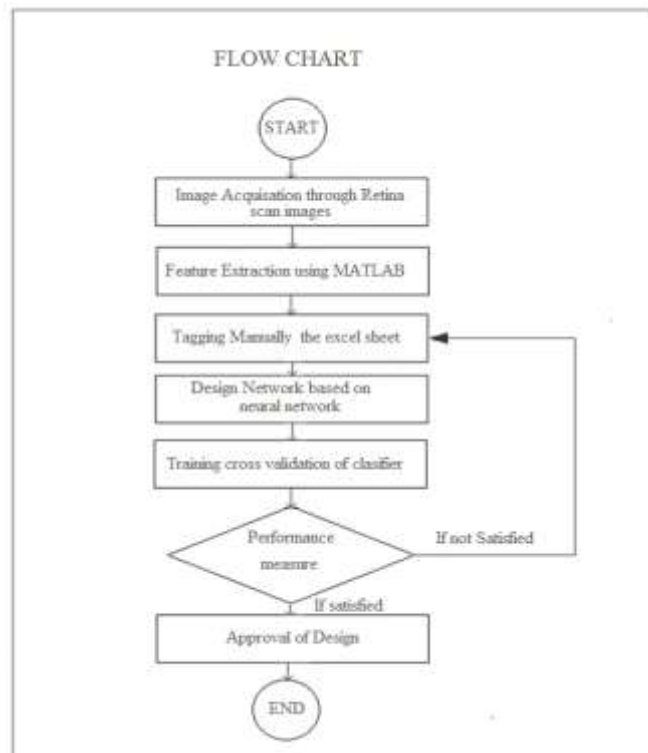
1.3 Contribution

In this project work, the digital retinal fundus images are classified into diabetic or non-diabetic; Diabetic image contains mild to severe signs of non-proliferative DR and nondiabetic does not contain any microaneurysms (MA). The method proposed in this work is to correctly assign the class to which a retinal fundus image could be classified using one rule classifier and back propagation neural network (BPNN) techniques.

1.4 Advantages

- 1) Diabetic Retinopathy diagnosis is an arduous task that needs to be executed scrupulously. The computerization of this system will be extremely advantageous.
- 2) Clinical judgments are usually made based on medical practitioner’s perception and wisdom rather on the technical information available in the database.
- 3) It is not easy for a doctor to have expertise in every subspecialty. This leads to unwanted prejudices, mistakes and unnecessary medical expenses that might affect the quality of service provided to patients.

II. PROPOSED ALGORITHM



In this paper to study classification of diabetic and non diabetic retina images Using Neural Network Approaches... Data acquisition for the proposed classifier designed for the classification of diabetic retinopathy using neural network approach. Image data will be collected from the different- different ophthalmologist hospital. The most important un correlated features as well as coefficient from the images will be extracted .In order to extract features, statistical techniques, image processing techniques, transformed domain will be used.

III. NEURAL NETWORK

Following Neural Networks are tested:

Feed-Forward Neural Networks

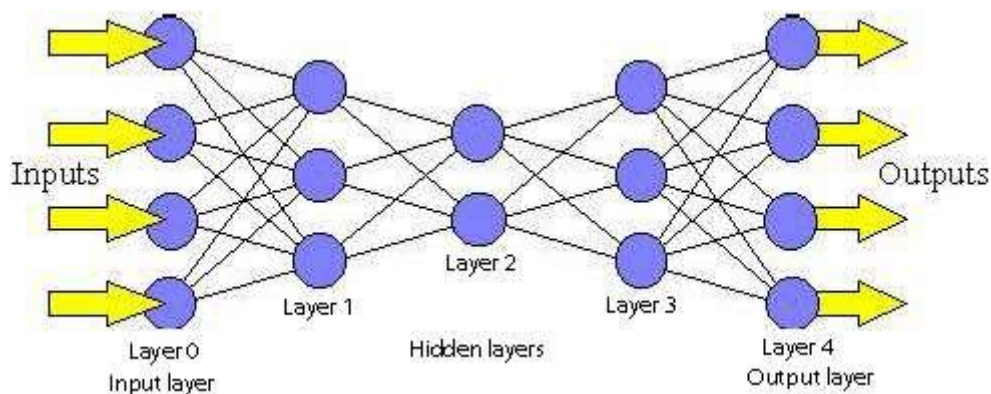


Figure 3.1. A feed-forward network.

Feed-forward networks have the following characteristics:

1. Perceptrons are arranged in layers, with the first layer taking in inputs and the last layer producing outputs. The middle layers have no connection with the external world, and hence are called hidden layers.
2. Each perceptron in one layer is connected to every perceptron on the next layer. Hence information is constantly "fed forward" from one layer to the next. and this explains why these networks are called feed-forward networks.

3. There is no connection among perceptrons in the same layer.

A single perceptron can classify points into two regions that are linearly separable. Now let us extend the discussion into the separation of points into two regions that are not linearly separable. Consider the following network:

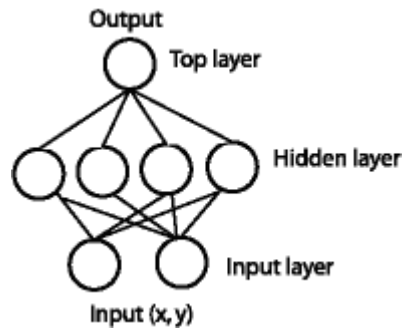


Figure 3.2. A feed-forward network with one hidden layer.

The same (x, y) is fed into the network through the perceptrons in the input layer. With four perceptrons that are independent of each other in the hidden layer, the point is classified into 4 pairs of linearly separable regions, each of which has a unique line separating the region.

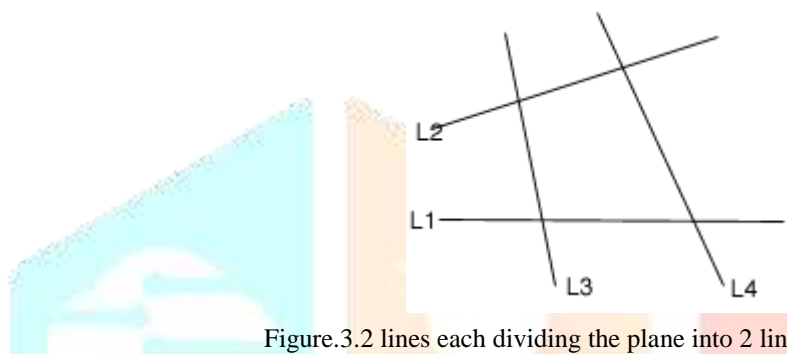


Figure.3.2 lines each dividing the plane into 2 linearly separable regions.

The top perceptron performs logical operations on the outputs of the hidden layers so that the whole network classifies input points in 2 regions that might not be linearly separable. For instance, using the AND operator on these four outputs, one gets the intersection of the 4 regions that forms the center region.

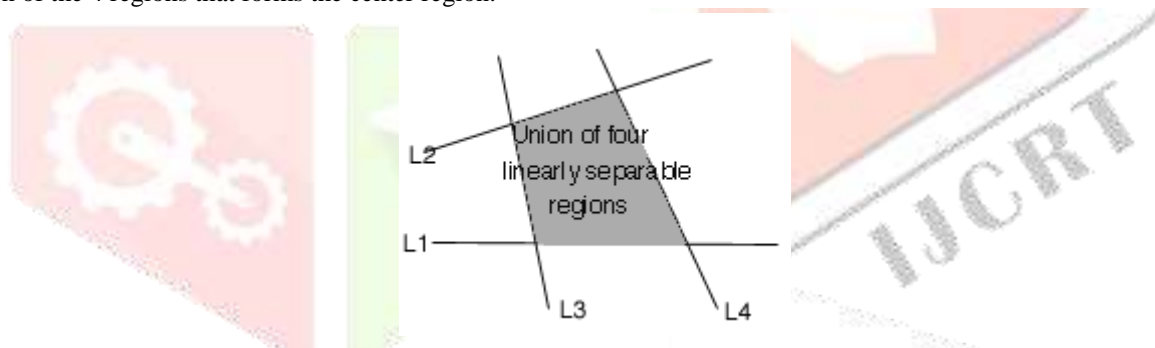


Figure3.3 Intersection of 4 linearly separable regions forms the center region.

By varying the number of nodes in the hidden layer, the number of layers, and the number of input and output nodes, one can classification of points in arbitrary dimension into an arbitrary number of groups. Hence feed-forward networks are commonly used for classification.

3.1 Learning rules of Neural Network

3.1.1 Quick propagation (QP):

Quick propagation (QP) is a heuristic modification of the standard back propagation algorithm. Fahlman introduced QP in 1998. QP is not essentially faster than back propagation even though for some application it may prove faster. QP is more susceptible to instability and may stick to local minimum than back propagation. QP changes the network weights after each case. It is a batch update algorithm. It computes the average gradient of the error surface across all the cases before updating the weights at the end of an epoch.

QP works with the assumption that the error surface is locally quadratic, with the axes of hyper-ellipsoid error surface associated with the weights. If this is true, then the minimum of the error surface can be found after only a couple of epochs. Certainly, the assumption is not generally valid, but if it is close to true, the algorithm can converge to the minimum very quickly. On the first epoch, the weights are changed using same rule as the back propagation, based upon the local gradient and the learning rate. On successive epochs, the quadratic assumption is used to obtain the minimum.

The basic QP formula has a number of limitations. If the error surface is not concave, the algorithm can deviate from the desired value. If gradient changes a little or not at all, then the changes can be extremely large. If the zero error is encountered, a weight will stop changing permanently. On the first epoch, QP updates weights similar to back propagation. Subsequently, weight changes are calculated using the quick propagation equation.

$$\Delta w(t) = \frac{s(t)}{s(t-1)-s(t)} \Delta w(t-1) \quad \dots (19)$$

The system is numerically unstable if $s(t)$ is very close, equal or greater than $s(t-1)$. Since (t) is expressed along the direction of weight gradient, such conditions can only occur if the slope becomes constant, or becomes steeper. In such cases, the weight update formula is

$$\Delta w(t) = \epsilon \alpha \Delta w(t - 1) \dots (20)$$

Where α denotes on acceleration constant

IV. RESULTS SIMULATION

The Best Neural network with maximum accuracy is shown below:

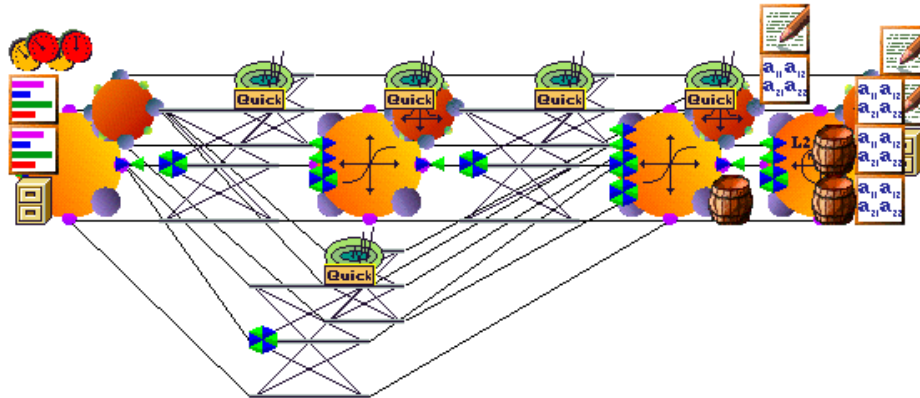


Figure 4.1 The Best Neural network with maximum accuracy

Training Report of the Best Classifier:

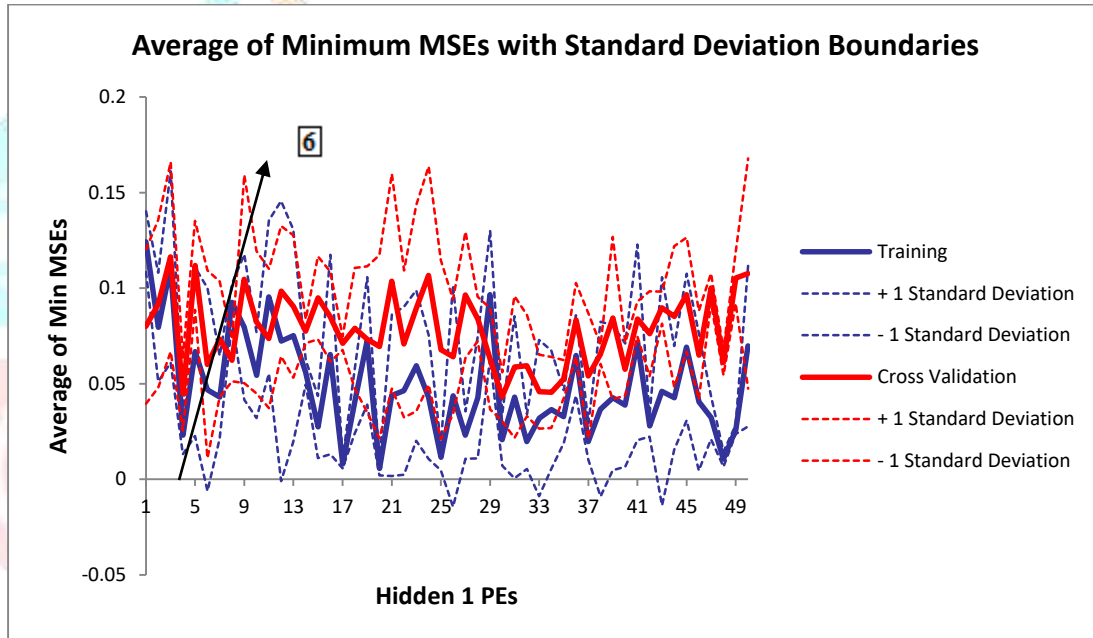


Figure 4.2: Average of Minimum MSEs with Standard Deviation Boundaries

| <i>Best Networks</i> | <i>Training</i> | <i>Cross Validation</i> |
|----------------------|-----------------|-------------------------|
| Hidden 1 PEs | 20 | 6 |
| Run # | 2 | 2 |
| Epoch # | 1000 | 1000 |
| Minimum MSE | 0.003471347 | 0.006384309 |
| Final MSE | 0.003471347 | 0.006384309 |

Table 1: Processing Element Training Data Set

Test on Cross validation (CV):

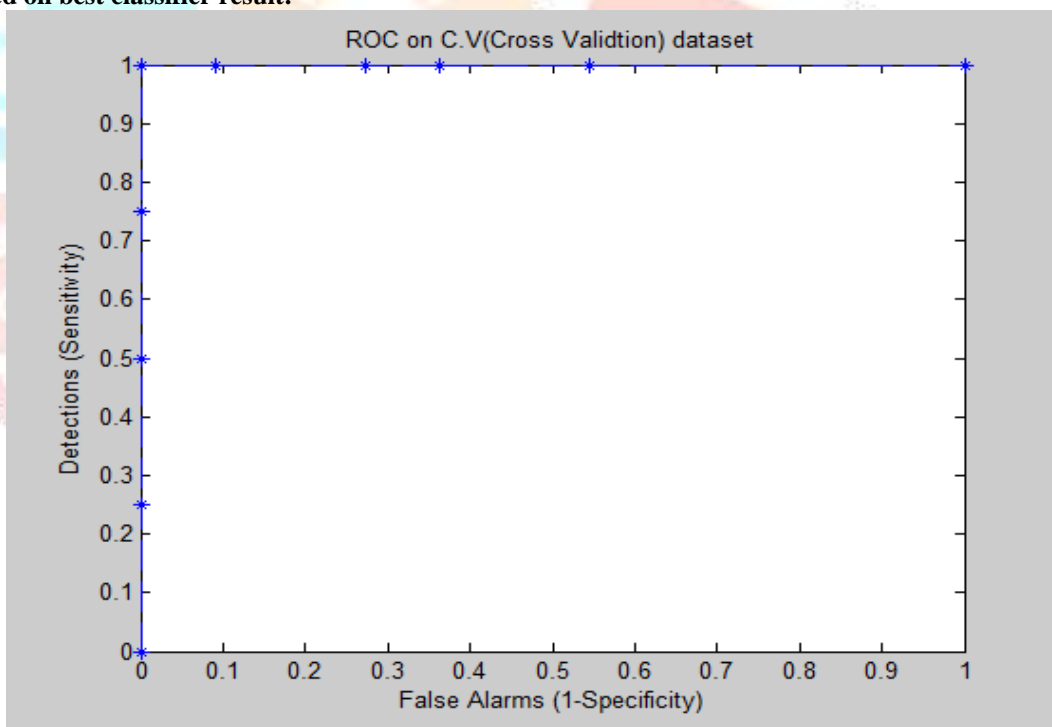
| | | |
|----------------------------|--------------------------|----------------------------|
| Output / Desired | <i>NAME(NORMAL)</i>) | <i>NAME(DIABATIC)</i>) |
| <i>NAME(NORMAL)</i>) | 4 | 0 |
| <i>NAME(DIABATIC)</i>) | 0 | 11 |

Table 2: Confusion matrix of Cross validation (CV)

| <i>Performance</i> | <i>NAME(NORMAL)</i> | <i>NAME(DIABATIC)</i> |
|--------------------|---------------------|-----------------------|
| MSE | 0.032374274 | 0.023520248 |
| NMSE | 0.165550262 | 0.120273995 |
| MAE | 0.102752117 | 0.100140349 |
| Min Abs Error | 0.009902296 | 0.000952562 |
| Max Abs Error | 0.615546209 | 0.358050743 |
| R | 0.918058308 | 0.939541173 |
| Percent Correct | 100 | 100 |

Table 3: Performance Measures for cross validation

ROC curve based on best classifier result:



Area under ROC curve = 1.000000

Test on Training:

| | | |
|----------------------------|--------------------------|----------------------------|
| Output / Desired | <i>NAME(NORMAL)</i>) | <i>NAME(DIABATIC)</i>) |
| <i>NAME(NORMAL)</i>) | 33 | 1 |
| <i>NAME(DIABATIC)</i>) | 0 | 96 |

Table 4: confusion matrix of Training

| <i>Performance</i> | <i>NAME(NORMAL)</i> | <i>NAME(DIABATIC)</i> |
|--------------------|---------------------|-----------------------|
| MSE | 0.019479355 | 0.018589165 |
| NMSE | 0.102843207 | 0.09814336 |
| MAE | 0.094168175 | 0.092339204 |
| Min Abs Error | 0.000104615 | 0.000398675 |
| Max Abs Error | 0.717738502 | 0.546484309 |
| R | 0.951457015 | 0.953907387 |
| Percent Correct | 100 | 98.96907216 |

Table 5: Performance Measures for training

IV. CONCLUSION

From the results obtained in FFT domain it concludes that the GFF Neural Network with QP (Quick Prop) and hidden layer 1 With processing element 6 gives best results of 100% in Cross Validation and 99.45% in Training over all accuracy is 99.72%.

V .Acknowledgment

We are very grateful to our Jagdambha college of engineering and technology Yavatmal to support and other faculty and associates of ENTIC department who are directly & indirectly helped me for these paper.

REFERENCES

- [1] Rajaa D. Reasan ali, Dr Jane j. Stephan , Dr. Ban N. Dhannoon, fingerprint recognition by using extract level3 feature, International Journal of Advanced Computer Technology (IJACT).
- [2] Dr. R. Satya Prasad, Muzhir Shaban Al-Ani, Salwa Mohammed Nejres,'An Efficient Approach for Fingerprint Recognition, International Journal of Engineering Innovation & Research Volume 4, Issue 2
- [3] Iehab AL Rasan, Hanan AlShaherSecuring Mobile Cloud Computing using Biometric Authentication (SMCBA),'2014 International Conference on Computational Science and Computational Intelligence
- [4] Josef Strom Bartunek, Mikael Nilsson, Benny Sallberg, Ingvar Claesson, Adaptive Fingerprint Image Enhancement with Emphasis on Pre-processing of Data, 2013 IEEE.
- [5] Lavanya B N1 and K B Raja1, Performance Evaluation of Fingerprint Identification Based on DCT and DWT using Multiple Matching Techniques. IJCSI International Journal of Computer Science Issues, Vol. 8, Issue 6, No 1, November 2011
- [6]Reza ABRISHAMBAF, Hasan DEMIREL, Izzet KALE, A Fully CNN Based Fingerprint Recognition System, 2008 IEEE.
- [7] S.Arivazhagan, T.G.ArulFlora, L.Ganesan, Fingerprint Verification using Gabor Co-occurrence Features, 2007 IEEE.
- [8] Mariano Fons, Francisco Fons, Enrique Cantó, Design of an Embedded Fingerprint Matcher System, 2006 IEEE
- [9] F.A. Afsar, M. Arif and M. Hussain, Fingerprint Identification and Verification System using Minutiae Matching, National Conference on Emerging Technologies IEEE2004
- [10] Marius Tico, Pauli Kuosmanen, Fingerprint Matching Using an Orientation-Based Minutia Descriptor, IEEE transactions on pattern analysis and machine intelligence, vol. 25, no. 8, august 2003
- [11] M. D. Abramoff, M. K. Garvin, and M. Sonka,(2010) "Retinal imaging and image analysis," IEEE Reviews in Biomedical Engineering, 3:169–208.
- [12] M.I Iqbal, N.S Gubbal, A.M Aibinu, A. Khan (2006), "Automatic diagnosis of diabetic retinopathy using fundus images", Blenkinge Institute of Technology.
- [13] R.M Rangayyan, F. Oloumi (2007), "Detection of blood vessels in the retina using Gabor filters", Canadian Conference on Electrical and Computer Engineering, 1-3: 717-720.
- [14] H. A.Harry. Quigley; A.E. Brown; J.D. Morrison, MD; S M. Drance (1990), "The Size and Shape of the Optic Disc in Normal Human Eyes" Arch Ophthalmol : 108(1):51-57. 184
- [15] S. Ravishankar, A. Jain, A. Mittal (2009), "Automated feature extraction for early detection of diabetic retinopathy in fundus images", IEEE Conference on Computer Vision and Pattern Recognition.

- [16] H. Kolb, E Fernandez and R. Nelson (2002), Webvision: The Organization of the Retina and Visual System. <http://www.webvision.med.utah.edu>. Date of last access: 09/02/2014.
- [17] A. Osareh, B. Shadgar (2009), "Automatic blood vessel segmentation in colour images of retina" Iranian Journal of Science and Technology Transaction B-Engineering, 33(B2): 191-206.
- [18] K S, Coyne , MK Margolis, T K Martin , TM Baker, R Klein , M D Paul (2004), "The impact of diabetic retinopathy: perspectives from patient focus groups". FamPract21:447-453.
- [19] C .Agurto, E. S. Barriga,V. Murray, S. Nemeth, R. Crammer,W. Bauman, G. Zamora, S. M Pattichis, and P Soliz (2011), "Automatic detection of diabetic retinopathy and age-related macular degeneration in digital fundus images". Investigative Ophthalmology and Visual Sciences (IOVS).52(8):5862-71.
- [20] M. J. Cree and H. F. Jelinek, "Image analysis of retinal images", chapter 11:263.

