

Identification of Alzheimer's disease using Image Analysis

¹Arun Kumar, ²Vaibhav Jotania, ³Yash Mav, ⁴Mohammed Malpara, ⁵Swati Shinde

¹Student, ²Student, ³Student, ⁴Student, ⁴Assistant Professor

¹EXTC,

¹KJSIEIT, Mumbai, India

Abstract: Alzheimer's disease (AD) is a condition that attacks the brain's grey matter which results in loss of memory, thinking, language skills and difficulty in mental tasks. Alzheimer's is the most common type of dementia. The total brain withering and specifically hippocampal withering are considered as the strong diagnostics of AD. Research is ongoing to diagnose these neurodegenerative disorders in the early stages. Early diagnosis helps patients to obtain the maximum treatment benefit before significant mental decline occurs. The work presented in this paper evaluates the utility of image processing on the Magnetic Resonance Imaging (MRI) scans to estimate the possibility of an early detection of AD. Image processing techniques such as Pre-processing for intensity adjustment, K-means clustering, such as Region growing algorithm for extraction of white matter and grey matter for calculation of brain volume are tailored for specific cases. To calculate the brain volume we consider three planes of brain such as axial plane, coronal plane and sagittal plane by obtaining the region of interest.

I. INTRODUCTION

Human brain is the most advanced organ and is the center of system that controls all necessary functions of body. Any abnormal behavior of brain results in total collapse of entire body practicality. One such brain abnormality could end in Alzheimer's disease. AD is a neurodegenerative illness of brain that causes changes in brain. AD commonly affects folks over the age of sixty leading to a progressive decline in memory. AD is named after Dr. Alois Alzheimer in 1906 once he noticed changes in brain tissue of a girl who died as a result of uncommon mental illness. Her symptoms enclosed amnesia, language drawback and unpredictable behavior. He examined her brain and located several abnormal clumps (now known as amyloid plaques and neurofibrillary tangles). The 2 main options of AD square measure Plaques and Tangles. Alternative cause is attributable to loss of connections between neurons as shown in Fig. 1. The first feature of chronic method concerned in AD is recognized as Hippocampal atrophy. Diminished in hippocampal volume seems to be correlative to early decline of memory. The most symptoms of AD square measure amnesia and confusion. Alternative symptoms embrace misplacing things in applicable places, issues in speech, forceful changes in temperament and problem in activity acquainted task. The current work explores brain atrophy and hippocampal atrophy because the main indicators of AD as a result of overall atrophy will occur attributable to alternative reasons like age and alcoholism.

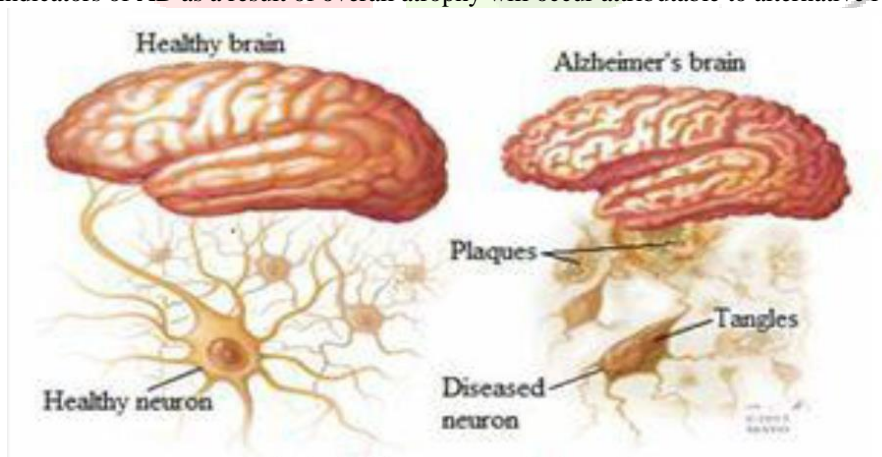


Fig 1: Healthy brain vs Alzheimer's brain

II. MATHEMATICAL MODELLING

A. Magnetic Resonance Imaging (MRI) MRI scans are used as raw input image which can be used to produce activation maps that shows which parts of the brain are affected. It detects changes in blood oxygenation and flow that occurs in response in the neural activity.

B. Pre-processing Image pre-processing is used to perform operation on images at the lowest level whose aim is to enhance image features that suppress the undesired distortions and does not increase image information content. In pre-processing image resizing, image conversion and intensity adjustment is done.

C. Region growing algorithm K-means Clustering K-means algorithm is an unsupervised clustering algorithm that classifies the input data points into multiple classes

Region growing is a simple region based image segmentation method which is classified as a pixel-based image segmentation method that involves the selection of initial seed points. It is a method of partitioning an image into similar areas of connected pixels.

D. Calculation of Brain volume In order to calculate the total volume of brain, three planes of brain is considered i.e. axial plane, coronal plane and sagittal plane. The volume of brain obtained from each of the plane differs as each plane has different amount of grey matter and white matter. Adding the volume of all planes gives the overall brain volume.

E. Detection of Alzheimer’s disease after segmenting the volumes of overall brain, white and gray matter is obtained. By calculating the ratio of grey to white matter Alzheimer’s disease is detected.

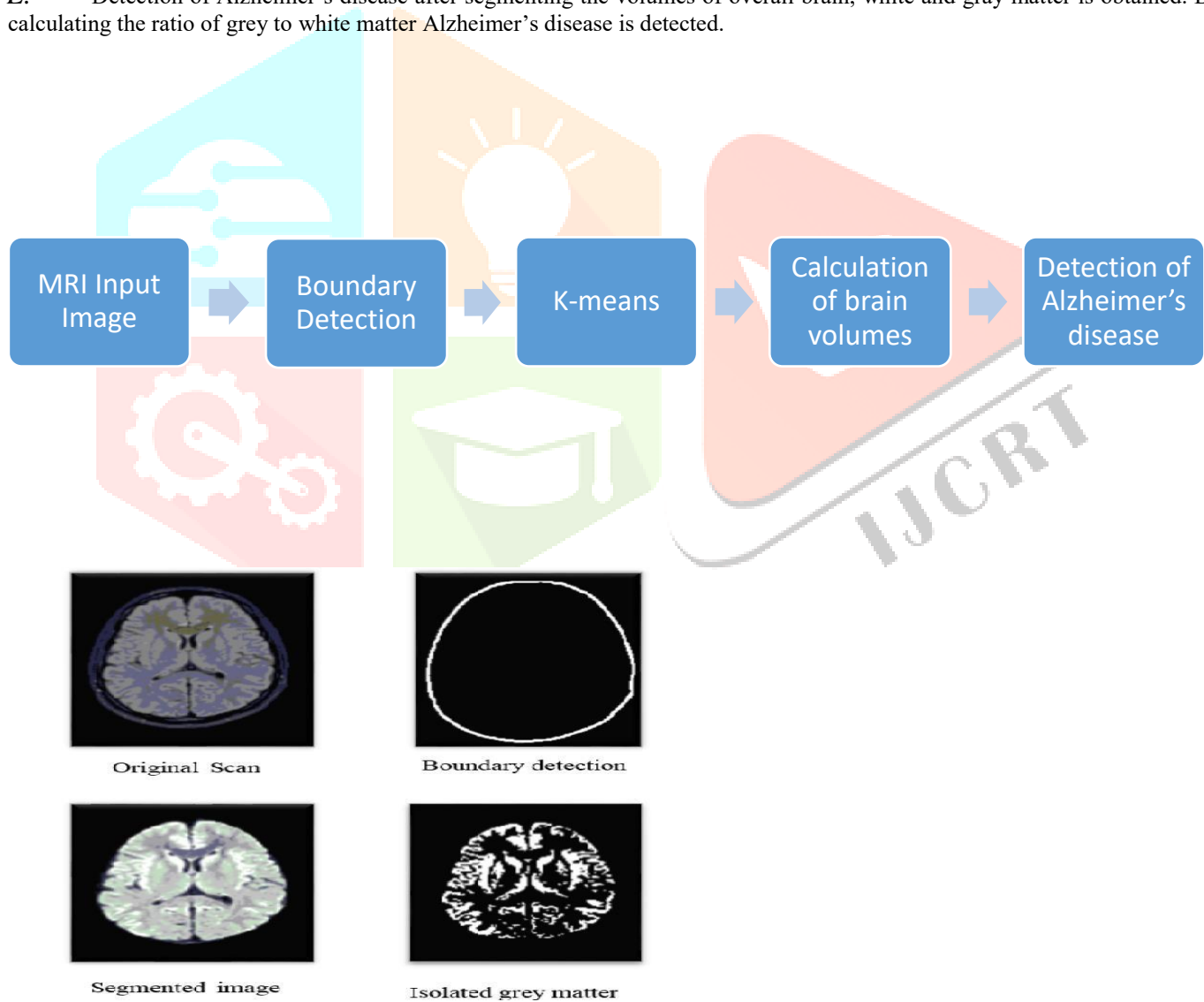


Fig 2: Calculation of grey matter

III. IMPLEMENTATION

This project is initially designed and tested on the MATLAB platform. However, MATLAB is a proprietary platform and it is very unlikely that the hospital laboratories would be equipped with MATLAB. Owing to the growing demand for open source implementations and the associated benefits, the image processing algorithms mentioned above can be transferred from MATLAB to OpenCV software.

There are two solutions the program offers, the first being to calculate the overall brain (grey and white matter) volume and the second, to calculate the hippocampi. The K-means code can be implemented and tested using OpenCV and C/C++ libraries and the segmentation results. Many other functions such as convolution, erode, dilate, RGB to greyscale, region extraction, area calculation can be transferred from MATLAB to OpenCV. K-means can be used as the basic segmentation technique to calculate brain volume. The process segments the MRI scan into grey matter and white matter and calculates the area of each segment. The challenge in the process is the associated noise and the cranium which hampers the segmentation. The solution is available as a Win32 executable file which can be run on any system without any software requirement. The output indicates the grey matter, white matter and the total volume of the brain. The hippocampal isolation and volume calculation process works on similar lines but with some challenges and differences. The hippocampi present in the brain constitute a small part of the brain but the hippocampal volume is a vital indicator in the detection of Alzheimer's disease. Owing to the small size of the hippocampi and the noise present in the MRI it is difficult to isolate the hippocampi. Filtering techniques are utilized to reduce the noise and the image is cropped interactively to further reduce the error probability. The user is expected to mark the smallest rectangular region containing the hippocampi using the selection tool. This further enhances the accuracy of the algorithm. The process is repeated for a series of MRI scans containing the hippocampi and the volume of the hippocampi is estimated. The output of the program is the volume of the hippocampi.

The two targeted processes namely the brain volume and the hippocampal volume calculation have been implemented successfully. The results for brain volume calculation are as shown in Table 1. The comparison of the grey and white matter in each case helps us conclude as to whether the patient is healthy, going through atrophy due to age or AD. In case of healthy patient the brain volume corresponds to that of a healthy brain i.e. without atrophy. In case of atrophy due to age, the difference between the grey matter and white matter volume is not significant and so it is possible to distinguish between atrophy due to age and atrophy due to Alzheimer's. In case both the overall brain volume is less and the difference between the grey matter and white matter volume is higher, then it is most likely a case of Alzheimer's. For instance, Patient no. 18 – Atrophy; Patient no. 19 – atrophy and possible AD; Patient no. 20 – huge difference in grey to white matter ratio and hence confirmed AD. In the case of hippocampal isolation, the devised algorithm, which uses watershed and filtering, is seen to isolate the hippocampus. These results validated by the doctors. This algorithm takes into consideration the ROI where the hippocampus is present thereby ensuring that it is generalized and applicable to all cases and interactive segmentation is used to improve the accuracy. Hippocampal volume is a vital parameter in the detection of Alzheimer's and the comparison of its volume along with the overall volume of brain provides a very strong ground for the detection of Alzheimer's disease. The methods have been tested on several data sets obtained from the hospital and the results have proved the efficiency of the algorithm.

Based on our project, we expect to detect AD at the earliest by comparison of grey matter and white matter and also detect the stage of the condition.

Sample no	Age	Gray matter %	White matter %	Gray/white matter ratio	Comment
1.	52	41.3110	58.68	0.7039	normal
2.	58	35.05	64.941	0.5399	1 st stage
3.	60	32.53	67.46	0.4823	2 nd stage

Table 1: Stages of Alzheimer's Disease

IV. RESULTS AND DISCUSSION

- The main area of application of this project is in hospitals to detect AD at the earliest.
- Can be used in research
- Can be used in Medical colleges to teach about AD.

FUTURE SCOPE

As the Technology is new there can be various Future scope and further development options for Image Analysis, some them are listed below

- Using PET scans and CT scans along with MRI scans
- Mobile Application based detection
- Identification of stages
- Calculation of loss of neural networks for identification

IV. CONCLUSION

MRI Scans are used to gather data for detection. In this process we are using a k-means algorithm which is highly useful to find the diseased area in the scanned image. The final outcome of the image is that it detects whether the patient is suffering from Alzheimer's diseases or not.

REFERENCES

- [1] Ashford, J., Rosen, A., Adamson, M., Bayley, P., Sabri, O., Furst, A., and Simmons (2011). "Magnetic Resonance Imaging and Magnetic Resonance Spectroscopy for detection of early Alzheimer's disease". *Journal of Alzheimer's disease*, 26, 307-319.
- [2] Beatrice Duthey (2013) "Alzheimer Disease and other Dementias" London, U.K. Oxford University Press.
- [3] Dr. K.D. Desai, (2012) "Effective early detection of Alzheimer's and Dementia disease using Brain MRI Scan Images" *International Journal of Emerging Technology and Advanced Engineering*, volume 2, Issue 4.
- [4] Kuhn, Daniel, and Bennett, David (2011). "Alzheimer's Early Stages" 2nd ed.", Hunter House: USA. ISBN-10: 0897933974 | ISBN-13: 978-0-89793-397-1.
- [5] Olga Miljković, "Image Pre-Processing Tool" College of Computer Science, Megatrend University, 2009.