

ENAMEL ISLAND TECHNIQUE REVISITED

Dr Anup Gopi, Dr Poonam Prakash, Dr Prashant Awasti

INTRODUCTION:

The precise relation of maxillary and mandibular casts in accurate occlusion is the most important step in fixed prosthodontics. It is easier to articulate the casts without a record when they can be accurately related by hand into maximum intercuspation. However, when several teeth are prepared or missing, a separate interocclusal record may be required.

Interocclusal records are the means by which the inter-arch relationships are transferred from the mouth to an articulator.[1] In the absence of definitive occlusal contacts, a definitive interocclusal record is required to articulate the maxillary & the mandibular teeth. This becomes even more important when the distal most tooth in the arch is to be prepared as an abutment for a fixed partial denture. An accurate interocclusal record and correct mounting of the casts on an adjustable articulator allows proper alignment of the opposing teeth, creation of anatomic details and accurate intercuspation of the teeth post rehabilitation. Failure to capture an accurate interocclusal record will result in time-consuming chairside adjustments, the need for remounting casts and possible refabrication of the prosthesis.[2]

This article describes a method of making an accurate interocclusal record when the most distal tooth is an abutment for a fixed partial denture. In this method a centric stop or vertical stop is prepared on the distal abutment to maintain the vertical dimension of occlusion and to act as third point of reference for a stable occlusal relationship when occluding the definitive casts on articulators.

CASE REPORT:

A 45 year old lady reported with a chief complaint of missing lower right back teeth since a year. On eliciting the history, her tooth was extracted following pain & swelling secondary to a failed RCT. On examination, the patient had a broad smile and competent lips. She had a complement of 29 teeth with a missing upper premolar & the upper third molar was unerrupted. Occlusion revealed group function occlusion with an Angle's class I molar relation. Considering the clinical presentation, radiological assessment and the patient's requirement of a fixed tooth for grinding, various treatment options were discussed. Since the patient was unwilling for an implant placement, it was decided to replace missing 47 with a three unit fixed partial denture with full coverage porcelain fused to metal retainer on 46, a modified ridge lap pontic and a full coverage metal retainer on 48 (Fig-1). Written consent was obtained. Considering that the anatomy of the distal most teeth, which was planned to be used as an abutment, and its role in providing a stable intercuspation on the right side it was decided to use the enamel island technique of FPD fabrication. Abutment preparation was completed leaving the mesiobuccal cusp of 48 intact & in occlusion with its opposing teeth (Fig-2). Gingival retraction was done using 000 alum impregnated cord and impressions made using elastomeric impression material. The impression was poured in Type IV gypsum and the cast was retrieved. A face bow recording was done to transfer the upper cast to the articulator and the lower cast was mounted in maximum intercuspation (Fig-3). Following this, the enamel island on 48 was reduced intra orally using a straight fissure bur (Fig-4). Similar reduction of the cusp is done over the mounted cast using the same bur and in a similar angulation. Separating media was applied over the tooth and an acrylic coping is prepared over it using autopolymerising resin (Fig-5). The coping was removed from the cast and tried intraorally over the same tooth to evaluate for proper fit (Fig-6). A proper fit, confirms even reduction of the enamel island both intra orally & extra orally. Provisional restoration was fabricated using autopolymerising resin (DPI clear; Dental products of India, Mumbai). Wax pattern was fabricated and its relation checked on the articulator in all excursive movements for

adequate clearance. Coping trial was done taking adequate care to ensure the precise fit of the retainers(Fig-7). Try in was done before glaze firing and the esthetics & occlusion was checked and corrected (Fig-8). The prosthesis was cemented using glass ionomer luting cement. Post insertion instructions were given following which the patient was reviewed after 03 months & oral hygiene was reinforced

DISCUSSION:

For opposing casts to occlude accurately, a tripod of vertical support and horizontal stability must exist between the casts. To ensure that there are sufficient numbers of occluding teeth to mount working and opposing casts in maximum intercuspation, as well as horizontal stability, casts must reproduce the full dental arch. When terminal teeth are prepared for crowns or fixed partial dentures and the third leg of the tripod is lost, the dentist must fabricate an interocclusal record to recapture the lost leg and create a tripod of vertical support to mount casts accurately.[3]

Ideal requirements of interocclusal recording materials are:[4 -11]

1. The materials should offer limited resistance before setting to avoid displacing the teeth or mandible during closure, whereas after setting, it should be rigid or resilient, with minimal dimensional change
2. It should be easy to manipulate with no adverse effect on the tissues involved in the recording procedures.
3. It should accurately record the incisal and occlusal surfaces of teeth
4. It should be verifiable.

Commonly used interocclusal recording materials are:

1. Base plate wax
2. Plaster of Paris
3. Zinc oxide eugenol paste
4. Rubber base and silicone materials
5. Acrylic resin

Techniques to record maxillomandibular relationship:

- 1) Dawson's technique: [12]

Bilateral manipulation is used to guide the mandible to centric relation and this relation is recorded using the following recording techniques:

a) Wax bite record: a brittle hard wax is used for this technique. Wax is softened and placed against the upper arch to indent it. The mandible is manipulated to CR and patient closes into wax. Keep upward loading compression on the condyles as the patient closes, otherwise the patient may protrude the jaw. There should be no impingement into soft tissues.

b) Anterior stop technique: when the mandible is closed, the lower incisors strike against a stop that is precisely fitted against the upper incisors. The stop should be thin enough so that the first point of tooth contact barely misses but under no circumstances should any posterior tooth be allowed to contact when the anterior stop is in place. A firm setting bite registration paste is injected between the posterior teeth and allowed to set.

c) Record for edentulous ridges: when large edentulous areas are present, a wax occlusal rim base can be adapted on a cast of the arch. Ask the patient to lightly bite into the wax. Chill the wax record to harden it and add putty silicone or zinc oxide paste into indentations over

it. Manipulate to a verified centric relation and ask the patient to close into the indentations. The soft putty silicone will adapt to the opposing ridge.

2) Triple tray technique:[13]

A plastic impression tray is used in this method to carry the interocclusal registration material. The excess film that covers the unprepared teeth is trimmed away. The bite registration material is evenly applied on to both top and bottom of the frame and inserted in a tray into the mouth, centring the loaded portion over the prepared tooth or teeth. Cut off any material that extends over the unprepared teeth adjacent to preparation. Remove the excess thickness of the record so that only the imprint of cusp tip should remain. The part of the record facial to the mandibular buccal cusp tips is cut off all the way through the posterior member of the frame and the facial segment of the record is discarded.

3) The enamel island method:[14]

This is a method which preserves a centric stop on an abutment to act as an aid for registering an accurate interocclusal records by creating a vertical stop on the enamel of the abutment. The most prominent cusp in occlusion can be used as shown in this case or a stop can be made of composite restorative material or a metal core covered with composite when the most distal teeth is an abutment. After the cast is mounted in the articulator the cone is removed or the cusp is reduced as done in this case.

Step wise procedure for vertical cone preparation on a natural teeth abutment:

1. Isolate the desired abutment and keep it dry.
2. Use an articulating paper to identify the vertical stop.
3. With a bur or a diamond rotary instrument prepare the entire abutment leaving a slightly tapered island (cone) of enamel in contact with the teeth in the opposing arch.
4. Make the final impression & do not allow the tray to contact the cone.
5. Place the provisional restoration by leaving an opening for the cone.
6. Pour the final impression.
7. Mount the definitive cast in the articulator using the cone as a third point of reference for a stable occlusal relationship when occluding the definitive cast with the opposite cast.
8. Remove the cone from the cast, maintaining the contour of the occlusal surface of the preparation and fabricate the prosthesis.
9. Remove the cone from the abutment in the mouth in a similar manner using an acrylic coping made over the trimmed cast for evaluation if necessary.
10. Insert the final prosthesis.

Limitations

1. The abutment must be a natural tooth.
2. An enamel cone containing an oblique plane may cause instability of the vertical stop, which may result in an inaccurate interocclusal relationship.
3. Creation of a wide island (cone) to achieve stability requires a large volume of enamel to be removed which may result in inaccuracy of the prepared occlusal surface.

Alternatively, the stop may also be made either using a cone made of composite restorative material or a metal-reinforced cone on an endodontically treated abutment wherein a metal core can be cemented with a projection contacting the opposing

4) Interocclusal registration technique with avacuum-formed matrix:[15]

On the teeth opposing the planned abutments, a 0.20-inch vacuum-formed matrix is made. Prepare the opposing teeth abutments and make the definitive impression in the material of choice. Place the matrix on the opposing dentition and ensure that it clears the opposing occlusion completely. Add autopolymerising acrylic resin to the surface of the matrix to record a cusp of the preparation in maximum intercuspation or centric occlusion.

5) Direct intraoral fabrication of transfer copings and interocclusal record using flowable, light-cured composite resin:[2]

Lightly lubricate the prepared abutment teeth and the occlusal surface of the opposing teeth with petroleum jelly. Dispense flowable composite on the abutment tooth and light cure for 10 seconds. The thickness of the composite should not be more than 1 mm. The extension of coping to one half of the occluso-gingival length of the axial walls is sufficient to provide positive seating of the coping on the dies. Using the dispensing syringe, introduce flowable resin between the occlusal surface of the coping and the buccal cusps of the opposing tooth. Light cure the composite in this position for 10 seconds. Send the copings to the lab along with the final impression and the opposing cast. After indexing, the lab technician will place the copings on the dies and mount the casts.

6) Intraoral acrylic resin coping for interocclusal records:[11,16]

Select a preformed polyethylene core former of appropriate size, to fit loosely onto an abutment tooth. Fill the polyethylene matrix (about one-third) with the resin mixture, and place it over the prepared tooth and verify that there is adequate occlusal clearance. Remove the coping and light cure it. Separate the resin coping from the polyethylene matrix. Lubricate occlusal surfaces of antagonistic teeth with petroleum jelly. Add small quantities of low shrinkage autopolymerising acrylic resin to the occlusal surface of the coping and ask the patient to close into maximum intercuspation. Keep teeth in contact until complete polymerization. After polymerization, the record is trimmed to remove flash, leaving the impression of the opposing cusps intact.

7) Interocclusal records for implant in patients with posterior edentulism:[17]

Make the definitive impression of the implants. Connect castable plastic burnout abutments to the implants. The abutments should permit rotation to connect multiple implants. Adjust the height of the abutments to the available interocclusal distance. Connect the abutments together intraorally with a low-shrinkage autopolymerizing acrylic resin and create a platform to act as a carrier for the interocclusal registration material. Make index grooves on the top of the platform to orient the interocclusal registration material. Proceed with the interocclusal registration with a suitable material such as vinyl polysiloxanes [Figure 8].

CONCLUSION:

Wax is an unfavorable material for interocclusal registration, it is the most utilized material in the dental practice due to its ease of handling, clinical versatility, ease of corrections and low cost. Combinations of wax with rigid materials like Zinc oxide eugenol paste and acrylic resin have also been used as they incorporate less error. However, these have their own drawbacks. The major problem with Zinc oxide eugenol paste is that it is a brittle material that tends to adhere to the teeth and when used in excess, it may distort. Acrylic resin and elastomeric bite registration material are the most commonly used materials today apart from digital methods of bite recording.

The procedures described here used the enamel island (cones) as a third point of reference to make a stable occlusal relationship when occluding the definitive casts on articulators. It helps to achieve a precise interocclusal record by creating a vertical stop or enamel island on the most

distal abutment. The combination of the most suitable material & the most appropriate technique as decided by the operator on a case to case basis should be used.



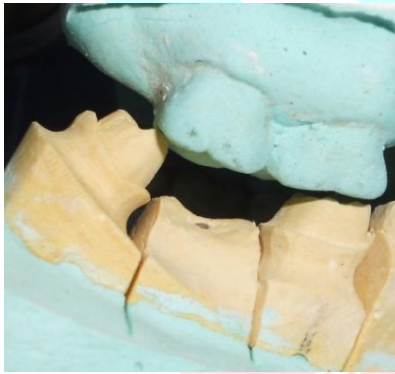
REFERENCES:

1. The glossary of prosthodontic terms. *J Prosthet Dent* 2005;94:10-92.
2. Marjan Moghadam, Bijan Moghadam: A simplified technique for making an interocclusal record in fixed prosthodontics. *NYS DJ* • JUNE/JULY 2005.
3. Freilich MA, Altieri JV, Wahle JJ. Principles for selecting interocclusal records for articulation of dentate and partially dentate casts. *J Prosthet Dent* 1992;68:361-7.
4. Warren K, Capp N. A review of principles and techniques for making interocclusal records for mounting working casts. *Int J Prosthodont* 1990;3:341-8.
5. Malone WFP, Koth DL. *Tylman's Theory and Practice of Fixed Prosthodontics*. 8th ed. Ishiyaku Euro America, Inc. Publishers. Tokyo. St. Louis.
6. Squier RS. Jaw relation records for fixed prosthodontics. *Dent Clin North Am* 2004;48:471-86.
7. Skurnik H. Resin registration for interocclusal records. *J Prosthet Dent* 1977;37:164-72.
8. Millstein PL, Clark RE. Differential accuracy of silicone-body and self-curing resin interocclusal records and associated weight loss. *J Prosthet Dent* 1981;46:380-4.
9. Millstein PL, Clark RE, Kronman JH. Determination of the accuracy of wax interocclusal registrations. II. *J Prosthet Dent* 1973;29:40-5.
10. Fattore L, Malone WF, Sandrik JL, Mazur B, Hart T. Clinical evaluation of the accuracy of interocclusal recording materials. *J Prosthet Dent* 1984;51:152-7.
11. Stamoulis K. Intraoral acrylic resin coping fabrication for making interocclusal records. *J Prosthodont* 2009;18:184-7.
12. Peter E. Dawson: *Functional occlusion: from TMJ to smile design*. Mosby (Elsevier) 2007, pages 93-97.
13. Shillinburg H T, Hobo S: *Fundamentals of fixed prosthodontics*. Third edition, Quintessence books, 2002, pages 41-43.
14. Sonune, et al: An accurate interocclusal record by creating a vertical stop. *The Journal of Indian Prosthodontic Society* 2005;5:119-121.
15. Steven Reed Curtis: Interocclusal registration technique with a vacuum formed matrix. *J Prosthet Dent* 2003;90:308-9.
16. William FP, David L: *Tylman's theory and practice of fixed prosthodontics*. Eighth Edition, medico dental publishing, 2000, page 275.
17. Haralampos P. Petridis: Stable interocclusal records for implant patients with posterior edentulism. *J Prosthet Dent* 2004;92:503.

PHOTOGRAPHS:

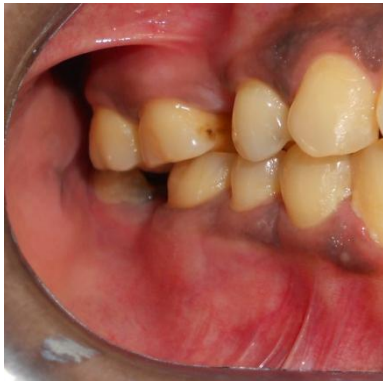
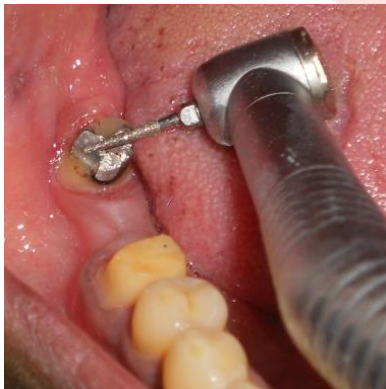
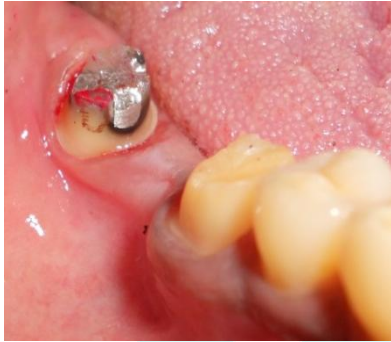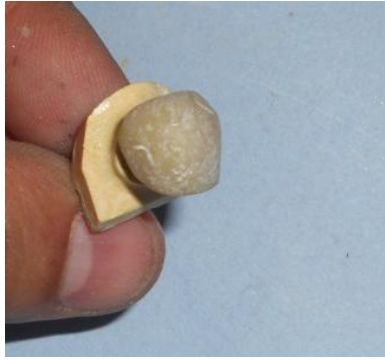FIGURE-1

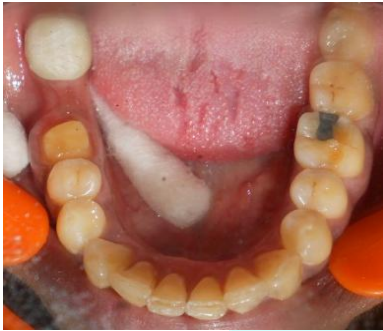



LEGENDS TO PHOTOGRAPHS:

[Redacted]

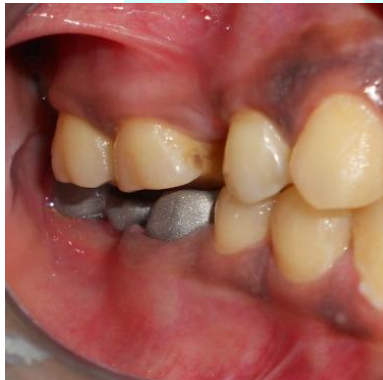[Redacted]



[Redacted]

[Redacted]

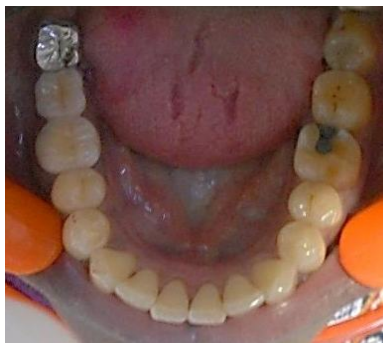[Redacted]



[Redacted]

[Redacted]

[Redacted]



[Redacted]

[Redacted]