

# POSTERIOR MAXILLARY REHABILITATION WITH HYBRID IMPLANT: A CASE REPORT

<sup>1</sup>Col (Dr) M Panwar, <sup>2</sup>Surg Lt Cdr (Dr) Oliver Jacob, <sup>3</sup>Lt Col (Dr) M Kosala, <sup>4</sup>Sqn Ldr (Dr) Navneet

<sup>1</sup>Associate Professor, <sup>2</sup>Resident, <sup>3</sup>Reader, <sup>4</sup>Resident

Division of Periodontology, Dept of Dental Surgery and Oral Health Sciences, Armed Forces Medical College, Pune, India

**Abstract:** Loss of tooth is a common problem and its replacement has evolved from removable dentures and fixed dentures to dental implants. The ultimate aim of Prosthetic dentistry is replacement of missing teeth so as to restore function and to a certain extent aesthetics. An implant eliminates the need of deriving support from the oral mucosa in a partially edentulous case, as well as reduces the necessity to derive support from one or more adjacent teeth and focuses on deriving the support from the underlying bone mimicking a natural tooth. Deficiency of residual bone has been a challenge since the inception of implant dentistry. Utilizing a strong basal bone as a support has opened up a new arena in this aspect without the use of graft. Hybrid implants are one such alternative in the functional and aesthetic restoration in regions of narrow residual ridges.

**Key words:** Hybrid implants, Sub-periosteal implants, Maxillary posterior rehabilitation

## I. Introduction

Advanced jawbone resorption, presents a humongous challenge in placing conventional endosteal implants. Patients who are not good candidates for traditional or small-sized dental implants due to deficiencies of residual bone need to undergo major surgery to place grafts in these areas and also sinus lifts. These procedures usually take several months of healing and recovery. In addition, the costs incurred by the patients are too high. In addition, there are concerns with reports of infection or failure [1]. With the lack of teeth in the maxilla (upper jaw), tendency for the bone internal to the ridge to resorb over time increases. The increased porosity makes such bone unsuitable for implant placement without graft placement. Although the ridge may look sufficient from the outer surface, a radiographic investigation shows a total lack of bone density. Many times even repeated attempts at bone grafting proves unsuccessful [2,3]. Subperiosteal implants can be of tremendous help in such cases. The reduction of bone height in maxillary posterior region poses a serious challenge for implant placement. Whereas, in the mandibular region compromised bone dimensions while placement of endosseous implant may lead to injury to the neurovascular bundle. Taking this into consideration we have used a hybrid implant system instead of endosseous implant in our case to overcome the concept of ridge augmentation with bone grafting for implant supported prosthetic rehabilitation of maxillary posterior region.

## II. Case Report

A 27 yr old working male patient reported to the division of Periodontology with chief complaint of missing upper posterior tooth since one and half years. He had a missing 26 with adequate bone height and reduced residual bone width (*Fig 1*). His medical history was not of relevance and he had not visited a dentist since his extraction was carried out. Oral prophylaxis was done and a diagnostic CBCT to estimate his bone height and width and the level of maxillary sinus floor was carried out. The CBCT revealed his residual bone height of 17.9mm and residual bone width of 3.4mm (*Fig 2a & Fig 2b*). The patient's informed consent was taken and surgery was planned. All surgical procedures were carried out under local anaesthesia with strict sterilization protocols.

## III. Implant Design and Surgical Procedure

A Hybrid implant consists of a long malleable plate having a length of 30-45 mm, thickness of 0.4-1 mm and width of 3-5 mm with screw holes and a stump called the abutment. The implant has a vestibular anchoring part with at least three screw holes and a lingual or palate anchoring part with at least two screw holes for fixing at the most appropriate area of the jaw bone by means of screws (*Fig 3*). Two arms on either side of the abutment are of variable length. However number of holes on the plate and the diameter and length of the abutment are also variable and is in the range of 1.5-7 mm diameter with 4-8 mm length. The length of abutment can be cut to size as required. These variations are decided according to the site of placement. The elongated laminar plate, abutment and screws are made of titanium. Screws of diameter 2 mm and length 6mm are commonly used.

Under local anesthesia crevicular incision was given continued with a crestal incision followed by a vertical release incision in the edentulous region of the maxilla. A mucoperiosteal flap is elevated and the alveolar bone is exposed. After reflection of the mucoperiosteal flap the implant blade was molded according to the ridge shape and fixed using titanium screws on both buccal and palatal cortices in such a way that the abutment was projecting occlusally in the oral cavity (*Fig 4*). Out of the three screw holes in vestibular region two holes were used for anchoring and one screw hole was on the palatal side. Xenograft of particulate type was

placed over the plates that were anchored on the bone using 6mm screws. PerioCol membrane was placed to stimulate Guided Bone Regeneration (Fig 5). Primary closure was achieved such that the abutment remained exposed. The closure was done with 3-0 silk suture. A periodontal pack was placed and antibiotic prophylaxis with NSAIDs was prescribed. Patient was reviewed on the 10<sup>th</sup> day for removal of pack and sutures. He was subsequently re-evaluated on the 30<sup>th</sup> day. The healing at the surgical site was satisfactory and the implant integration appeared stable (Fig 6). A permanent restoration with ceramic crown was provided after 5 months. The patient is under regular re-evaluation.

#### IV. Discussion

The concept of osseointegration proposed by Branemark *et al.* [4, 5] and the replacement of lost teeth by implants have revolutionized restorative prosthetic dentistry. There have been four main types of dental implant designs that were developed and used in clinical dentistry, such as subperiosteal form, blade form, ramus frame, and endosseous form. The major drawbacks of the endosseous implant were:

- (1) The width of the bone in the bucco-lingual direction is crucial as more than 1 mm of bone should be around the endosteal implant [6].
- (2) The length of the root form implant is often above 8 mm and any reduction in this length due to inadequate bone height calls for the increase in the diameter of the implant to achieve adequate bone implant interface.
- (3) Risk of involvement of neurovascular bundle in the mandible in reduced bone height is a reality. A minimum distance of 2 mm has to be maintained to avoid nerve injury [7]
- (4) In the sinus area of the maxilla, the vertical thickness of the bone is often less than 5 mm [8].

Subperiosteal implants have been around since the early 1940s. In 1937 Gustav Dahl proposed the original subperiosteal implant concept and design along with the insertion protocol. It was brought to the United States by Dr. Aaron Gershkoff and Dr. Norman Goldberg. These implants were made of a lightweight and inorganic metal that was biocompatible. The early material was Vitallium, a cobalt chrome alloy that is completely inert in human tissue. The subperiosteal implant was designed to rest on the crestal bone and beneath the periosteum. The design based on concept of distribution of stress from the prosthesis to large areas of supporting bone. The reattached mucoperiosteum provided the retention and it would stabilize the infrastructure casting. By definition, a subperiosteal implant is a framework specifically fabricated to fit the supporting areas of the mandible or maxilla with permucosal extensions for support and attachment of prosthesis [9]. The optimal outcome of subperiosteal implant therapy is represented by the long-term material of Bodine and Yanase whose 10-year report indicated success in the range of  $66 \pm 8\%$ .

Through the years, many clinicians have modified this design. However, in 2014 Varghese Mani *et al.* [10] introduced Hybrid implant a novel implant system which can handle atrophic maxilla without sinus lift and grafting procedures, and mandibular edentulous areas with minimal nerve injury. These are close to a normal teeth and research is being carried out to fine tune them to replicate more of the anatomical structure in order to make them more biocompatible and functionally stable. These implant showed good stability with minimum postoperative complication as it is placed subperiosteally onto the bone. The proximity to anatomic structure is not of serious concern as the screws are fixed subperiosteally far away from any predictable anatomical entity.

Conventional implant placement in compromised edentulous ridges requires a complex array of armamentarium and is not economical. The osteotomy required to place a conventional system is technique sensitive which affects subsequent prosthetic rehabilitation. In case of hybrid implant the osteotomy involves single drills with various points of fixation. Second stage surgery and making impressions with a coping that replicates the abutment is a cumbersome technique specific procedure for the clinician in conventional endosseous implants. In Hybrid implant systems the abutment is already projecting in the oral cavity which eventually serves for immediate prosthetic rehabilitation.

Hybrid implant is designed to overcome the limitations of the root form implants taking the advantage of malleability of titanium alloys and firm support from the basal bone of the jaws.

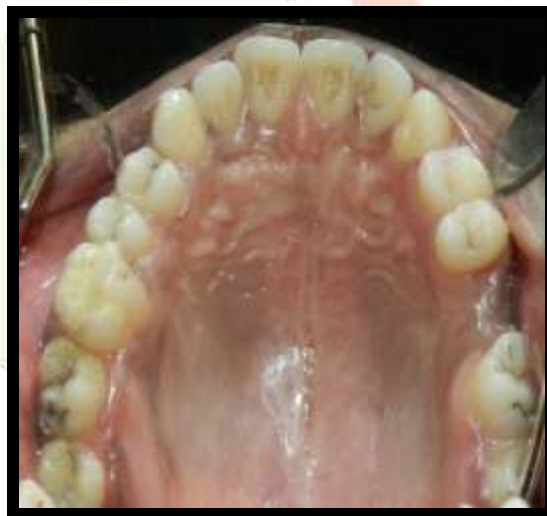#### V. Conclusion

Hybrid implant system is an effective system for the rehabilitation of edentulous spaces with inadequate bone for endosseous implant placement, and also cost effective and patient friendly [11]. This implant system is economical, technically less sensitive, requiring minimum armamentarium for implant placement. This new implant system has opened up new prospects in the field of prosthetic rehabilitation. Since its inception and proposed patent application [10], several implantologists have utilized this system to rehabilitate missing teeth. Further research into the applicability of this implant system and probability of immediate loading under full functional capacity can be studied in a clinical setup.

#### VI. References

- [1] Placement of a Modified Subperiosteal Implant: A Clinical Solution to Help Those with No Bone Authored by Ara Nazarian, DDS Dentistry today Vol 33 No 7 Page 134.

- [2] Barrero C, Border MB, Bencharit S. Fabrication of a maxillary implant retained over denture using an existing subperiosteal implant: A clinical report. *Open Dent J* 2011; 5:122-5.
- [3] Misch CE, Abbas HA. *Contemporary Implant Dentistry*. 3rd ed. Netherlands: Elsevier Health Sciences; 2008. p. 839-69.
- [4] Branemark PI, Adell R, Breine U *et al.* Intra-osseous anchorage of dental prostheses. I. Experimental studies. *Scand J Plast Reconstr Surg*. 1969; 3(2):81-100.
- [5] Adell R, Lekholm U, Rockler B *et al.* A 15-year study of osseointegrated implants in the treatment of the edentulous jaw. *Int J Oral Surg*. 1981; 10(6):387-416.
- [6] Belser UC, Bernard JP, Buser D (1996) Implant-supported restorations in the anterior region: prosthetic considerations. *Pract Periodontics Aesthet Dent* 8:875–883
- [7] Shenoy VK (2012) Single tooth implants: Pretreatment considerations and pretreatment evaluation. *J Interdiscip Dent* 2(3):149–157
- [8] Nimigean V, Nimigean VR, Maru N, Salavastru DI, Badita D, Tuculina MJ (2008) The maxillary sinus floor in the oral implantology. *Rom J Morphol Embryol* 49(4):485–489
- [9] Singh P. *The forgotten implant: Subperiosteal*. Vol. 4. New York, USA: Implant Tribune; 2009. p. 1-7.
- [10] Varghese Mani *et al.* Hybrid Implant: A Novel Implant System *J. Maxillofac. Oral Surg*. 2014. 12663-014-0722-9
- [11] Prosthetic rehabilitation with hybrid implants – A case report Dr. Gaurav Mittal, Dr. Anmol Agrawal, Dr. Ritesh Garg, Dr. Abhishek Rathi and Dr. Dipika Raghaw *International Journal of Applied Dental Sciences* 2017; 3(3): 109-112



**Fig 1. Pretreatment photograph showing missing 26**

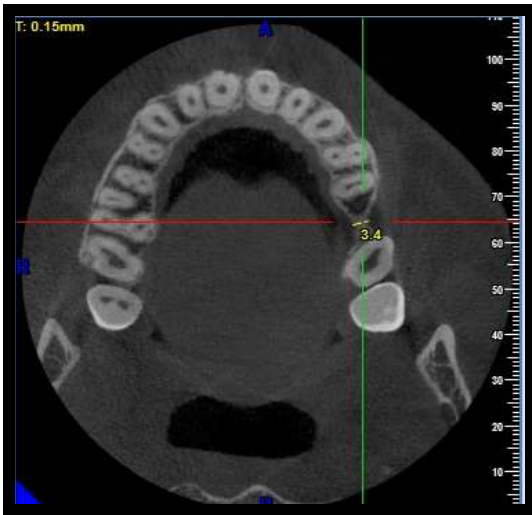


Fig 2a. Pretreatment CBCT showing residual bone width of 3.4mm

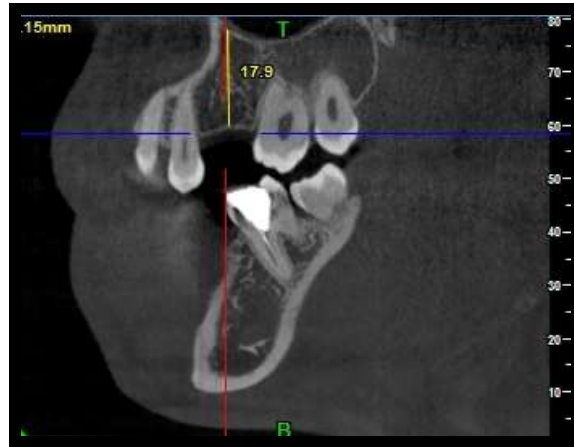

Fig 2b. Pretreatment CBCT showing bone height of 17.9mm




Fig 3. Hybrid Implant with abutment diameter of 3.5mm

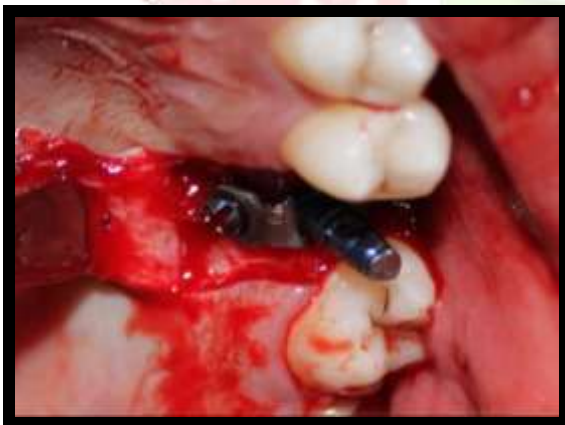

Fig 4. Hybrid implant secured with 6mm screw and abutment projecting into the oral cavity

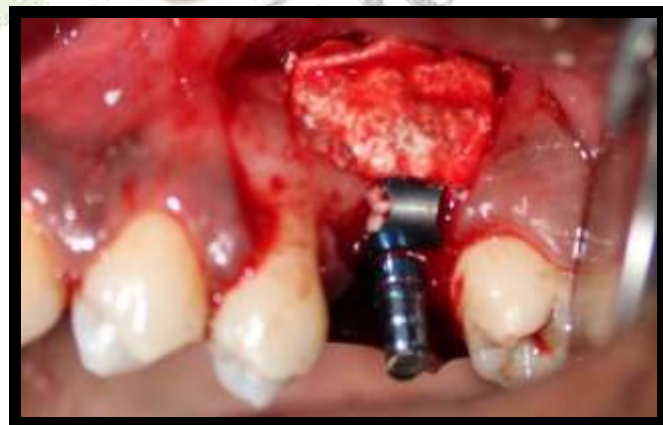
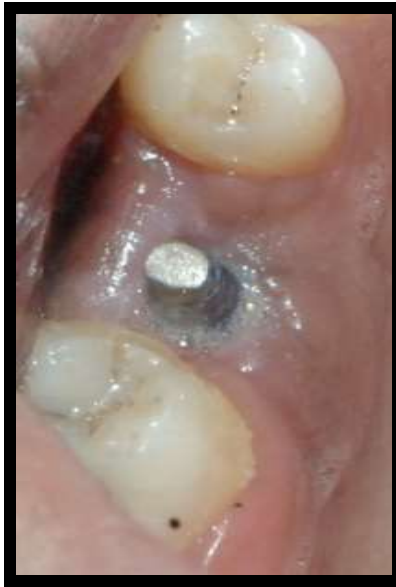
Fig 5. Guided Bone Regeneration with particulate bone graft and PerioCol Membrane



**Fig 6. 30 days post operative showing satisfactory wound healing**

