

Ayurvedic Management Of Pleural Effusion W.S.R To *Urahstoya* A Case Report

1Dr ShivaPrasad Sharma, 2Dr Kiran Kumar Mutnali

1 Assistant Professor & Consultant, Department of Kayachikitsa CVM University's GJ Patel Ayurveda College, Research Centre & SJ Patel Ayurveda Hospital & Maternity Home, Anand, Gujarat.

2 Professor & Consultant, Department of Kayachikitsa, Dr NA Magadum Ayurveda Medical College, Ankali, Karnataka.

Abstract:

Pleural cavity is filled with minimal amount of fluid sufficient enough to facilitate the free expansion of the lungs. Pleural effusion is a condition where excess of fluid gets accumulated within the pleural cavity resulting in breathlessness, pleuritic chest pain and dry cough. The precise description of this condition although available in later period lexicons of Ayurveda, the above presentation of clinical features is found in multiple conditions like *Shwasa* (breathing ailments),

Parshwashoola (Flank pain), *Kasa* (Cough), *Sosha* (Pulmonary Tuberculosis) etc. *Bhaishajya Ratnavali*, documents the condition named *Urahstoya* which exactly correlates to pleural effusion. A female case of 58 years reported to outpatient dept was diagnosed with *Urahstoya* (pleural effusion) and managed by a *Shodhana* (detoxification) procedure called *Nitya Virechana* (Gut cleansing on daily basis). Simultaneously patient was subjected to *Vatanulomana* (facilitating movement of *Vata Dosha* in its natural direction), *Kapha* pacifying, *Mutrala* (diuresis), *Vishaghna* (anti poisonous) and *Jwaraghna* (antipyretic) medicaments. The patient showed steady improvement over five months of active treatment i.e., from 9th April to 31st August 2018, which was consistent and complete with no relapse during follow up till 11th January 2019.

Key-words: *Nitya Virechana*, Pleural effusion, *Shodhana*, *Shwasa*, *Urahstoya*.

Key Messages: Ayurvedic herbo-mineral medicines showed promising result in the management of Pleural Effusion specially improvement in the symptoms like reduction in pleuritic chest pain, dyspnea and Cough. Ayurveda treatments can be successfully adopted in mild to moderate cases with no marked debility, without having to subject the patient for invasive procedures like thoracentesis.

INTRODUCTION

The anatomical architecture of human lung provides minimal amount of free fluid in the pleural space i.e., 10 to 20 ml¹, which helps in smooth expansion of lungs to preventing friction. Excess fluid hinders lung expansion resulting in dyspnea, cough and pleuritic chest pain during breathing limiting the execution of routine activities.² The accumulated fluid can be either transudative or exudative based on the underlying aetiology³. Intervention is therefore essential to eliminate the excess fluid and minimize the discomfort. Thoracocentesis is the mainstay of treatment in contemporary science and is quite effective as well. However, it comes with risks and complications.⁴ In *Ayurveda*, these symptoms are documented under the condition *Urahstoya*.⁵

The condition basically involves all three *Dosha* in its pathology with derangement in *Vata* and *Kapha* at initial phase. *Urahstoya* is characterized by excess accumulation of *Ambu* (serous fluid) in *Shleshmadhara Kala* (pleural cavity) of *Phupphusa* (lungs) one among *Kosthanga*⁶ (body cavities). *Ayurveda* recommends the treatment principles of *Mutrakrichra* (dysuria), *Hridroga* (cardiac ailments), *Shwasa* (breathing ailments), *Kasa* (cough), *Udara roga* (ascites) and *Shotha*⁷ (edema) in the management with medications possessing *Kapha Vata* pacifying and *Mutrala*⁸ (diuresis). *Ayurvedic* management promises good outcome without subjecting the patient to the risk of interventional procedures like thoracocentesis in uncomplicated cases.

PATIENT INFORMATION

A 58 year old female patient, non-diabetic but a known case of bronchial asthma since eight years and hypertension since one year approached to the PRANADA OPD of KLE Ayurveda Hospital on 9th April 2018 with chief complaints of breathlessness (ATS- American thoracic Society Scale – Grade 3 – Stops for breath after walking about hundred yards or after a few minutes on level)⁹, chest pain (VAS-Visual Analogue Scale 6)¹⁰, dry cough (VAS 6)¹¹ and coryza since last 8 days associated with pain in left shoulder radiating to left arm with tingling sensation, disturbed sleep and low backache. She has complained of inability to lie in supine position. The above complaints were insidious and gradually progressive in nature, aggravated by physical exertion and relieved by lying in left lateral position. On deep inspiration, the patient was experienced stabbing type of pain in the left side of the chest. There was associated generalized body weakness.

CLINICAL FINDINGS & DIAGNOSTIC ASSESSMENT:

The general physical examination of the patient was within normal limits with the vitals viz., temperature, pulse and respiratory rate in normal range and the blood pressure was well controlled. Inspection of the chest showed reduced expansion on the left side and apex beat was not remarkable. On palpation the chest movements, tactile vocal fremitus were reduced. Percussion revealed stony dull-note and auscultation confirmed absence of air entry in left middle and lower lung fields with no adventitious sounds. Details of examination findings at different time points have been summarized in Table No 2. The right lung and other systems were within the normal. A diagnosis of left sided pleural effusion was made based on the history, X ray and clinical examination.

Patient was followed up over 8th, 15th, 32nd, 39th, 50th, 60th, 95th, 119th and 144th day. She was called for first follow up on 8th day of intervention to ascertain the efficacy of treatment¹² and consider referring to higher centre in case there was no relief. During follow-up when improvement was noted, she was called for second follow-up on 15th day.

Assessment was based on history of Dyspnoea (Grading of ATS), cough, chest pain (VAS) and concurrent clinical assessment of respiratory system. Radiological assessment was done prior and post completion of intervention.

Diagnosis: *Urahstoya* (Left side pleural effusion involving the middle and lower lobes)

TIMELINE

Eight days prior to the onset of current symptoms, the patient had high grade fever, productive cough and ATS Grade 2 breathlessness. A provisional diagnosis of pneumonia was made by a local Homeopathic physician who advised Tab Cefuroxime 250 mg twice in a day and Tablet Montelukast sodium once daily after food, Tablet Pantozol-DSR one two times a day before food for five days. Owing to her incomplete relief she approached our hospital for further evaluation and management. The routine blood investigations revealed no derangement except that the Erythrocyte Sedimentation Rate was 70mm at the end of one hour and Total Leukocytes count (TLC) was 11,600cells/mm³. Chest X-ray of the patient in Posteroanterior (PA) view confirmed left sided moderate pleural effusion with underlying collapse/consolidation. From last eight

years patient is using inhaler Beclomethasone and Salbutamol once daily. Patient is on Tablet Amlodipine Besylate and Atenolol 50mg once daily since one year for management of hypertension. The history and clinical examination is consistent with presentation of post-pneumonic pleural effusion. Case reporting is done as per CARE (Case Report) case report guidelines.(<http://www.care-statement.org>)

THERAPEUTIC INTERVENTION:

The approach towards management in this case was on the principles of *Udara Roga and Shwasa roga* wherein the herbs with property of diuresis, *Vatanulomana* (facilitating movement of *Vata Dosha* in its natural direction), *Kapha Vata* pacifying when given orally in the present case over a period of five months, the result was encouraging. (Table No.1) The patient was treated with *Nitya Virechana* (NV), *Lepa*, *Shamana Aushadhi* (oral medications) with due consideration to her *Kaphapittala Prakruti* (constitution) and *Kapha Vata Dosha* dominance in the pathogenesis of the pleural effusion (PE). Various timelines and details of treatment with chronological intervention, medicines used, dosage, duration and outcome have been mentioned in [Table No. 4]

Lepa is a procedure in which herbs are made into fine powders and mixed homogenously in warm water to attain a fine paste. This warm paste was applied once daily to the left side of the chest, back and flank. The paste was kept for thirty minutes and washed off after drying with lukewarm water.

FOLLOW-UP & OUTCOME:

Patient was treated from April to December 2018. Active intervention for PE was administered till August 2018 (144 days). Follow-up of the patient was continued till her last visit in January 2019 for other complaints like *Sandhigata Vata* (osteoarthritis of knee joints) and *Gridhrasi* (sciatica).

The outcome on respiratory system findings like air entry on auscultation exhibited steady improvement over follow ups. Clinical assessment parameters like breathlessness, cough and chest pain exhibited gradual recovery from baseline score of 3 (Dyspnea), 6 (Cough) and 6 (VAS) to 1 (Dyspnea), 2 (cough) and 4 (VAS) on 32nd day and near to complete recovery by 144 days. Orthopnoea subsided on 15th day. On 8th and 15th day visit patient complained of loss of appetite, heart burn, sour eructation and nausea. Accordingly diagnosis of *Urdhwaga Amlapitta* was done and was treated with Tab *Pravala Panchamrita* 125gm twice a day and *Madiphala Rasayana*¹³ 3 teaspoonful twice a day before food. During this visit medications to improve *Agni*

and alleviate *Ama* were added. At follow-up, ESR on 4 August 2018 was 16mm at the end of one hour and x ray chest showed 80% reduction in effusion. The effusion reduced completely on 4 December as evidenced by chest x-ray. Chronological improvement has been summed up in Table No. 4&5.

DISCUSSION:

Urahstoya is a *Pranavaha srotas* (respiratory system) disease with dominance of *Vata* and *Kapha Dosha* where in there is fluid accumulation within the pleural space. The condition develops as a result of vitiation of *Vata Dosha* exciting the *Pitta* and *Kapha Dosha* and further vitiating them. Thus vitiated *Vata-Pitta-Kapha Dosha* disturbs the *Rasa* (Plasma and Nutrient Fluid) , *Rakta Dhatu* (~blood & its components) producing *Shleshaka Kapha Dusti* in *Urah* (thoracic cavity) which is followed by the accumulation of the fluid in *Shleshmadhara Kala*¹⁴. The patient under study had ATS Grade 3 breathlessness, chest pain of VAS 6 and cough of VAS score 6 before initiation of treatment. Ensuring that her life was not at stake, an individualized diligent treatment plan was made and initiated. Observations and findings were noted during regular follow-ups. Treatment was based on the principles of *Shwasa*, *Udara Roga* and *Shotha*. *Nitya Virechana*¹⁵ (Gut cleansing on daily basis), *Lepa* (topical application) with oral medications were administered for five months. NV was administered with ten grams of *Haritaki* (*Terminalia chebula Linn.*) powder for 32 days on daily basis in order to achieve elimination of fluid by inducing bowel movement and the average number of *Vegas* attained were three. NV also acts as diuretic, rectifies the diminished appetite.¹⁶ Oral medications were targeted at normalizing *Vata*, *Kapha Dosha* and maintenance of digestion to prevent *Ama* formation.

At first visit patient was advised Tab. *Lakshmi Vilasa Rasa* (*Naradeeya*) [LVRN] 250mg one tablet twice a day post meal, Tab *Suvarnamalini Vasanta Rasa* [SMVR] 125mg one tablet twice a day post meal, Syrup *Pushkaramruth* 15 ml twice a day with 30ml warm water and combination of *Talisadi Churna* (TC) 100 gms and *Rasasindhoo*¹⁷ 2.5 gm in a dose of six gram thrice a day post meal.¹⁸ LVRN¹⁹ is highly effective in cold, cough and dyspnea. Ingredients like *Krishna Abhraka Bhasma* (incinerated Mica), *Shuddha Gandhaka* (processed Sulphur), *Karpoora*²⁰ (*Cinnamomum camphora. (L.) J. Presl.*), *Vridhdhadaru*²¹ (*Argyreia nervosa. (Burm.f.) Bojer.*), *Nagabala*²² (*Sida Veronicaefolia Lam.*), *Atibala*²³ (*Abutilon Indicum (Linn.)*); act as *Rasayana*, antimicrobial and antipyretic. SMVR is a herbo-mineral formulation, indicated primarily in chronic fever, cough, asthma and tuberculosis. Ingredients like *Suvarna Bhasma*²⁴, *Mukta Bhasma*²⁵, *Kajjali*, *Ayas*,

and *Tamra Bhasma* enhance immunity. It balances *Vata & Kapha Dosha*. *Syp. Pushkaramruth*²⁶ a proprietary medicine of Swadeshi Pharmaceuticals Pvt.Ltd is indicated in bronchial asthma, bronchitis, cough and cold. The ingredients *Pushkaramoola*, *Vasa*, *Trikatu*, *Yasthimadhu*, and *Bharangi* are potent bronchodilators, antispasmodic and decongestants. ²⁷TC was administered to relieve cough, breathlessness and induce expectoration, enhance digestion and is *Moodha Vata Anulomana. Haritaki Churna* 5gm followed by 10gm with warm water was administered to cleanse the accumulated *dosha* as a NV medicine. *Haritaki* is *Vata Anulomaka*; regulation of movement of *Vayu* cures *Shwasa & Kasa*. During follow-ups when patient complained of generalized weakness, *TC* was added with *Shataputi Abhraka Bhasma* one gram and *Sitopaladi churna* in equal quantity and *Swamla Compound*²⁸ a proprietary medicine of Shri Dhootapapeshwar Ltd. for inducing *Bala* and mitigation of aggravated *Vata Dosha*. *Devadaru* (*Cedrus deodara Roxb*),²⁹ *Daruharidra* (*Barberis aristata*), *Haridra* (*Curcuma longa Linn*), *Vacha* (*Acrous calamus Linn*), *Triphala* (*Emblia officinalis Gaertn*, *Terminalia bellirica Roxb*, *Terminalia chebula Retz*) *Ashwagandha* (*Withania somnifera Dunal*), *Rasna* (*Pluchea lanceolata Oliver & Hiern*) *Churna* was advised for *Lepa* to left lung area, back and lateral aspects for reducing pain and *soshana* (dries up) of accumulated *Ambu*. *Devadaru* mitigates provoked *Vata*, *Kapha* and is indicated in cough, asthma. *Devadaru* and *Haridra* being *Ushna Veerya* help in *Soshana* of *Ambu* accumulated and are *Shothaghna* (anti-inflammatory). Overall, the management was *Vata and Kapha* mitigating targeting the primary *doshas* involved in pathology.

The above treatment protocol was adopted and encouraging outcome was found at each visit of with no adverse effects. Four months and 24 days of follow up and observation demonstrated sustained amelioration of all the symptoms at each visit by around 20 to 30% on ATS Scale (American Thoracic Society) for Dyspnoea and VAS (Visual Analogue Scale) for pain in flank. The line of management adopted was safe alternative to conventional thoracocentesis in this case. Ayurvedic treatment is effective and safe in patients of Pleural effusion matching the above case.

CONCLUSION

The treatment principles of *Shwasa*, *Udara*, *Shotha* and *Kasa* diseases showed efficacy in eliminating the accumulated fluid and simultaneous correction of abnormality in *Dosha*, *Dhatu* and maintaining *Agni* with oral medications has been helped to restore the normalcy of *Pranavaha srotas*. Intersecting the paradigm of conventional pleural effusion treatment, Ayurvedic management exhibited significant effect in the current case with treatment span consisting 32 days of *NV*, 144 days of oral medications that resulted in complete remission. The above discussed case is a fine illustration of how PE with no significant debilitation can be fruitfully managed with Ayurveda.

Patient Informed Consent: Patient gave consent for the Publication of Article.

Source of funding: None

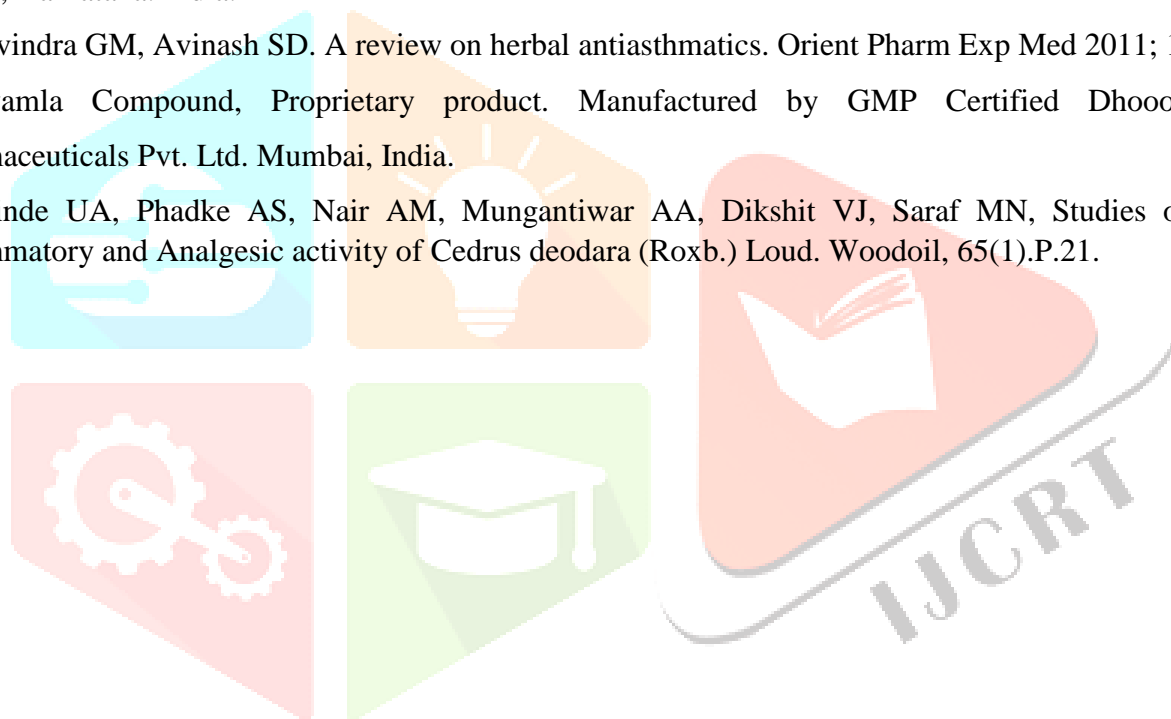
Conflict of Interest : None

REFERENCES

1. Richard W. Light ,Anthony S fauci, Eugene braunwald, dennis, Dennis L.Kasper, Stephen L. Hauser, Dan L. Longo, J.Larry jameson, Joseph Loscalzo ; Harrison's principles of internal medicine: 17th edition ;p 1658.
2. Ralston SH, Penman ID, Strachan MWJ, Hobson RP. Respiratory Medicine In: Reid PT, Innes JA , editor. Davidson's Principles and Practice of Medicine. 23rd International edition. Ch.17.New York: ELSEVIER, 2018.p.562
3. Fauci AS, Braunwald E, Kasper DL, Hauser SL, Longo DL, Jameson JL , Loscalzo J. Disorders of Pleura and Mediastinum In: Light RW, editor. Harrison's Principles of Internal Medicine. 17th International edition. Ch. 257, Vol. II. New Delhi: Mc Graw Hill, Medical Publishing Division; 2008. p.1659.
4. Michael G. Seneff, M.D. R. William Corwin, M.D. Louis H. Gold, M.D. Richard S. Irwin,M.D.,F.C.C.P. Complications of Thoracocentesis: CHEST Journal , VOLUME 90, ISSUE 1, P97-100, JULY 01, 1986.
5. Shastri AD, commentator. Bhaishajya Ratnavali of Govinda Das Sen, Ch.80.2nd ed. Varanasi: Chaukambha Sanskrit Samsthan;2004. p.806.
6. Acharya YT, editor. Susruta Samhitha of Susruta, Chikitsa Sthana, Ch.2, Ver.12-13.8th ed. Varansi: Chaukambha Orientalia; 2005. p. 409.
7. Shastri AD. Bhaishajya Ratnavali of Govinda Das Sen. Ch.80.2nd ed. Ver. 6. Varanasi: Chaukambha Sanskrit Samsthan; 2004. p. 806

8. Shastri AD. Bhaishajya Ratnavali of Govinda Das Sen. Ch.80.2nd ed.Ver.1. Varanasi: Chaukambha Sanskrit Samsthan; 2004. p.806.
9. SP Mehta, SR Joshi ,Nihar P Mehta P.J.Mehta. Respiratory system In,Practical medicine. 18th edition ,ch.4.Mumbai:NBD Publishers,2008, P.111.
10. Paula Kersten, Peter White, Alan Tennant: Is the Pain Visual Analogue Scale Linear and Responsive to Change? An Exploration Using Rasch Analysis, PLoS ONE 9(6), June 2014
11. SpinouA,Birring SS. An update on measurement and monitoring of cough.what are the important study endpoints? J Thorac Disease 2014;6(s7):S728-S734.
12. Acharya YT, editor. Susruta Samhita of Susruta, sutrasthana, 8thed, Ch.35, Ver.49. Varanasi: Chaukhambha Orientalia ; 2005. p.158.
13. Aptilift, Proprietary product. Manufactured by GMP Certified SANDU Pharmaceuticals Pvt. Ltd. Marra, Bardez, Goa.
14. Acharya YT, editor. Susruta Samhita of Susruta, Uttara Tantra, Ch.42, Ver. 111. 8th ed. Varanasi: Chaukhambha Orientalia; 2005.p.725.
15. Acharya YT, editor. Charaka Samhita of Agnivesa, Chikitsasthana .Ch.13, Ver. 61. Reprint ed. Varanasi: Chaukhambha Orientalia; 2011 edition. p.495.
16. Acharya YT, editor. Charaka Samhita of Agnivesa, Chikitsasthana .Ch.13, Ver. 61. Reprint ed. Varanasi: Chaukhambha Orientalia; 2011 edition. p.495.
17. Sitarm Sitarm B, commentator. Bhavaprakasha Nighantu of Bhavamishra, Ch.6, Hareetakyadi Varga, Vol.01, Ver.19. Varanasi: Chaukambha Orientalia. p.132.
18. Acharya YT, editor. Charaka Samhita of Agnivesa, Chikitsasthana .Ch.13, Ver. 61. Reprint ed. Varanasi: Chaukhambha Orientalia; 2011 edition. p.495.
19. Sitarm Sitarm B, commentator. Bhavaprakasha Nighantu of Bhavamishra, Ch.6, Hareetakyadi Varga, Vol.01, Ver.19. Varanasi: Chaukambha Orientalia. p.132.
20. Dwivedi V, Anandan EM, Mony RS, Muraleedharan TS, Valiathan MS, Mutsuddi M, et al. (2012) In Vivo Effects Of Traditional Ayurvedic Formulations in Drosophila melanogaster Model Relate with Therapeutic Applications. PLoS ONE 7(5): e37113. 2012.
21. Hariprannaji P , Rasayogasagara :Vol II, Commentary on Rasasindhura : ver.522-524. Varanasi: Chaukambha Kishandas Academy; p.25
22. Shastri AD commentator. Bhaishajya Ratnavali of Govinda Das Sen, Ch. 73 ver.81- 101. Varanasi: Chaukambha Sanskrit Samsthan; 2007 edition .p.1109
23. Wenting Wang , Dongxiang Li , Xiaoqin Huang , Huixiang Yang , Ziwen Qiu , Liting Zou, Qin Liang , Yu Shi , Yingxiang Wu , Shaohua Wu , Chao Yang ,and Yongyu Li . Study on Antibacterial and Quorum-Sensing Inhibition Activities of Cinnamomum camphora Leaf Essential Oil, 21 October 2019.
24. Subramoniam A, Madhavachandran V, Ravi K, Anju VS, Aphordisiac property ofthe elephant creeper Argyreia nervosa, Journal of Endocrinology and Reproduction, 2007; 11:5-19.

25. Philip BK, Muralidharan A, Natarajan B, Varadamurthy S, Venkataraman S. Preliminary evaluation of anti-pyretic and anti-ulcerogenic activities of *Sida cordifolia* methanolic extract. *Fitoterapia* 2008; 79: 229-31.
26. K. Radhakrishnan, A. Mohan, Shanmugavadivelu Chandra Mohan and S. Velavan,. A comparison of chemical composition, antioxidant and antimicrobial studies of *Abutilon indicum* leaves and seeds. 11(1) 11-19, 2017
27. A Mitra, S Chakraborty, B Auddy, P Tripathi, S Sen, A.V Saha, B Mukherjee. evaluation of chemical constituents and free radical scavenging activity of Swarnabhasma (gold ash), an Ayurvedic drug, *Journal of Ethnopharmacology*, 80: 147-153. 2020
28. B K Veena, P.G.Jadar Immunomodulatory Effects of Ayurvedic Drugs: A Review: 4(11), 2014.
28. Pushkaramruth, Proprietary product. Manufactured by GMP certified Swadeshi Pharmaceuticals Pvt. Ltd, Udupi, Karnataka. India.
29. Ravindra GM, Avinash SD. A review on herbal antiasthmatics. *Orient Pharm Exp Med* 2011; 11:77-90.
30. Swamla Compound, Proprietary product. Manufactured by GMP Certified Dhootapapeshwar Pharmaceuticals Pvt. Ltd. Mumbai, India.
31. Shinde UA, Phadke AS, Nair AM, Mungantiwar AA, Dikshit VJ, Saraf MN, Studies on the Anti-inflammatory and Analgesic activity of *Cedrus deodara* (Roxb.) Loud. *Woodoil*, 65(1).P.21.



**TABLE No. 1 ASSESMENT OF DYSPNEA ATS
(AMERICAN THORASIC SOCIETY)**

GRADE	DEGREE	DESCRIPTION
0	None	Not troubled by shortness of breath or levels or uphill.
1	Mild	Troubled by shortness of breath on level or up hills.
2	Moderate	Walks slower than persons of same age
3	Severe	Stops afterwalking100yards
4	Very severe	Breathlessness at rest

TABLE No. 2 GRADING OF COUGH FOR ASSESMENT (VAS) Visual Analogue Scale

GRADE	DESCRIPTION
0	No cough
1-3	Mild cough
4-6	Moderate cough
7-10	Severe cough

TABLE No.3 PAIN ASSESMENT -Visual Analogue Score(VAS)

GRADE	DESCRIPTION
0	No Pain
1-3	Mild Pain
4-6	Moderate Pain
7-10	Severe Pain

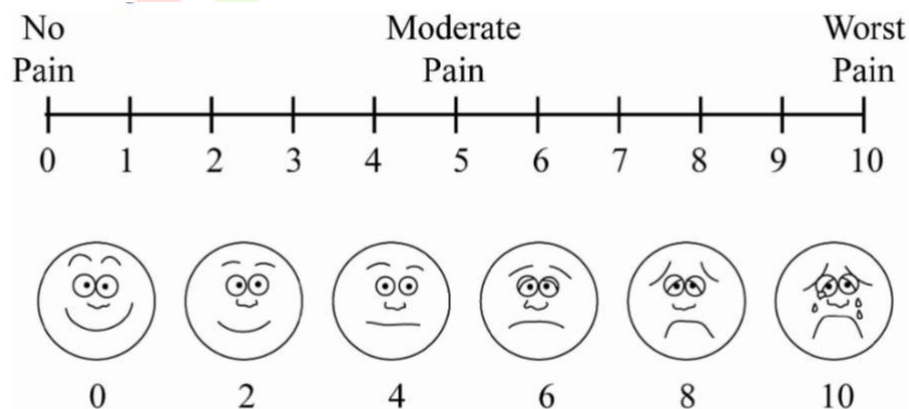


Figure No. 1

Table No 4 Pain Assessment - Visual Analogue Score(VAS)

GRADE	DESCRIPTION
0	No Pain
1-3	Mild Pain
4-6	Moderate Pain
7-10	Severe Pain

Table No. 3 Details of Therapeutic Interventions At Different Timelines

S.No	Duration of Intervention	Lakshana	Samprapti	Dosha vrudhi /kshaya avastha	Chikitsa (Shodhana & Shamana)
01	1 st to 32 nd day	Breathlessness Pleuritic chest pain Cough Coryza	Kapha vata	Kaphapitta samsrusta vatavrudhi	<ol style="list-style-type: none"> Nitya virechana with haritaki churna 10gm F/b 5gm with warm water at 7am Lepa (<i>Devadaru, Daruharidra, Haridra, Vacha, Triphala, Ashwagandha, Rasna</i>)
02	1 st to 144 day	Breathlessness Pleuritic chest pain Cough	Kapha vata	Kaphapitta samsrusta vatavrudhi	<p>Tab. <i>Lakshmi Vilasa Rasa</i> (<i>Naradeeya</i>) [LVRN] 250mg <i>Suvarnamalini Vasanta Rasa</i>[SMVR]125mg <i>Talisadi churna</i> (TC) with <i>Rasasindhura</i> (RS), TC with <i>sitopaladi churna</i>(SPC)and RS, TC with 100 <i>puti Abhraka bhasma</i> and RS <i>Pushkaramruth</i>(PA) <i>Madiphala rasayana</i>(MR), <i>Panchamrutha parpati</i>(PA), <i>Tab Dashamoola katutraya</i>[DKK], <i>Shwasa Kutara Rasa</i> [SKR], <i>Swamla Compound</i> [SC].</p>

Table 4 TIMELINE -Details of Therapeutic Interventions

S.NO	VISIT	INTERVENTION	OBSERVATIONS
1	Visit 1 (09-04-2018) 0 th day	1.Tab.LVRN 250mg, 1 TID/After food (AF) 2.Tab.SMVR, 125mg, 1 BD AF 3. Syp. Pushkaramruth 4TSF QID AF 4.TC- 100 gms + RS -2.5 gms - 6gm QID with Honey AF 5.Haritaki churna10gm with warm water on empty stomach 6.Devadaru + Daruharidra + Haridra + Vacha + Triphla + Ashwagandha + Rasna churna ⁷ Lepa with warm water to left flank & back Twice Daily	Orthopnoea Cough Chest pain Diminished Air entry in left lung in middle and lower lobe
2	Visit 2 (17-04-2018) 8 th day	1.Tab.LVR[N]) 1TID/AF 2.Tab. SMVR 1 BD AF 3.Syp. Pushkaramruth5 4TSF QID AF 4.TC50gm + SPC 50 gm + RS -2 gms 5.Haritaki churna 10gm with warm water on empty stomach 6.Devadaru + Daruharidra + Haridra + Vacha + Triphla + Ashwagandha + Rasna churna in equal quantity, Lepa with warm water to left flank & back Twice daily	Orthopnea Occasional Dry cough Exertional dyspnea Diminished Air entry in left lung in middle and lower lobe Loss of appetite
3	Visit3 (24-04-2018) 15 th day	Continued 1-6 medicines Added 1.Tab.Pravala Panchamrutha Ras [PAP] 1BD BF	Orthopnea subsided no dyspnea, no chest discomfort Diminished Air entry in left lung in middle and lower lobe
4	Visit 4 (11-05-2018) 32 nd day	1.Madiphala rasayana [MR] 2tsf TIDBF 2. Swamla compound [SC] 1tsf BD AF 3.Pushkaramoolasa 3tsf BD	No chest pain Diminished Air entry in left lung at base Appetite improved
5	Visit 5 (18-05-2018) 39 th day	1. TC 50gm +100puti AB + RS - 2gms 1tsf QID with Honey AF 2.Tab .DMKK 1TID AF 3.Pushkaramrith 3 TSF TID AF 4.Tab. SMVR 1BD AF	Diminished Air entry in left lung at base
6	Visit 6 (29-05-2018) 50 th day	1.PUSHKARAMRITH 3tsf TID AF Tab. DMKK 1TID AF Tab. SMVR 1TID AF	Diminished Air entry in left lung at base

7	Visit 7 (08-06-2018) 60 th day	1.PUSHKARAMRITH 3tsf TID AF Tab. DMKK 1TID AF Tab. SMVR 1TID AF	Diminished Air entry in left lung at base
8	Visit 8 (13-07-2018) 95 th	1.PUSHKARAMRITH 3tsf TID AF 2. Tab. DMKK 1TID AF 3.Tab. SKR 1BD AF 4.SC 1Tsf BD	Air entry improved in left lung X ray chest shows 80% resolution of effusion
9	Visit 9 (06-08-2018) 119 th day	1.Tab. R G Forte 1BD AF 2.Tab. Biogest 1BD AF PUSHKARAMRITH 3 TSF TID AF Tab. SMVR 1TID AF	No complains pertaining to respiratory system
10	Visit 10 (31-08-2018) 144 th day	1. Tab .DMKK 1TID AF 2.Shwasa Kuthara Ras 125mg, 1BD, AF 3.TC 50gm+RS 2gm+100puti AB 1tsf AF 4. Flexy Liniment E/A	No complains pertaining to respiratory system

Table 5 Assessment of Symptoms and Signs during different follow-up

S.No	Date	Dyspnea (ATS grade)	Cough (VAS)	Chest pain (VAS)	Air entry in left lung (diminished in)	Orthopn oea (Present/ Absent)	Anorexia (Present/ Absent)	Gener alized weakn ess
1	0 th day	3	6	6	Mild & lower lobe	Present	Absent	+++
2	8 th day	2	4	4	Mild & lower lobe	Present	Present	+++
3	15 th day	1	2	4	Mild & lower lobe	Absent	Present	+++
4	32 nd day	1	2	4	Lower lobe	Absent	Absent	++
5	39 th day	1	2	2	Lower lobe	Absent	Absent	++
6	50 th day	0	0	0	Lower lobe	Absent	Absent	+
7	60 th day	0	0	0	Lower lobe	Absent	Absent	+
8	95 th day	0	0	0	-	Absent	Absent	-
9	119 th day	0	0	0	-	Absent	Absent	-
10	144 th day	0	0	0	-	Absent	Absent	-

+ indicates severity of symptom, -:indicates absence of sign or symptom

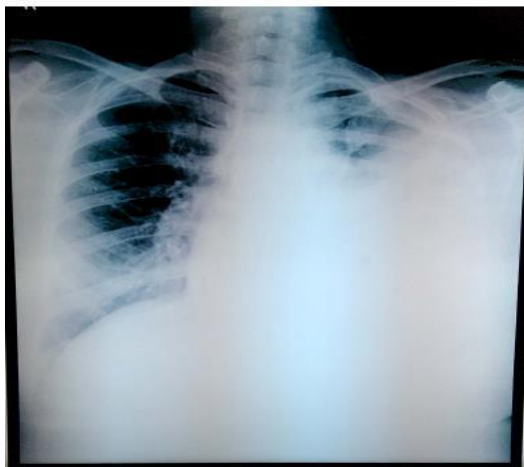

Fig 1. BEFORE TREATMENT(8/4/2018)
Impression: Left Moderate Pleural Effusion
With Underlying Collapse/Consolidation

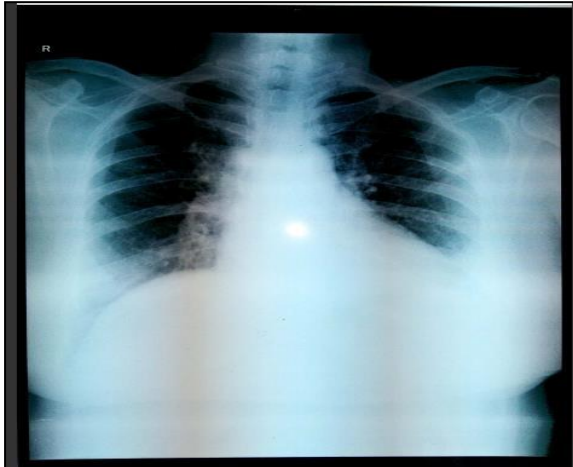


Fig 2. AFTER TREATMENT(4/8/2018)
Impression: Mild Blunting of Left CP Angle..?
Pleural Effusion or Pleural Thickening

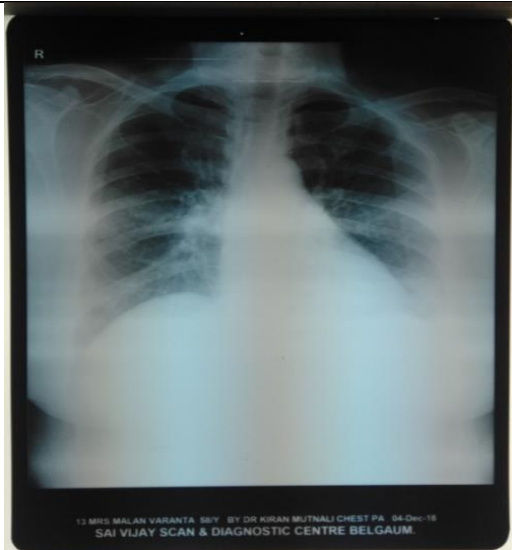

Fig 3.
Impression: Mild blunting of left CP angle
Pleural thickening dated 4/12/2018

