

ADAPTIVE METHODS FOR EARLY IDENTIFICATION OF GLAUCOMA FOR DIABETIC RETINOPATHY USING MATLAB GUI

B.Anupama(PHD)¹, Dr.Ramakrishna Seemakurti²

¹Research Scholar,

Electronics & Communication Engineering,
JJTU, RAJASTHAN, INDIA, 333001.

²Principal, Ph.D(Computer Science)

SVIT College, Secunderabad, INDIA, 500003

Abstract— Glaucoma is a neurodegenerative disorder of the optic nerve, which causes partial loss of vision. It is due to the increase in intra ocular pressure within the eyes. The retinal image diagnosis is an important methodology for diabetic retinopathy detection and analysis. The key image processing techniques to detect eye diseases include image registration, image fusion, image segmentation, feature extraction, image enhancement, morphology, pattern matching, image classification, analysis and statistical measurements.

Index Terms— Glaucoma, Funds Image, CDR, Diabetic Retinopathy, Image processing, image subtraction.

I. INTRODUCTION

Glaucoma is one of the major problems of modern ophthalmologic medicine. Currently, about 15-20% of patients with glaucoma, even with adequate treatment, are exposed to blindness. It is estimated by the person, but only half aware of this diagnosis, and an even smaller percentage receives adequate treatment [1]. At least 9 million glaucoma patients suffer from blindness in both eyes, and the number is steadily increasing. The number of patients suffering from glaucoma in the world is over 100 million.

Glaucoma is a multi-factorial disease in which, Primary open-angle glaucoma - a chronic eye disease characterized by an increase in the intraocular pressure (IOP) levels, damaging the optic nerve, causing a violation of the visual fields and leads to irreversible blindness if untreated quickly[2]. Early detection of glaucoma can limit the progression of disease.

The ratio of the size of the optic cup to the optic disc, also known as the cup-to-disc ratio (CDR), is one of the important clinical indicators of glaucoma, and is currently determined manually by trained ophthalmologists, limiting its potential in mass screening for early detection [3].

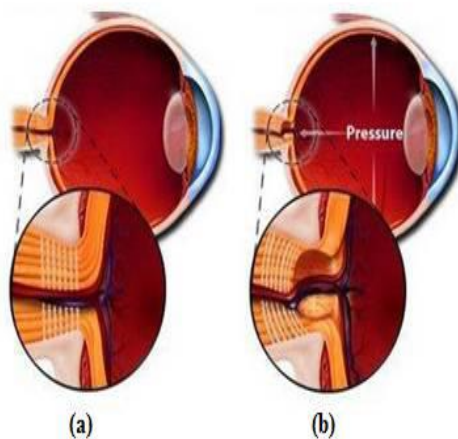


Figure 1: (a) Normal Eye (b) Glaucoma Eye

Primary glaucoma has three basic forms:

- Closure form
- Open form
- Mixed form

Closure form of glaucoma is characterized by a narrow or closed structure of the angle of the anterior chamber. The main link in the pathogenesis of primary angle-closure glaucoma is an indoor unit drainage system of the eye, which is blockage of the anterior chamber angle of the iris root. Open-form of glaucoma, as the name implies, it has an open profile or a wide angle of the anterior chamber and the free access of aqueous humor drainage to the area. The main resistance to outflow is directly in the most profound ways of outflow - trabeculae, scleral sinus, and collector channels intrascleral plexus.

Mixed form of glaucoma combines a narrow structure of the anterior chamber angle (liquid difficulty of access to the drainage system of the eye) and the deterioration of the permeability for ocular moisture filtration zone. In addition to primary glaucoma significantly rarer congenital, vascular, hypersecretory, low and high pressure form of secondary glaucoma. Clinically, the diagnosis of Glaucoma can be done through measurement of CDR. It is defined as the ratio of the vertical height of the optic cup to the vertical height of the optic disc. A CDR value that is greater than 0.65 indicates the high glaucoma risk [4].

II. RELATED WORK

Several studies are reported in the literature for the detection of optic disc and the classification of glaucoma disease. Walter and Klein [5] have proposed a method based on the morphological operation; applying the watershed transformation to the gradient image [6]. Another method is an active shape model, which consists of building a model with training cases and iteratively matching the landmark points on the disc edges and main vessels inside the disc [7].

Next method investigated for the determination of optic disc regions is based on the active contour modelling. In this method, expected disc borders have been searched in radial directions from the centre of an ROI. In another approach by Gopal Datt Joshi [8], region based active contour method has been used which avoided intensity variations due to vessels. However the cup deformation shall not be uniform due to variations in vessels.

In this study, we propose a method namely anisotropic diffusion filtering as a pre-processing step. The bright speckles distributed over the images are reduced without losing important information about disc and cup boundaries by using anisotropic diffusion filtering [9],[10]. Three methods are used to automatically extract the optic disc, 1) Edge detection method [11],[12], 2) Optimal thresholding method[13] and 3) Manual threshold analysis[14]. Cup is extracted using Threshold level-set method [15]. Later an ellipse fitting is applied to smooth and regulate the shape of segmented disc and cup boundary. Area of the disc and cup is found by finding number of white pixels in the results obtained from above methods. With the help of detected area, the cup to disc ratio (CDR) is calculated to suspect the glaucoma. Finally clinical CDR is compared with the proposed methods[16].

III. PAPER PROPOSED SYSTEM

Here we propose a method for the detection of glaucoma using fundus image which mainly affects the optic disc by increasing the cup size is proposed. The ratio of the optic cup to disc (CDR) in retinal fundus images is one of the primary physiological parameter for the diagnosis of glaucoma. The K-means clustering technique is recursively applied to extract the optic disc and optic cup region and an elliptical fitting technique is applied to find the CDR values.

The blood vessels in the optic disc region are detected by using local entropy thresholding approach. The ratio of area of blood vessels in the inferior superior side to area of blood vessels in the nasal-temporal side is combined with the CDR for the classification of fundus image as normal or glaucoma by using K-Nearest neighbour, Support Vector Machine and Bayes classifier [17]. The proposed system mainly consists of three different stages. They are Region of Interest (ROI) Extraction, Feature extraction stage and classification stage. Firstly, optic disk needs to be segmented.

After image acquisition, pre-processing is done by applying thresholding, illumination and histogram equalization. The optic disk and cup is segmented using various techniques like Hough transform, k-means clustering, active contour method, matched filter approach, vessel bends and morphological operations. Then CDR is calculated and classification is done for deciding whether condition of eye is normal or glaucomatous.

Localizing The Roi (Region Of Interest)

In order to extract the optic disc and cup, a region of interest around the optic cup and disc must first be delineated.

The ROI is segmented to calculate the cup and disc area, boundaries and also structural and textural features. To localize the boundary exactly morphological feature is applied.

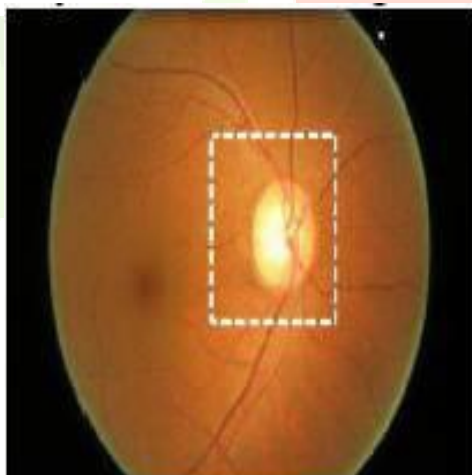


Figure 2: Retinal fundus image with the defined ROI by masking

K-Means Clustering

K-means is one of the simplest learning algorithms that solve the well-known clustering problem. The procedure follows a simple and easy way to classify a given data set through a certain number of clusters (assume k clusters) fixed a priori. The main idea is to define k centroids, one for each cluster. The next step is to take each point belonging to a given data set and associate it to the nearest centroid. When no point is pending, the first step is completed and an early group age is done. After we have these k new centroids, a new binding has to be done between the same data set points and the nearest new centroid. A loop has been generated [18].

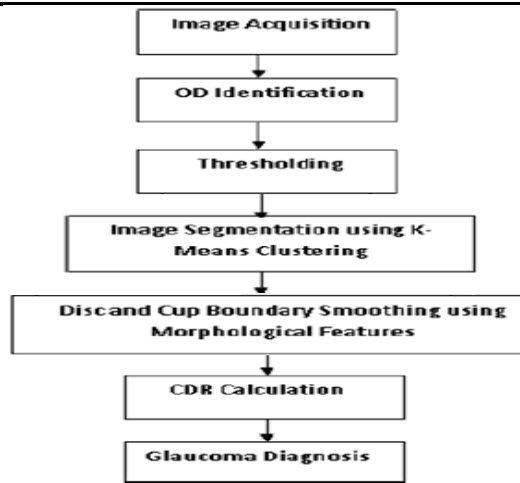


Figure 3: Workflow of Glaucoma diagnosis using CDR calculation

IV. USED METHODOLOGY

A. Optic Disc and Cup Segmentation

The K-means algorithm is an iterative technique that is used to partition the ROI image into K clusters. The ROI covers mainly the entire optic disc, optic cup and a small portion of other regions of the image. Hence the K value is chosen as 3. From the three clusters as shown in Figure 4 (a), the optic disc cluster has to be identified as follows. The cluster which contains the border region belongs to the other region of the ROI image that does not contain the optic disc and optic cup. Hence, the cluster is removed for the extraction of optic disc and the remaining two clusters form the optic disc region which is shown in Figure 4(b).

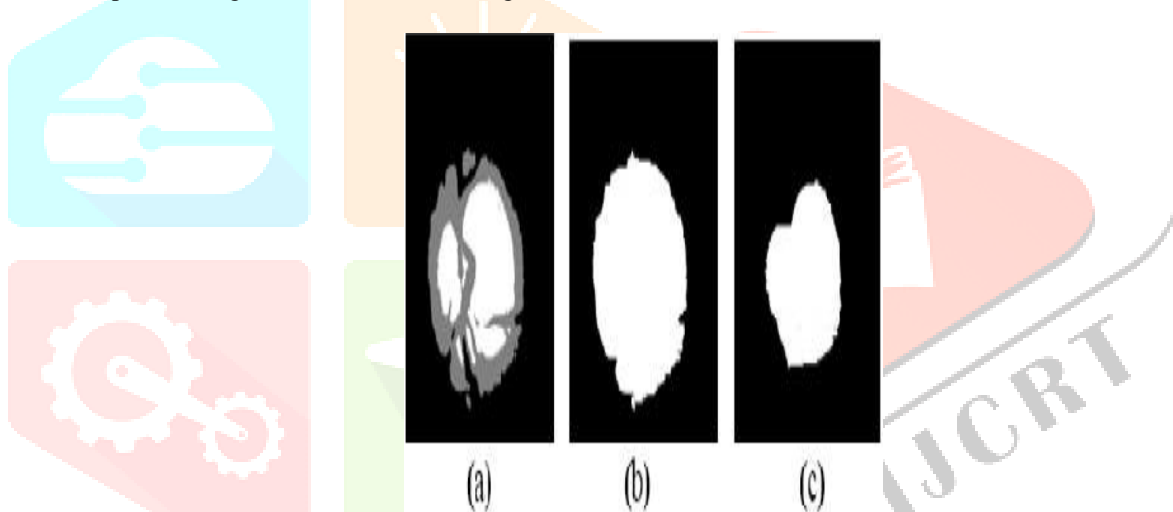


Figure 4: (a) K means clustering Image (b) Optic disc (c) Optic cup

Since it is clearly known that the optic cup is inside the optic disc, the cluster in the center of the image forms the optic cup which is shown in Figure 4(c). Finally, the morphological operation is performed to fill the holes and small region inside optic disc clusters and optic cup cluster.

After extracting optic disc, connected components technique is applied to form the rectangle that contains the whole disc region and cup region as shown in Figure 5 (a) and 5 (b) respectively. From the centre of the rectangle an ellipse is drawn that is inscribed in the rectangle.




Figure 5: (a) Rectangle for Optic disc region (b) Optic cup region

B. Optic Disc Smoothing

The disc boundary detected from the above step may not represent the actual shape of the disc since the boundary can be affected by a large number of blood vessels entering the disc. Therefore morphological features are applied to reshape the obtained disc boundary. Optic Cup smoothing after the cup boundary detection, morphological feature is again applied to eliminate some of the cup boundary's sudden changes in curvature [19].

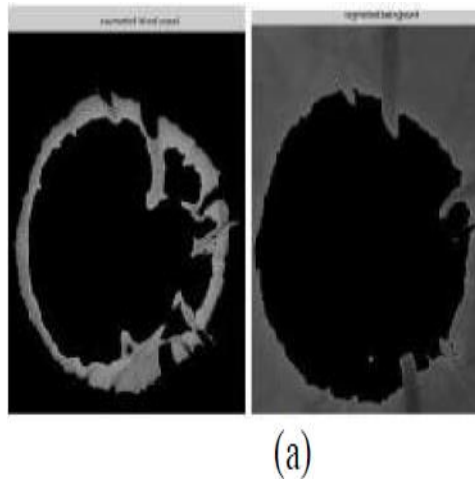


Figure 6 (a): segmented blood vessel & background using K-Means clustering

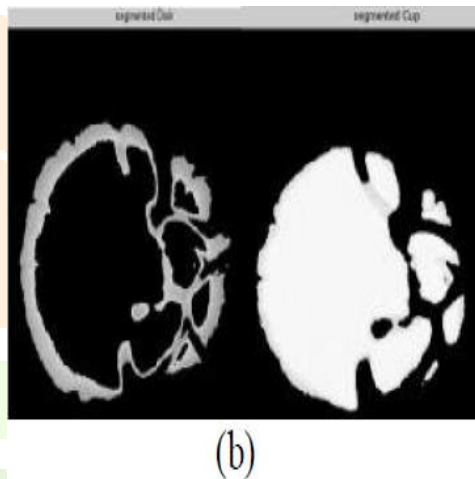


Figure 6 (b): Segmented disc & cup using K-Means clustering

C. Cup To Disc Ratio (CDR)

The cup-to-disc ratio (often notated CDR) is a measurement used in ophthalmology and optometry to assess the progression of glaucoma.

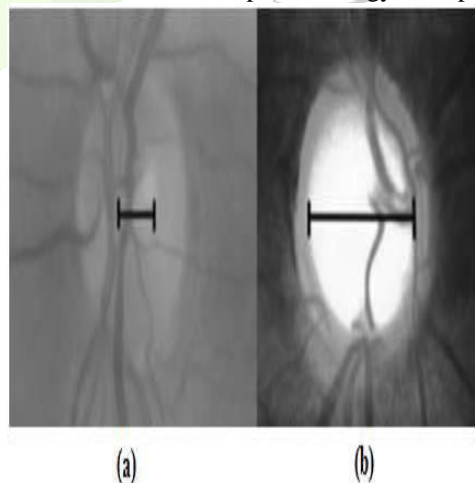


Figure 7: (a) Normal optic nerve head with small optic cup. b) Glaucomatous optic nerve head.

Currently, an important indicator of glaucoma is CDR, defined as the ratio of the vertical height of the optic cup to the vertical height of the optic disc [8]. Optic nerve cupping progresses as the cup becomes larger Fig 7(b) in comparison to the optic disc as shown in Fig 7(a). A cup to disc ratio value that is greater than 0.65 is generally considered to be suspicious for glaucoma.

CDR Calculation: To calculate the vertical cup to disc ratio (CDR), the optic cup and disc first have to be segmented from the retinal images. The evaluation of the performance of our approach is divided into 3 parts, which are the performance of the optic disc boundary detection, the performance of the optic cup boundary detection, and the vertical cup-to-disc ratio (CDR).

V. RESULTS AND DISCUSSION

A. Results Of CDR Detection

The normal cup to disc ratio is 0.3. A large cup ratio may imply glaucoma or other pathology. The cup-to-disc ratio compares the diameter of the "cup" portion of the optic disc with the total diameter of the optic disc. The cup-to-disc ratio of normal subjects is typically around 0.2 to 0.3.

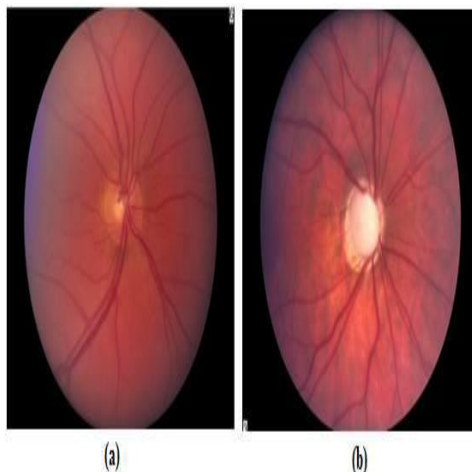

Figure 8: (a) Normal optic nerve - 0.3 C/D ratios (b) Glaucomatous optic nerve - 0.9 C/D ratios.

B. Glaucoma Screening Using GUI

Median Filter in images finds the median pixel value within the diameter that specified. It removes bright or dim features. Median filters are very effective in removing salt and pepper and impulse noise while retaining image details because they do not depend on values which are significantly different from typical values in the neighborhood.

Median filters work in successive image windows in a fashion similar to linear filter. It sorts all the pixels in an increasing order and takes the middle one. If the number of pixels is even, the median is taken as the average of the middle two pixels after sorting.

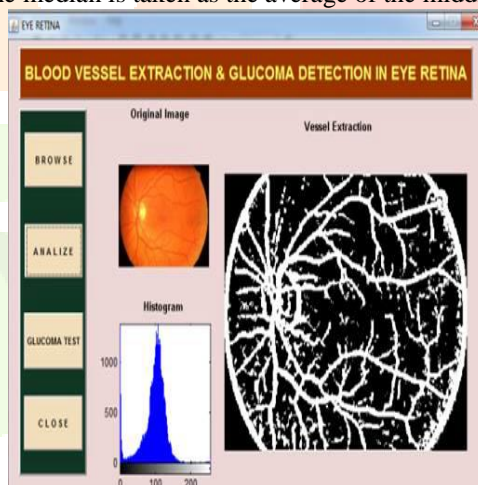


Figure 9 (a): Vessel Extraction

A) Blood Vessels Removal

Optic nerve fibers are mainly affected by glaucoma. Vessels are removed as their characteristics (such as diameter, location) are minimally affected by glaucoma. To suppress the behavior of vessels in the fundus image, in painting of the blood vessels is performed. A large number of vessel segmentation techniques are available in the literature. In this work, morphology based vessel segmentation is used as this method achieves higher accuracy.

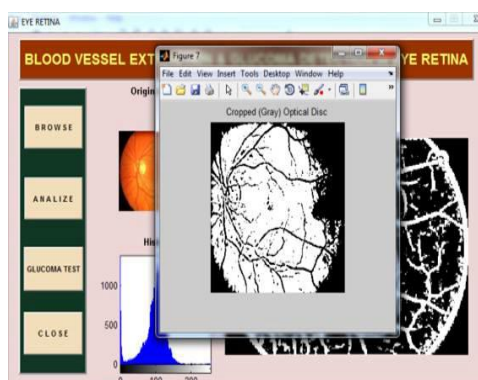


Figure 9 (b): Cropped Optical Disc

B) Segmentation of Optic Disc:

The optic disc is the entrance of the vessels and the optic nerve into the retina. The optic disc region is usually of a brighter pallor or higher color intensity than the surrounding retinal area. To calculate the vertical cup to disc ratio (CDR), the optic cup and disc first have to be segmented from the retinal images. Optic disc segmentation is the primary task in the analysis and classification of normal and abnormal images.

C) Edge Detection Method:

The green channel of the retinal image is extracted and filtered. After the pre-processing step that produces an image with uniform illumination, the next step is to remove the blood vessels and nerve fibers in the image, because these objects are not required in the segmentation process. The contrast of the blood vessels and the back ground is higher in the green channel. The morphological operation such as the closing is performed.

Conversely, if the cup-to-disc ratio is 0.3 or less, then this refers to a relatively healthy looking optic nerve. While there is no one cup-to-disc ratio that separates normal from glaucoma, the cup-to-disc ratio greater than 0.6 or 0.7 is suspicious of glaucoma and often requires further testing to rule out glaucoma.

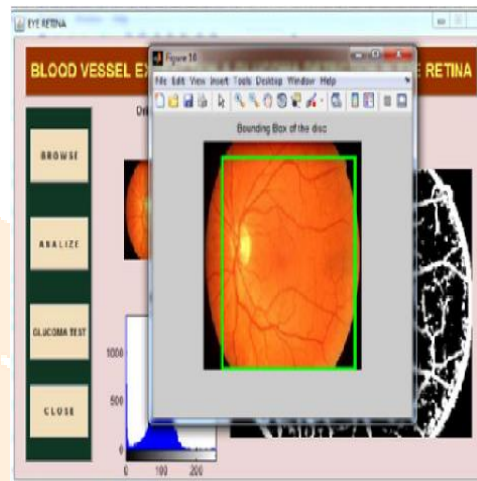


Figure 9 (c): Bounding Box of Disc RGB

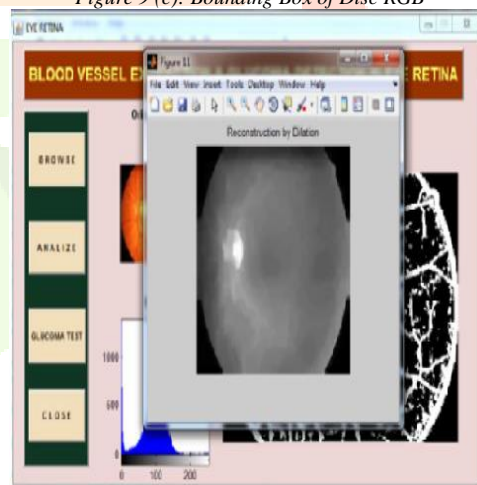


Figure 9 (d): Median Filtered Image

VI. CONCLUSION AND FUTURE WORK

In this paper, a combined glaucoma risk analysis is done based on the results of image and data based classification. This classification gives one of the five risk labels; no risk, low risk, moderate risk, high risk, and very high risk to each patient. Development of the user interface is the highlight of this work which enables any user to make use of the advantage of the technique.

REFERENCES

- [1] Joshi G D, Sivaswamy J & Krishnaas S.R, 'Optic disk and cup segmentation from monocular color retinal images for glaucoma assessment', IEEE Transactions on Medical Imaging, Vol. 30, No. 6, pp.1192–1205,2011.
- [2] Jun Cheng, Jiang Liu, Yanwu Xu, Fengshou Yin & Ngan-Meng Tan, 'Super pixel Classification Based Optic Disc and Optic Cup Segmentation for Glaucoma Screening', IEEE Transactions on Medical imaging, Vol. 32, NO. 6, pp.1019-1032, 2013.
- [3] Aquino A, Gegundez M & Marin D, 'Detecting the optic disc boundary in digital fundus images using morphological, edge detection, and feature extraction techniques', IEEE Transaction on Medical Imaging, Vol.29, No. 11,pp. 1860–1869, 2010.
- [4] Thomas Walter, Jean-Claude Klein, Pascale Massin, and Ali Erginay, 'A Contribution of image processing to the diagnosis of diabetic retinopathy detection of exudates in colour fundus images of the human retina', IEEE Transaction on medical imaging, vol.21, no.10, October 2002.

- [5] H. Li, O. Chutatape, 'Automated feature extraction in color retinal images by a model based approach', IEEE Trans. Biomed. Eng. 51 246–254, 2004.
- [6] M. Kass, A. Witkin, D. Terzopoulos, Snakes: 'active contour models', International Journal of Computer Vis. 1 321–331, 1988.
- [7] Gopal Datt Joshi, Jayanthi Sivaswamy, Kundan Karan, S. R. Krishnadas "Optic disc and cup boundary detection using regional information"- IEEE transactions on medical imaging, 2009.
- [8] J.J Staal et. al 'Digital Retinal Images for Vessel Extraction' Second International conference on Computing, Communication and Networking Technologies, vol.12, pp. 668–675, 2005.
- [9] P. Perona and J. Malik, "Scale space and edge detection using anisotropic diffusion" IEEE Trans. Pattern Anal. Machine Intell., vol.12, pp. 629–639, 1990
- [10] J. Serra, 'Introduction to mathematical morphology', Comput. Vis. Graph Image Process 35, 283–305, 1986.
- [11] N. Otsu, 'A threshold selection method from gray-level histogram', IEEE Trans. Syst. Man Cybern. 9, 62–66, 1979.
- [12] Anil K. Jain, "Fundamentals of Digital Image Processing" (Edition 7, unabridged, Prentice Hall, 1989).
- [13] S.Kavitha, S.Karhikeyan, Dr.K.Duraiswamy, 'Early Detection of Glaucoma in Retinal Images Using Cup to Disc Ratio', Second International conference on Computing, Communication and Networking Technologies 2010.
- [14] Jagadish Nayak. Rajendra Acharya U. P.Subbanna Bhat. Nakkul Shetty. Teik –Cheng Lim, "Automated Diagnosis of Glaucoma Using digital Fundus Images," J. Med Syst, DOI 10.1007/s10916-008- 9195-z, July 2008.
- [15] Chalinee Burana-Anusorn¹, Waree Kongprawechnon¹, Toshiaki Kondo¹, Sunisa Sintuwong² and KanokvateTungpimolrut, 'Image Processing Techniques for Glaucoma Detection Using the Cup-to-Disc Ratio' Thammasat International Journal of Science and Technology, Vol. 18, No. 1, January-March 2013.

